

**DATE PRESENTING CLINICAL SIGNS**

3/26/22

On Monday ingested 300mg of Gabapentin. RDVM did BW and LE, Lymphocytes and Monocytes were elevated. Had planned to have BW rechecked yesterday at RDVM but not able to find him. He has been hiding more than normal. Owner is not sure if he is eating or not.

**PATIENT**

Sammy Narrow

Current Medications: Prednisolone, Vitamin K, Doxycycline, Maropitant Citrate, Pantoprazole, Potassium Chloride.

**SPECIES**

Feline

Lab Results: Attached.

Date of Previous IntraPet Ultrasound: No previous.

Sedation: Not required to complete full diagnostic ultrasound.

Stat Report: Not requested.

**BREED**

DLH

**ULTRASONOGRAPHIC EXAMINATION OF THE ABDOMEN****SEX**

Neutered Male

**Urinary System**

The urinary bladder is well filled. The wall is smooth and regular. There is no evidence of cystoliths, polyps or a mass. A large amount of free floating sediment, most likely composed of mucus, crystals, and exfoliated cells is observed. It is most likely clinically insignificant. There are no obvious signs of cystitis.

**AGE**

3/25/20

The left kidney is within normal limits in size for the patient's weight (4.10 cm). The capsule is smooth. Its overall architecture, including the definition of the cortico-medullary junction, are preserved. There are no signs of nephroliths or pyelectasia. The surrounding mesentery is not hyperechoic.

**WEIGHT**

9.2 Pounds

The right kidney is within normal limits in size for the patient's weight (3.96 cm). The capsule is smooth. Its overall architecture, including the definition of the cortico-medullary junction, are preserved. There are no signs of nephroliths or pyelectasia. The surrounding mesentery is not hyperechoic.

**INTERPRETED BY**

Lisa Carioto, DVM,  
DVSc, Diplomate  
ACVIM

**Adrenal Glands**

The left adrenal gland was visualized in passing (not measured). No abnormalities are noted in the gland's shape, overall architecture, echogenicity or echotexture. The phrenico-abdominal vein and surrounding vasculature and mesentery are unremarkable.

**IMAGING PERFORMED BY**

Andi Parkinson RDMS

The right adrenal gland measures 0.42 cm at the cranial pole, 0.48 cm at the caudal pole, and 1.7 cm in length. No abnormalities are noted in the gland's shape, overall architecture, echogenicity or echotexture. The phrenico-abdominal vein and surrounding vasculature and mesentery are unremarkable.

**HOSPITAL NAME**

Animal Emergency  
Hospital

**Spleen**

The spleen is within normal limits in size, architecture, echotexture, and echogenicity. The capsule is smooth. No abnormalities are observed with its vasculature, i.e. congestion and thrombi are not identified.

**REFERRING VET**

Dr. Ruby

**Liver**

There are no obvious signs of hepatomegaly and its borders are smooth and sharp. The liver's echotexture is homogeneous and it is within normal limits in echogenicity. The hepatic veins are, subjectively, mildly dilated. Overt signs of an inflammatory, infiltrative or regenerative process are not evident.

**INVOICE**

36485

A portosystemic shunt is not visualized. However, one could be easily missed due to all of the gas and fluid in the surrounding gastrointestinal tract. The mesentery surrounding the liver is markedly hyperechoic.

The presence of a mildly hyperechoic and thickened gall bladder wall (1.3 mm), as well as the hyperechoic walls of the bile ducts are suggestive of cholecystitis. There are no signs of an obstruction. It is not possible to follow the cystic duct to the common bile duct due to the large amount of gas and fluid within the stomach.

### ***Gastrointestinal***

The stomach wall is thickened up to 0.78 cm in certain areas. Certain wall layers are severely thickened and hyperechoic, and a loss of definition of multiple layers is present. The stomach is enlarged and flaccid, with a lack of peristalsis (i.e., an ileus is present), and contains ingesta, fluid and gas. A “punched out” hypoechoic lesion of the mucosa is observed, which may be suggestive of an ulcer. Multiple hypoechoic foci are also visualized within the serosa. The mesentery surrounding the stomach is markedly hyperechoic.

The definition of the wall layers of the small intestines is preserved, however, the intestines in the region of the stomach are mildly thickened at 0.26 cm. Marked mucosal fogging and mild corrugation are also observed, in addition to severe hyperechogenicity of the surrounding mesentery. No abnormalities are observed in the transverse colon. An obvious foreign body is not visualized.

### ***Pancreas***

Within normal limits regarding echogenicity and echotexture. There is no evidence of hyperechogenicity of the mesenteric fat; active pancreatitis is considered unlikely.

### ***Other***

Lymph nodes: No abnormalities are observed.

Abdominal effusion is not visualized.

### ***Heart***

No obvious abnormalities are observed with contractility. Pleural effusion and pulmonary edema are absent. However, a trivial amount of pericardial effusion is observed.

## **ULTRASONOGRAPHIC FINDINGS**

- Severe inflammation and edema of the stomach is present. This is of unknown etiology. A non-specific gastritis must be considered. An ulcer of the mucosa, as well as hemorrhaging within the wall layers of the stomach cannot be excluded. Very severe inflammatory bowel disease with secondary inflammation due to an acute onset is possible. The hyperechoic mesentery surrounding some of the small intestines in the region of the stomach is attributed to the marked inflammatory response associated with a gastroenteropathy or gastritis. An obvious foreign body is not identified.
- The presence of distended hepatic veins and trivial amount of pericardial effusion may be due to volume overload or some form of vasculitis.
- The sediment in the urinary bladder is not considered clinically significant, however, a urinalysis is suggested to exclude hematuria based on the anemia.

## **INTERPRETATION OF THE FINDINGS & FURTHER RECOMMENDATIONS**

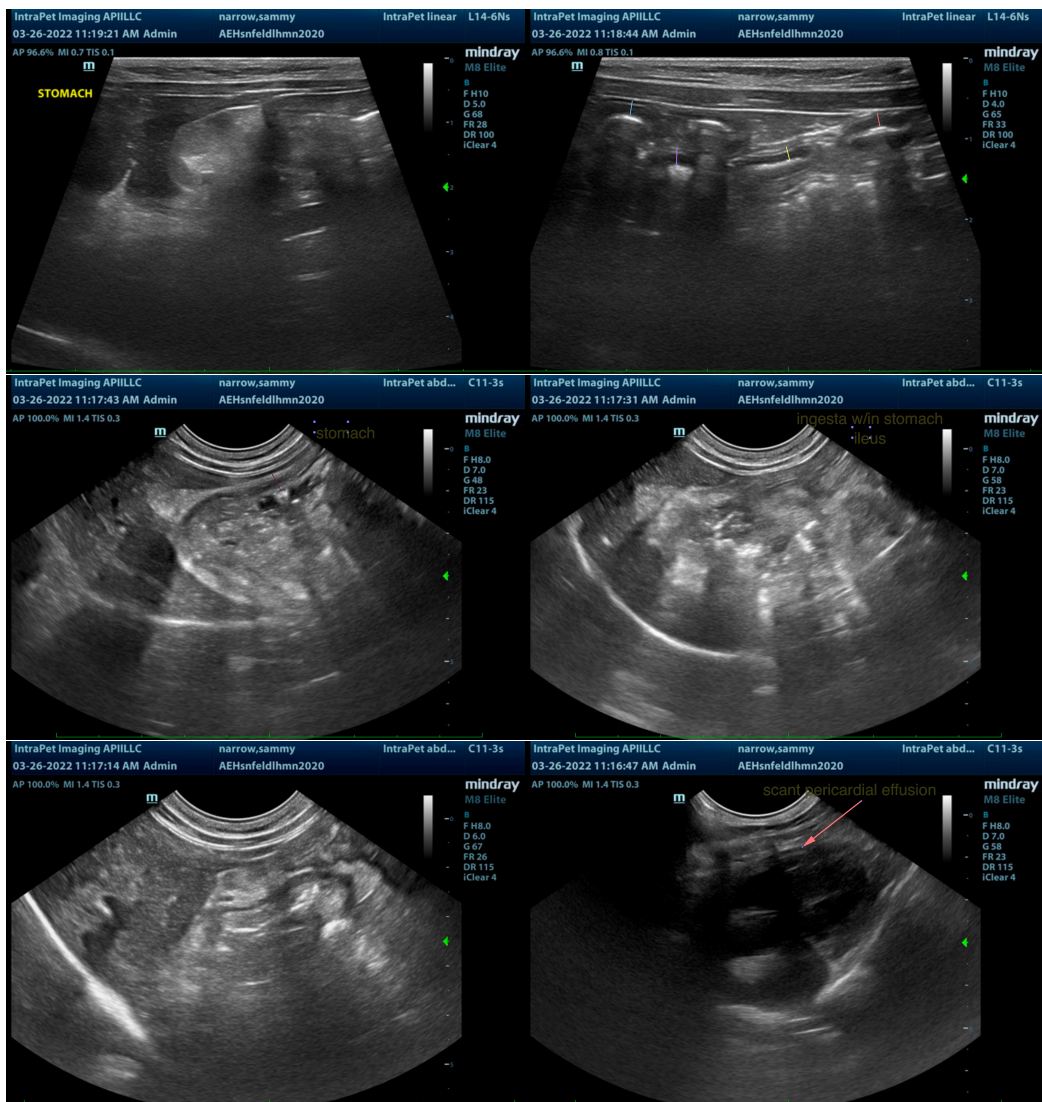
It may be worthwhile repeating the radiograph to determine whether or not the gas in the stomach has moved at all. Metoclopramide as a constant rate infusion may be considered to help improve peristalsis.

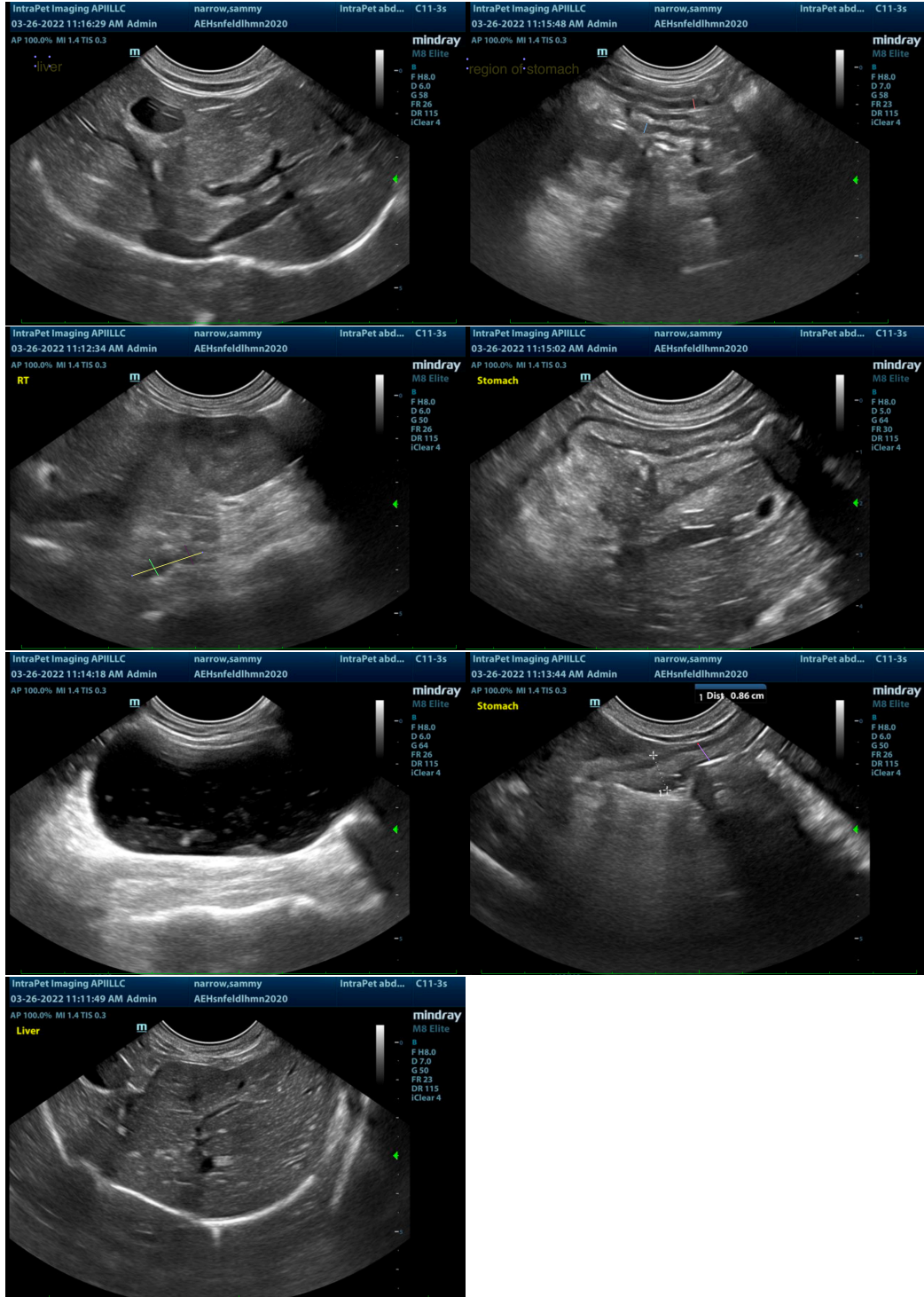
A blood smear of the CBC is recommended to rule out agglutination and spherocytes. These can be difficult to appreciate at times in cats, therefore, referral to a clinical pathologist may be warranted. A PCR test for *Mycoplasma* spp. is recommended, as immune mediated hemolytic anemia secondary to mycoplasmosis cannot be excluded.

The normal PT with an abnormal PTT is suggestive of factor XII deficiency, or what is known as Hageman factor deficiency. The latter causes a prolonged PTT without actual hemorrhage. If there is no history of

melenas or hematemesis, the vitamin K may be discontinued. However, to be sure, evaluation of factor XII is suggested. This can be performed at the Cornell University Diagnostic Laboratory. Hageman factor deficiency is not pathological. All other treatments, including prednisolone, doxycycline, maropitant, pantoprazole, and IV fluids should be continued. Dexamethasone administered intravenously may be administered instead of prednisolone to decrease gastrointestinal irritation.

Please refer to the emails sent to Intrapet on Saturday and Sunday for additional details regarding differential diagnoses and treatment options.





The information and recommendations provided are based on the images presented by the referring veterinarian/sonographer. No evaluation can be communicated regarding pathology that was not visible in the image/video clips provided.

Thank you for this referral. If the clinical or image interpretation does not parallel your findings or if I can be of any further assistance please contact me.

**Lisa Carioto, DVM, DVSc, Diplomate AVIM**

[Lisa.Carioto@sonopath.com](mailto:Lisa.Carioto@sonopath.com)