

**DATE**

3/21/22

PRESENTING CLINICAL SIGNS

Asymptomatic chronic ALT elevation.
Current Medications: Milk Thistle/Denamarin for several months.
Lab Results: Chronic ALT elevation- ALT 351 on 3/7/22.
Date of Previous IntraPet Ultrasound: No previous.
Sedation: Not required to complete full diagnostic ultrasound.
Stat Report: Not requested.
Imaging Performed By: Rachel Brillhart, RDMS.

PATIENT

Dino Binko

SPECIES

Canine

BREED

Chihuahua Mix

SEX

Neutered male

AGE

1/11/14

WEIGHT

10.4 lbs

INTERPRETED BY

Lisa Carioto, DVM,
DVSc, Diplomate
ACVIM

HOSPITAL NAME

Essex Middle River VC

REFERRING VET

Dr. Zulty

INVOICE

97006

ULTRASONOGRAPHIC EXAMINATION OF THE ABDOMEN**Urinary System**

The urinary bladder is adequately filled. The wall is smooth and regular. No abnormalities are present with the trigone or proximal urethra, and there is no evidence of sediment, cystoliths, polyps or a mass.

The prostate is homogenous and measures 0.83 mm, which is within normal limits for a neutered male.

The left kidney is within normal limits in size (3.85 cm) for the patient's weight and the capsule is smooth. However, the cortex is mildly hyperechoic and a mild loss of the normal definition of the cortico-medullary junction is present. A very small nephrolith/mineralization (1.2 mm), which casts a shadow is noted. The surrounding mesentery is not hyperechoic.

The right kidney is within normal limits in size (4.08 cm) for the patient's weight and the capsule is smooth. However, the cortex is mildly hyperechoic and a mild loss of the normal definition of the cortico-medullary junction is present. A nephrolith is noted and measures 1.5 mm. The surrounding mesentery is not hyperechoic.

Both kidneys have excellent blood flow.

Adrenal Glands

The left adrenal gland measures 0.49 cm at the cranial pole and 0.51 cm at the caudal pole and 1.82 cm in length. The caudal pole is rounded. No abnormalities are noted with the overall architecture, echogenicity or echotexture. There is very nice corticomedullary definition. The phrenico-abdominal vein and surrounding vasculature and mesentery are unremarkable.

The right adrenal gland measures 0.52 cm at the cranial pole, 0.48 cm at the caudal pole and 1.56 cm in length. The right adrenal gland is "plump" (somewhat "pudgy"). No abnormalities are noted with the gland's shape, overall architecture, echogenicity or echotexture. There is very nice corticomedullary definition. The phrenico-abdominal vein and surrounding vasculature and mesentery are unremarkable.

Spleen

The spleen is within normal limits in size, architecture, echotexture, and echogenicity. The capsule is smooth. No abnormalities are observed with its vasculature, i.e. congestion and thrombi are not identified.

Liver

There are no obvious signs of hepatomegaly and its borders are smooth and sharp. The liver's echotexture is very mildly heterogenous with a granular echotexture. No abnormalities are observed with the hepatic vessels.

A mild amount of echogenic material is visualized within the gallbladder, which is most likely considered clinically insignificant (see below). The biliary system is otherwise within normal limits.

Gastrointestinal

The gastric wall layers are more prominent than usual, particularly the mucosa and muscularis, which appear thicker than normal. The overall thickness is mildly thicker than usual (0.54 cm). The muscularis has mild fogging as well. Despite these abnormalities, definition of the wall layers is preserved. These changes are suggestive of inflammation. A small amount of fluid is present within the lumen.

The small intestinal wall thickness is within normal limits and there is no evidence of dilation. The definition of the wall layers is preserved. The ileo-cecal-colic junction and the surrounding mesentery are unremarkable. The colonic wall is not thickened and mural detail is preserved. There are no obvious signs of a mass, foreign body, or an obstruction.

Pancreas

Both the left and right limbs of the pancreas have a coarse echotexture and are mildly heterogeneous. These changes are most likely due to nodular hyperplasia and areas of fibrosis. The changes are considered age related and possibly secondary to previous episodes of pancreatitis, respectively. There are no signs of active pancreatitis.

Other

Lymph nodes: No abnormalities are observed.

Abdominal effusion is not visualized.

ULTRASONOGRAPHIC FINDINGS

Very mild degenerative changes of both kidneys, which are suggestive of age related degeneration.

Both limbs of the pancreas show signs suggestive of fibrosis, most likely due to age related degeneration, as well as possible scar tissue associated with previous episodes of pancreatitis and nodular regeneration. There are no signs of active pancreatitis or neoplasia.

The adrenal glands are within the normal reference range. However, the right adrenal is "mildly pudgy or plump" while the caudal pole of the left adrenal is mildly rounded. These are not considered clinically significant at this time. However, reevaluation of the adrenal glands is suggested in 6-12 months depending on Dino's clinical signs.

No major abnormalities are observed with the liver. Its coarse, mildly granular echotexture may be due to a reactive hepatopathy, which may be due to underlying inflammatory bowel disease of the stomach, which can also increase ALT enzyme activity. Discontinuation of Denamarin may be pursued in conjunction with starting a hypoallergenic or hydrolyzed diet and repeating liver enzyme activities, including a GGT, 4-6 weeks later.

The gallbladder sludge is most likely clinically insignificant; however, it is still worthwhile asking the client if Dino is experiencing signs of gastroesophageal reflux as treatment with ursodeoxycholic acid may be warranted in the future, as well as famotidine or omeprazole BID.

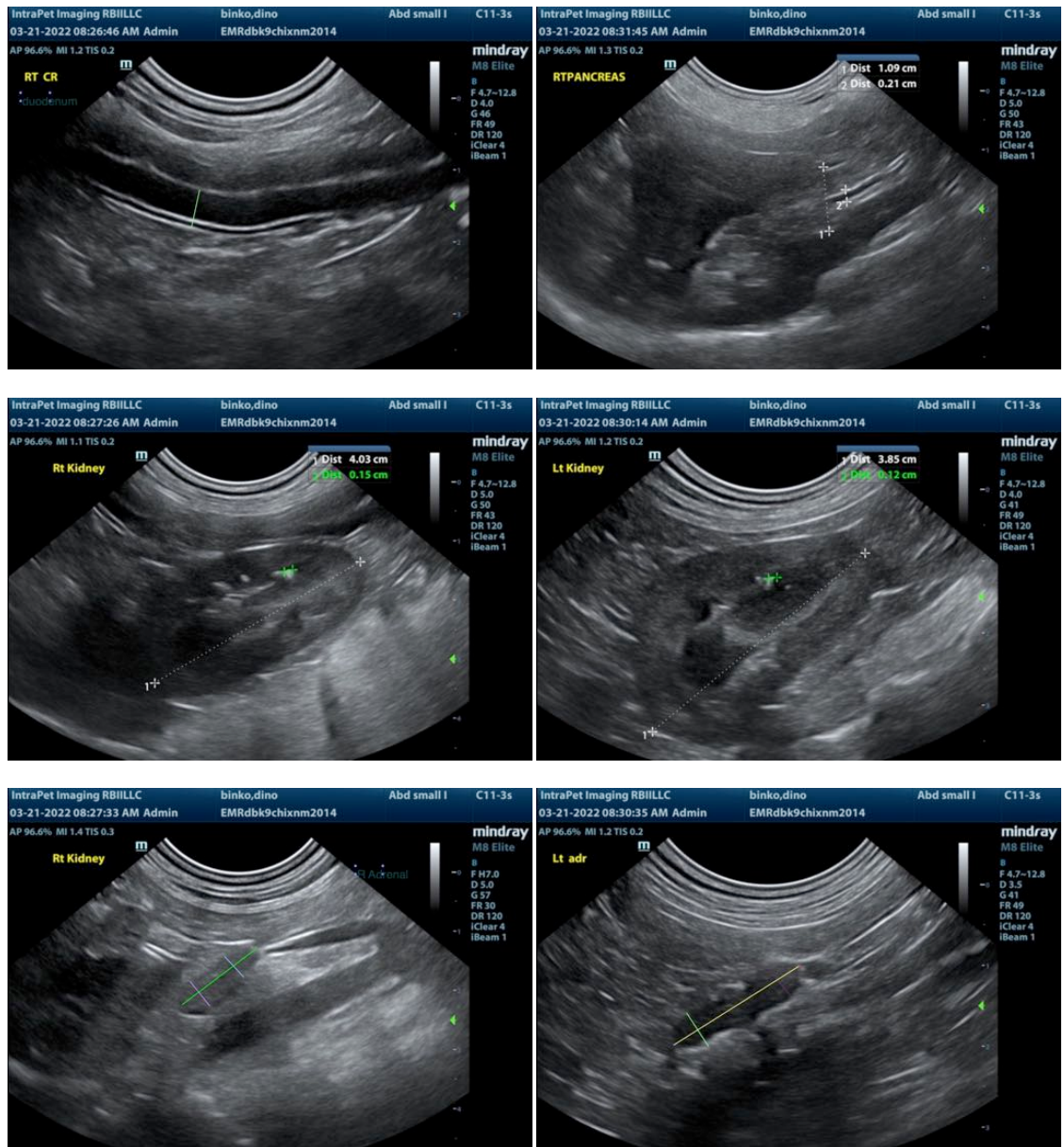
INTERPRETATION OF THE FINDINGS & FURTHER RECOMMENDATIONS

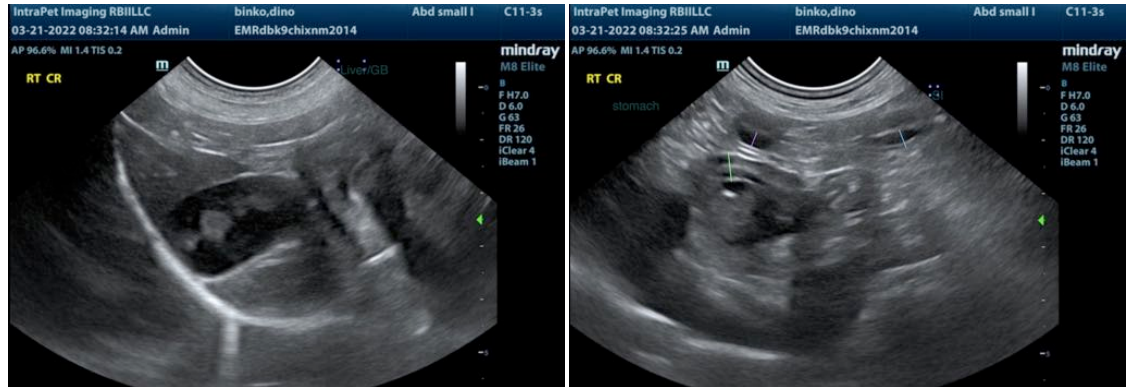
A hypoallergenic or hydrolyzed diet is recommended.

The Denamarin may be discontinued.

Reevaluation of the adrenal glands is suggested in 6 months to a year depending on Dino's clinical signs.

Obtaining additional history regarding signs of gastroesophageal reflux is recommended. If there is no improvement in the ALT, if it continues to increase or if the GGT is elevated, one could perform a FNA of the liver or consider a biopsy to determine the abnormal liver enzyme(s).





The information and recommendations provided are based on the images presented by the referring veterinarian. No evaluation can be communicated regarding pathology that was not visible in the image/video clips provided.

Thank you for this referral. If the clinical or image interpretation does not parallel your findings or if I can be of any further assistance please contact me.

Lisa Carioto, DVM, DVSc, Diplomate ACVIM
Lisa.Carioto@sonopath.com