



PATIENT

Bill Maes

SPECIES

Feline

BREED

Domestic Shorthair

SEX

Neutered male

AGE

4 / 12 years

WEIGHT

5.1 kg

INTERPRETED BY

Kathleen Sennello
DVM, MS, Diplomate
ACVIM (Small Animal
Internal Medicine)

**IMAGING
PERFORMED BY**

Kelly Reshny, RVT

HOSPITAL NAME

Big Creek VH

REFERRING VET

Dr. Wilkinson

INVOICE

98078

DATE

4/6/22

PRESENTING CLINICAL SIGNS

History: inappetence - normal hydration - radiographs with barium - sent to London Emerge (they did not think it was a blockage) - sent home Sunday - still not eating Monday/Tuesday. Currently on Mirtazapine.

Abnormal PE/Chem/CBC/UA Results: Bloodwork normal. Please find radiographs attached.

ULTRASONOGRAPHIC EXAMINATION OF THE ABDOMEN

Urinary System

The urinary bladder is moderately distended with anechoic urine. The Bladder wall, trigone, ureteral papillae and visible urethra (to a depth of 2cm) appear normal with no evidence of wall thickening, mucosal irregularities, masses or cystic calculi.

The left kidney has a normal shape and size (3.81 cm). Overall echogenicity is normal with adequate corticomedullary distinction and a typical 1:3 cortex:medulla ratio. There is no evidence of perinephric inflammation or effusion. There is no evidence of pyelectasia, nephroliths, infarcts or hydroureter. Renal vasculature is normal.

The right kidney has a normal shape and size (3.65 cm). Overall echogenicity is normal with adequate corticomedullary distinction and a typical 1:3 cortex:medulla ratio. There is no evidence of perinephric inflammation or effusion. There is no evidence of pyelectasia, nephroliths, infarcts or hydroureter. Renal vasculature is normal.

Adrenal Glands

The left adrenal gland is normal in size measuring 0.33 cm at the caudal pole. It is observed in its normal position cranial to the left renal artery. It is normal in appearance (uniformly hypoechoic) and shape with no evidence of a mass effect.

The right adrenal gland is normal in size measuring 0.41 cm at the caudal pole. It is observed in its normal position between the cranial aspect of the right kidney and the caudal vena cava. It is normal in appearance (uniformly hypoechoic) and shape with no evidence of a mass effect.

Spleen

The spleen is subjectively normal in size, echotexture is homogenous, and the splenic capsule is smooth with no irregularities. The blood flow through the hilus and splenic parenchyma appears normal. No focal parenchymal abnormalities are visualized.

Liver

The liver is subjectively normal in size, and echogenicity with smooth peripheral margins. The parenchyma is homogenous echotexture. The visible portions of the vasculature and biliary tract appear normal. No focal nodules or cystic lesions are observed. The gallbladder lumen is moderately distended. The wall of the gallbladder is not thickened and has a smooth mucosal surface. Luminal contents are primarily anechoic. The cystic and common bile ducts are normal/not visible.



PATIENT *Gastrointestinal*

Bill Maes The stomach contains minimal luminal contents. It measures at a normal thickness of <0.36cm with some variability due to the presence of rugal folds. The distinction of the gastric wall layers is adequate and there is no impression of reduced peristaltic activity. No masses or focal lesions were observed.

SPECIES

Feline

The visualized areas of duodenum, jejunum and ileum have a relatively uniform diameter with minimal fluid distension. Wall thickness is normal. Bowel loops follow a curvilinear path with distinct wall layering maintaining the typical 1:3 muscularis:mucosa layer ratio. The duodenum measured as normal and the jejunum measured as normal (0.21 cm). Visualized peristalsis appears appropriate. There were no focal lesions consistent with obstruction or a mass effect observed.

BREED

Domestic Shorthair

SEX

Neutered male

The ileocecal junction was visualized and exhibited normal intact wall layering and is subjectively of normal thickness. Sections of colon are visualized with formed fecal material and gas shadowing distally. There is no observed focal or generalized colon wall thickening or loss of layering.

AGE

4 /12 years

Pancreas

The pancreas is normal and isoechoic to surrounding mesentery. There is no evidence of nodules or cystic lesions. There is no evidence of regional mesenteric inflammation or fluid.

WEIGHT

5.1 kg

Free Abdomen

Evaluation of the peritoneal cavity did not reveal any evidence of effusion, or subjective lymphadenomegaly. The Medial iliac nodes appear normal and there was no evidence of a caudal aortic thrombus at the bifurcation. The omentum is of normal uniform echogenicity.

INTERPRETED BY

Kathleen Sennello
DVM, MS, Diplomate
ACVIM (Small Animal
Internal Medicine)

ULTRASONOGRAPHIC FINDINGS

IMAGING PERFORMED BY

Kelly Reshny, RVT

PRIMARY FINDINGS:

- No significant lesions visualized on today's exam.

HOSPITAL NAME

Big Creek VH

INTERPRETATION OF THE FINDINGS & FURTHER RECOMMENDATIONS

No focal lesions were visualized to explain the inappetence and lethargy reported. If primary GI disease is suspected you can consider a GI panel to Texas A&M for a qualitative fPLI, TLI, cobalamin, and folate to further evaluate the pancreas and small intestine. In some cases pancreatic disease does not always correlate with ultrasonographic findings and there are some types of foreign material that cannot always be detected with ultrasound. Consider some nutritional intervention (small volume oral syringing, nasogastric tube, esophagostomy tube, etc.) to support nutritional needs and close monitoring with additional evaluation as indicated based on clinical signs.

REFERRING VET

Dr. Wilkinson

INVOICE

98078

DATE

4/6/22



PATIENT

Bill Maes

SPECIES

Feline

BREED

Domestic Shorthair

SEX

Neutered male

AGE

4 /12 years

WEIGHT

5.1 kg

INTERPRETED BY

Kathleen Sennello
DVM, MS, Diplomate
ACVIM (Small Animal
Internal Medicine)

**IMAGING
PERFORMED BY**

Kelly Reshny, RVT

HOSPITAL NAME

Big Creek VH

REFERRING VET

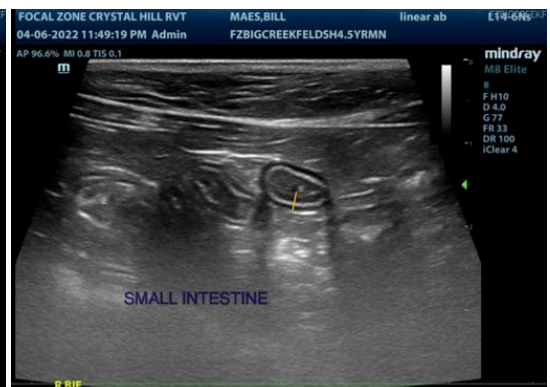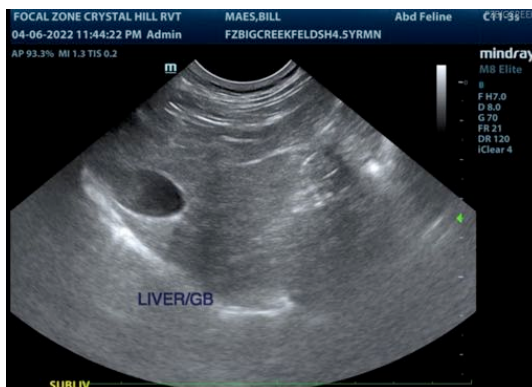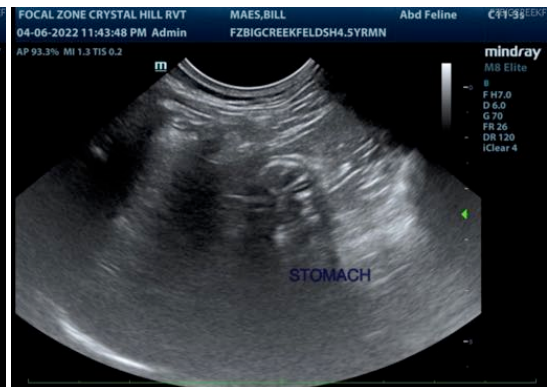
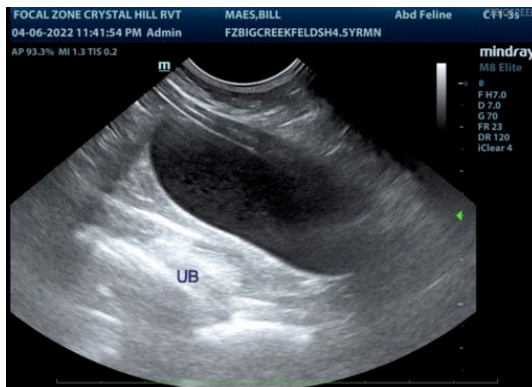
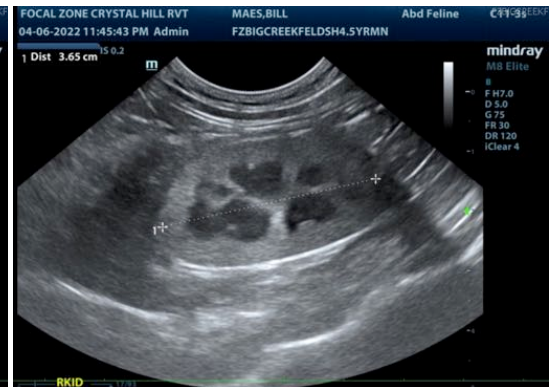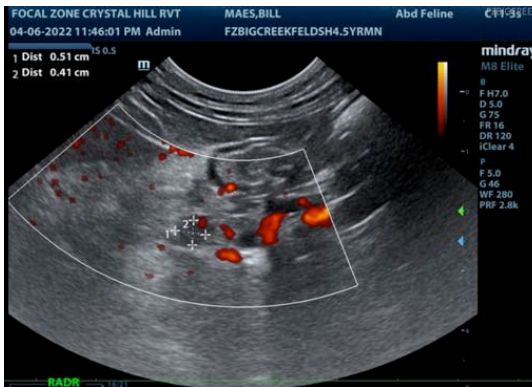
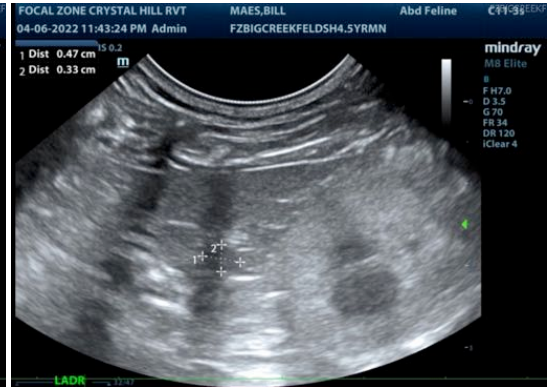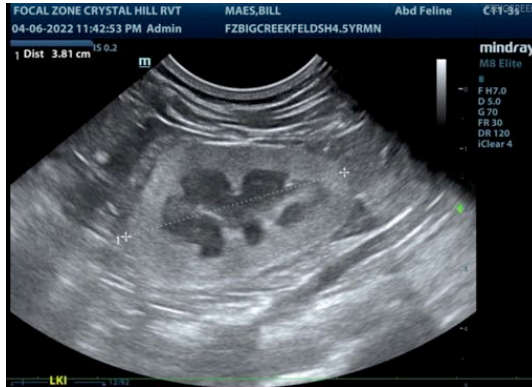Dr. Wilkinson

INVOICE

98078

DATE

4/6/22





PATIENT

Bill Maes

SPECIES

Feline

BREED

Domestic Shorthair

SEX

Neutered male

AGE

4 /12 years

WEIGHT

5.1 kg

INTERPRETED BY

Kathleen Sennello
DVM, MS, Diplomate
ACVIM (Small Animal
Internal Medicine)

**IMAGING
PERFORMED BY**

Kelly Reshny, RVT

HOSPITAL NAME

Big Creek VH

REFERRING VET

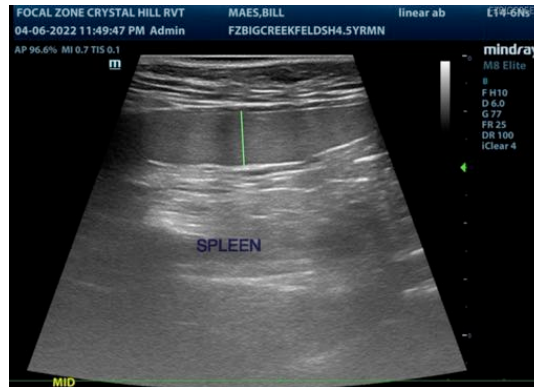Dr. Wilkinson

INVOICE

98078

DATE

4/6/22



The information and recommendations provided are based on the images presented by the referring veterinarian/sonographer. No evaluation can be communicated regarding pathology that was not visible in the image/video clips provided.

Thank you for this referral. If the clinical or image interpretation does not parallel your findings or if I can be of any further assistance please contact me.

Kathleen Sennello DVM,MS, Diplomate ACVIM (Small animal Internal Medicine)

kathleen.sennello@sonopath.com