



**PATIENT PRESENTING CLINICAL SIGNS**

**PATIENT**  
Evie Broberg

**SPECIES**  
Canine

**BREED**  
Coton de Tulear

**SEX**  
Spayed Female

**AGE**  
8 years

**WEIGHT**  
6.7 kg

Patient is doing well clinically presented with elevated renal parameters in Dec 2021 - bloodwork taken for routine dental cleaning Today noted SDMA had increased as well as ongoing elevation in BUN/CREA 4dx in spring was negative some hip/joint issues noted

Abnormal PE/Chem/CBC/UA Results: Dec 9 - SDMA 16, BUN and CREA at high end of normal, high RBC parameters Dec 14 2021 UA: SG 1.045, sediment quiet, a lot of debris present in sample Jan 4 2022 - SG 1.049, 1+ urine protein, 3+ CAO crystals, no infection noted, SDMA 14 Jan 18 - SDMA now 26, BUN and CREA at high end of normal, urine culture taken today and pending, radiographs did not reveal a stone despite high CaO content of prior urine sample Dental surgery postponed please see attached rads and labs

**ULTRASONOGRAPHIC EXAMINATION OF THE ABDOMEN**

**Urinary System**

The urinary bladder is moderately distended with anechoic urine. The Bladder wall, trigone, ureteral papillae and visible urethra (to a depth of 2cm) appear normal with no evidence of wall thickening, mucosal irregularities, masses or cystic calculi.

The left kidney has a normal shape and size (3.34 cm). Overall echogenicity is slightly hyperechoic with poor corticomedullary distinction and a typical 1:3 cortex:medulla ratio. There is no evidence of perinephric inflammation or effusion. Small, pinpoint, non-obstructive nephroliths were noted. There is no evidence of pyelectasia, infarcts or hydroureter. Renal vasculature is normal.

The right kidney has a normal shape and size (3.5 cm). Overall echogenicity is slightly hyperechoic with poor corticomedullary distinction and a typical 1:3 cortex:medulla ratio. There is no evidence of perinephric inflammation or effusion. Small, pinpoint, non-obstructive nephroliths were noted. There is no evidence of pyelectasia, infarcts or hydroureter. Renal vasculature is normal.

**Adrenal Glands**

The left adrenal gland is normal in size measuring 0.43 cm at the caudal pole It is observed in its normal position cranial to the left renal artery. It is normal in appearance (uniformly hypoechoic) and shape with no evidence of a mass effect.

The right adrenal gland is normal in size measuring 0.45 cm at the caudal pole It is observed in its normal position between the cranial aspect of the right kidney and the caudal vena cava. It is normal in appearance (uniformly hypoechoic) and shape with no evidence of a mass effect.

**Spleen**

The spleen is subjectively normal in size, echotexture is homogenous, and the splenic capsule is smooth with no irregularities. The blood flow through the hilus and splenic parenchyma appears normal. No focal parenchymal abnormalities are visualized.

**Liver**

The liver is subjectively normal in size, and echogenicity with smooth peripheral margins. The parenchyma is homogenous echotexture. The visible portions of the vasculature and biliary tract appear

**INTERPRETED BY**

Kathleen Sennello  
DVM, MS, Diplomate  
ACVIM (Small Animal  
Internal Medicine)

**IMAGING PERFORMED BY**

Kelly Reshny, RVT

**HOSPITAL NAME**

Oxford County VC

**REFERRING VET**

Dr. Halfon

**INVOICE**

95392

**DATE**

1/19/22



**PATIENT**

Evie Broberg

normal. No focal nodules or cystic lesions are observed. The gallbladder lumen is moderately distended. The wall of the gallbladder is not thickened and has a smooth mucosal surface. Luminal contents are primarily anechoic. The cystic and common bile ducts are normal/not visible.

**SPECIES**

Canine

**Gastrointestinal**

The stomach contains minimal luminal contents. It measures at a normal thickness of <0.7cm with some variability due to the presence of rugal folds. The distinction of the gastric wall layers is adequate and there is no impression of reduced peristaltic activity. No masses or focal lesions were observed.

**BREED**

Coton de Tulear

The visualized areas of duodenum, jejunum and ileum have a relatively uniform diameter with minimal fluid distension. Wall thickness is normal. Bowel loops follow a curvilinear path with distinct wall layering maintaining the typical 1:3 muscularis:mucosa layer ratio. The duodenum measured as normal (between 0.3-0.5cm in wall thickness) and the jejunum measured as normal (between 0.2-0.47cm.) Visualized peristalsis appears appropriate. There were no focal lesions consistent with obstruction or a mass effect observed.

**SEX**

Spayed Female

**AGE**

8 years

The ileocecal junction was visualized and exhibited normal intact wall layering and is subjectively of normal thickness. Sections of colon are visualized with formed fecal material and gas shadowing distally. There is no observed focal or generalized colon wall thickening or loss of layering.

**WEIGHT**

6.7 kg

**Pancreas**

The pancreas is normal and isoechoic to surrounding mesentery. There is no evidence of nodules or cystic lesions. There is no evidence of regional mesenteric inflammation or fluid.

**INTERPRETED BY**

Kathleen Sennello  
DVM, MS, Diplomate  
ACVIM (Small Animal  
Internal Medicine)

**Free Abdomen**

Evaluation of the peritoneal cavity did not reveal any evidence of effusion, or subjective lymphadenomegaly. The Medial iliac nodes appear normal and there was no evidence of a caudal aortic thrombus at the bifurcation. The omentum is of normal uniform echogenicity.

**IMAGING PERFORMED BY**

Kelly Reshny, RVT

**ULTRASONOGRAPHIC FINDINGS**

**HOSPITAL NAME**

Oxford County VC

**PRIMARY FINDINGS:**

- Decreased corticomedullary distinction in both kidneys with occasional, pinpoint, non-obstructive nephroliths. Mild loss of corticomedullary distinction in both kidneys could be consistent with chronic degenerative disease or interstitial nephrosis.

**REFERRING VET**

Dr. Halfon

**INTERPRETATION OF THE FINDINGS & FURTHER RECOMMENDATIONS**

**INVOICE**

95392

The ultrasonographic lesions on today's scan were relatively mild. There are subtle changes involving the kidneys that are most consistent with chronic, progressive type of changes. No focal lesions such as stones or pelvic dilation, etc. are visualized to explain the borderline azotemia reported.

**DATE**

1/19/22

- Consider blood pressure evaluation.
- Consider testing for Leptospirosis.
- Consider screening for Addison's disease.
- Recommend urinalysis and culture (currently pending per history).



**PATIENT**

Evie Broberg

**SPECIES**

Canine

**BREED**

Coton de Tulear

**SEX**

Spayed Female

**AGE**

8 years

**WEIGHT**

6.7 kg

**INTERPRETED BY**

Kathleen Sennello  
DVM, MS, Diplomate  
ACVIM (Small Animal  
Internal Medicine)

**IMAGING  
PERFORMED BY**

Kelly Reshny, RVT

**HOSPITAL NAME**

Oxford County VC

**REFERRING VET**

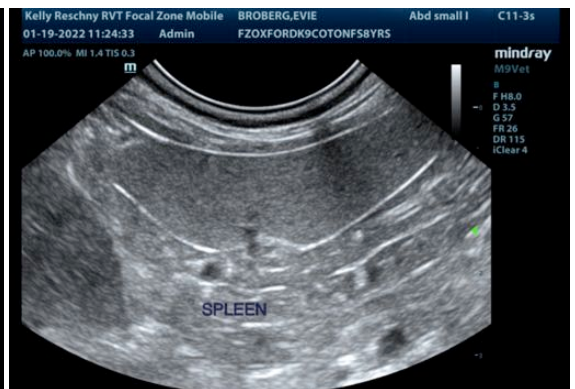
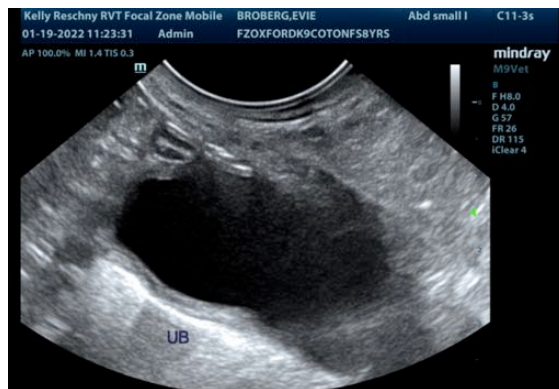
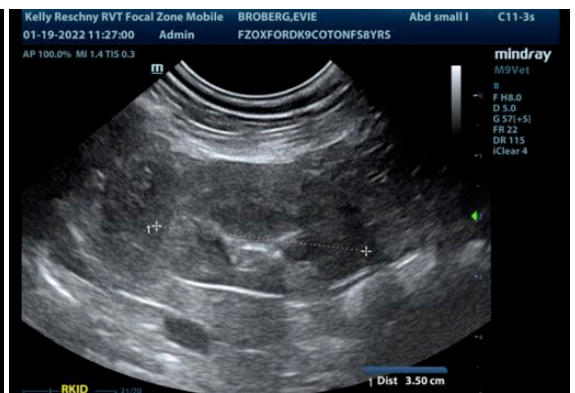
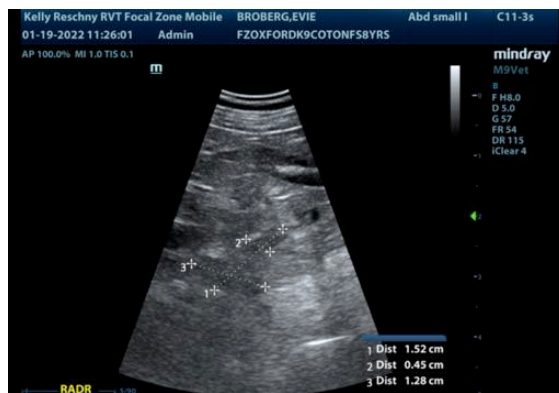
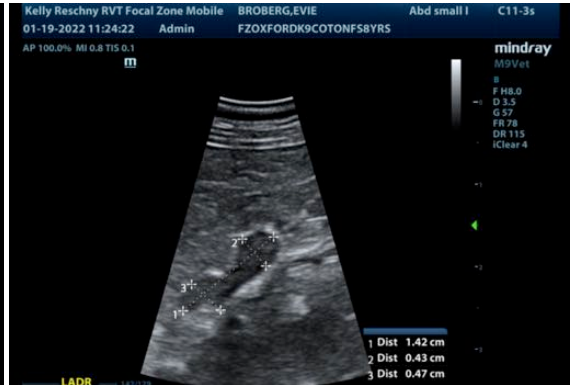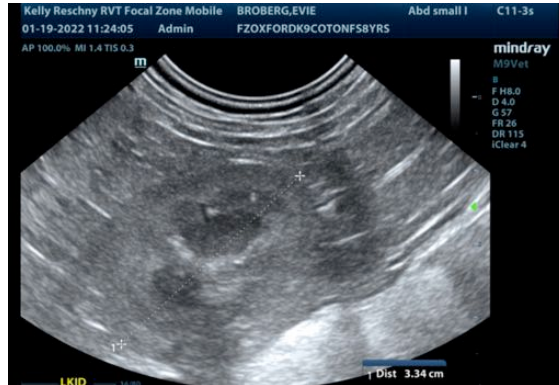
Dr. Halfon

**INVOICE**

95392

**DATE**

1/19/22





**PATIENT**

Evie Broberg

**SPECIES**

Canine

**BREED**

Coton de Tulear

**SEX**

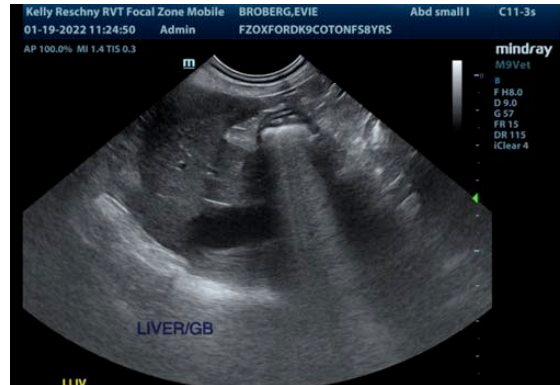Spayed Female

**AGE**

8 years

**WEIGHT**

6.7 kg



The information and recommendations provided are based on the images presented by the referring veterinarian. No evaluation can be communicated regarding pathology that was not visible in the image/video clips provided.

Thank you for this referral. If the clinical or image interpretation does not parallel your findings or if I can be of any further assistance please contact me.

Kathleen Sennello DVM,MS, Diplomate ACVIM (Small animal Internal Medicine)

kathleen.sennello@sonopath.com

**INTERPRETED BY**

Kathleen Sennello  
DVM, MS, Diplomate  
ACVIM (Small Animal  
Internal Medicine)

**IMAGING  
PERFORMED BY**

Kelly Reshny, RVT

**HOSPITAL NAME**

Oxford County VC

**REFERRING VET**

Dr. Halfon

**INVOICE**

95392

**DATE**

1/19/22