**DATE**

9/8/22

**PRESENTING CLINICAL SIGNS**

Episode of vomiting and diarrhea in May 2022. Seen at ER- no significant findings. Had had on/off diarrhea since then. No response to Hill's I/D.

Current Medications: Cerenia as needed.

**PATIENT**

Fluff Kitty Dickens

Lab Results: Fecal negative. Hematology/Chemistry attached.

Date of Previous IntraPet Ultrasound: No previous.

Sedation: Patient was sedated with Dexdomitor.

Stat Report: Not requested.

Imaging Performed By: Andi Parkinson, BS, RDMS.

**SPECIES**

Feline

**ULTRASONOGRAPHIC EXAMINATION OF THE ABDOMEN****BREED**

Maine Coon Mix

**Urinary System**

The urinary bladder is moderately distended with anechoic urine. The Bladder wall, trigone, ureteral papillae and visible urethra (to a depth of 2cm) appear normal with no evidence of wall thickening, mucosal irregularities, masses or cystic calculi.

**SEX**

Neuterd male

The left kidney has a normal shape and size (4.38 cm). Overall echogenicity is normal with adequate corticomedullary distinction and a typical 1:3 cortex:medulla ratio. There is no evidence of perinephric inflammation or effusion. There is no evidence of pyelectasia, nephroliths, infarcts or hydroureter. Renal vasculature is normal.

**AGE**

3/29/14

The right kidney has a normal shape and size (4.43 cm). Overall echogenicity is normal with adequate corticomedullary distinction and a typical 1:3 cortex:medulla ratio. There is no evidence of perinephric inflammation or effusion. There is no evidence of pyelectasia, nephroliths, infarcts or hydroureter. Renal vasculature is normal.

**WEIGHT**

15.8 lbs

**INTERPRETED BY**

Kathleen Sennello  
DVM, MS, Diplomate  
ACVIM (Small Animal  
Internal Medicine)

**Adrenal Glands**

The left adrenal gland is normal in size measuring 0.42 cm at the caudal pole It is observed in its normal position cranial to the left renal artery. It is normal in appearance (uniformly hypoechoic) and shape with no evidence of a mass effect.

The region of the right adrenal gland was unremarkable.

**HOSPITAL NAME**

Harborside Mobile

**Spleen**

The spleen is subjectively normal in size, echotexture is homogenous, and the splenic capsule is smooth with no irregularities. The blood flow through the hilus and splenic parenchyma appears normal. No focal parenchymal abnormalities are visualized. The spleen measured 1.0 cm in width at the level of the hilus.

**REFERRING VET**

Dr. Hawkins

**Liver**

The liver is subjectively normal in size, and echogenicity with smooth peripheral margins. The parenchyma is homogenous echotexture. The visible portions of the vasculature and biliary tract appear normal. No focal nodules or cystic lesions are observed. The gallbladder lumen is moderately distended. The wall of the gallbladder is not thickened and has a smooth mucosal surface. Luminal contents are primarily anechoic. The cystic and common bile ducts are normal/not visible.

**INVOICE**

32806

### ***Gastrointestinal***

The stomach contains minimal luminal contents. It measures at a normal thickness of <0.7cm with some variability due to the presence of rugal folds. The distinction of the gastric wall layers is adequate and there is no impression of reduced peristaltic activity. No masses or focal lesions were observed.

The visualized areas of duodenum, jejunum and ileum have a relatively uniform diameter with minimal fluid distension. Wall thickness is normal. Bowel loops follow a curvilinear path with distinct wall layering maintaining the typical 1:3 muscularis:mucosa layer ratio. The duodenum measured as normal and the jejunum measured as normal (0.2 cm.) Visualized peristalsis appears appropriate. There were no focal lesions consistent with obstruction or a mass effect observed.

The ileocecal junction was visualized and exhibited normal intact wall layering and is subjectively of normal thickness. Sections of colon are visualized with formed fecal material and gas shadowing distally. There is no observed focal or generalized colon wall thickening or loss of layering.

### ***Pancreas***

The pancreas is normal and isoechoic to surrounding mesentery. There is no evidence of nodules or cystic lesions. There is no evidence of regional mesenteric inflammation or fluid.

### ***Free Abdomen***

There is a scant amount of free abdominal fluid near the liver. There are some prominent, isoechoic lymph nodes visualized. One lymph node measured 0.69 cm in the midabdomen and another was in the cranial abdomen measuring 0.43 cm. The omentum is generally of normal echogenicity.

### **ULTRASONOGRAPHIC FINDINGS**

Mild mesenteric lymphadenopathy. The prominent abdominal lymph nodes are most consistent with reactive lymphadenitis or lymphoid hyperplasia. Neoplastic infiltration is considered less likely.

Scant free abdominal fluid.

### **INTERPRETATION OF THE FINDINGS & FURTHER RECOMMENDATIONS**

The lesions observed on today's scan are very mild. No focal mass lesions or obstructions are visualized.

- Consider metabolic causes based on bloodwork, ACTH stim results, Liver function testing, Gi panel (TLI/PLI, folate, cobalamin.)
- Consider primary GI causes: Gi parasitism, dietary indiscretion, mild pancreatitis, bacterial dysbiosis, food allergy, IBD and less likely intestinal neoplasia.

Based on the lab work submitted there is not a lot of support for metabolic disease. It is not uncommon to have relatively mild ultrasonographic findings despite significant GI signs. Consider a novel protein/hydrolyzed protein prescription diet.

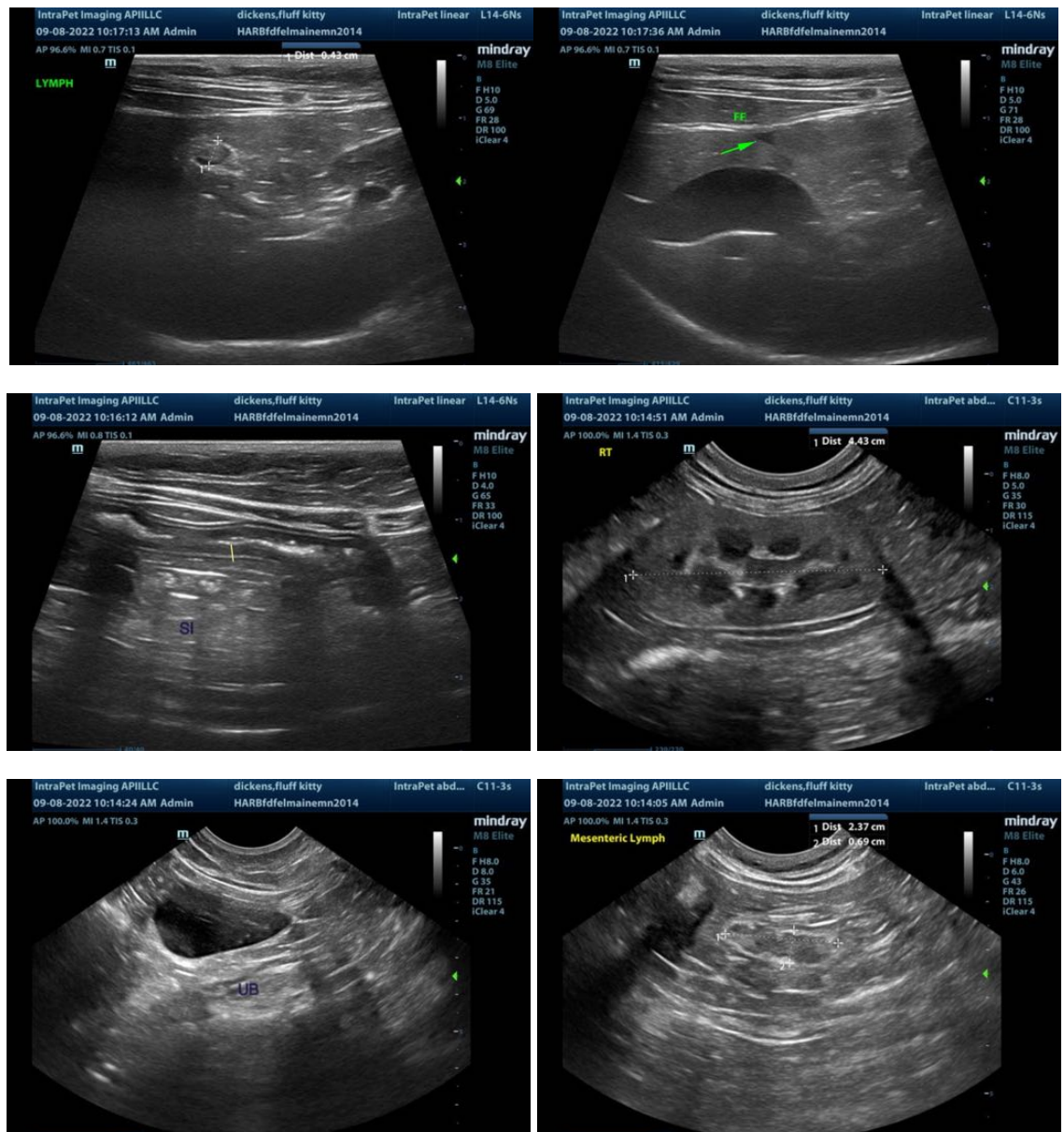
Recommended chronic probiotic therapy.

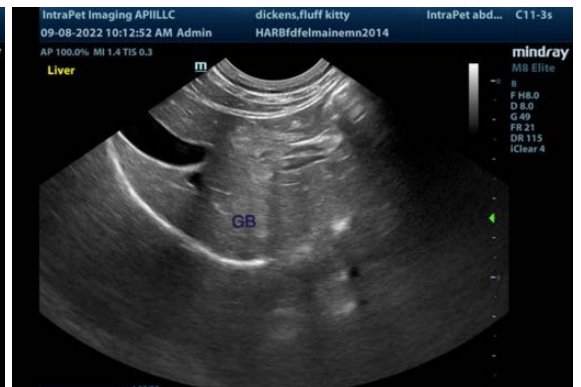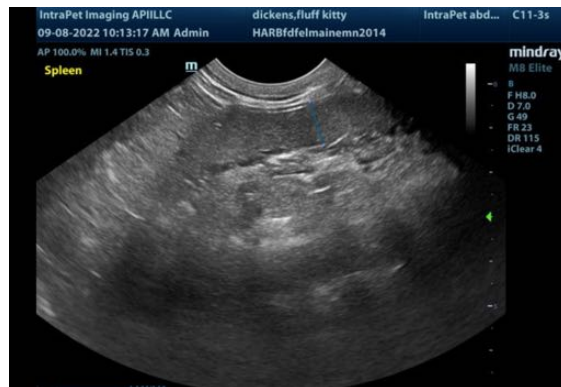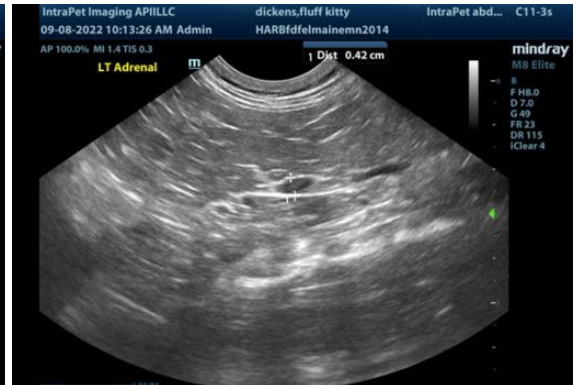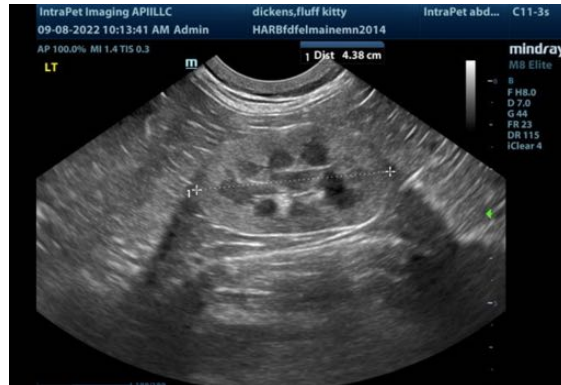Consider a GI panel to Texas A&M for evaluation of B12 levels, folate, PLI/TLI etc.. to further evaluate for pancreatic/small intestinal disease. (as recommended above).

FNA of a mesenteric lymph node can be considered, but I suspect these are relatively small and would be challenging to sample.

If symptoms persist despite the above measures consider obtaining GI biopsies.

Consider three view thoracic radiographs to rule out concurrent thoracic disease/involvement.





The information and recommendations provided are based on the images presented by the referring veterinarian. No evaluation can be communicated regarding pathology that was not visible in the image/video clips provided.

Thank you for this referral. If the clinical or image interpretation does not parallel your findings or if I can be of any further assistance please contact me.

Kathleen Sennello DVM,MS, Diplomate ACVIM (Small animal Internal Medicine)  
kathleen.sennello@sonopath.com