

**DATE**

9/9/21

PRESENTING CLINICAL SIGNS

History: Weight loss but increasing abdomen size- free fluid in abdomen, heart arrhythmia.

Current Medications: N/A

Lab Results: Lab results pending will send results once received.

PATIENT

Date of Previous IntraPet Ultrasound: No previous

Sedation: Gabapentin PO only.

Stat Report: Declined.

Doc Foster

SPECIES

Feline

ULTRASONOGRAPHIC EXAMINATION OF THE ABDOMEN**Urinary System**

The urinary bladder is moderately distended with anechoic urine. The Bladder wall, trigone, ureteral papillae and visible urethra (to a depth of 2cm) appear normal with no evidence of wall thickening, mucosal irregularities, masses or cystic calculi.

BREED

Domestic Shorthair

The left kidney has a normal shape and size (4.84 cm). Overall echogenicity is normal with adequate corticomedullary distinction and a typical 1:3 cortex:medulla ratio. There is no evidence of perinephric inflammation or effusion. There is no evidence of pyelectasia, nephroliths, infarcts or hydroureter. Renal vasculature is normal.

SEX

Neutered male

AGE

2011

The right kidney has a normal shape and size (4.19 cm). Overall echogenicity is normal with adequate corticomedullary distinction and a typical 1:3 cortex:medulla ratio. There is no evidence of perinephric inflammation or effusion. A 0.5 cm, non-obstructive nephrolith was noted. There is no evidence of pyelectasia, infarcts or hydroureter. Renal vasculature is normal.

WEIGHT

11.6 lbs

Adrenal Glands

The left adrenal gland is normal in size. It is observed in its normal position cranial to the left renal artery. It is normal in appearance (uniformly hypoechoic) and shape with no evidence of a mass effect.

INTERPRETED BY

Kathleen Sennello
DVM, MS, Diplomate
ACVIM (Small Animal
Internal Medicine)

The right adrenal gland is normal in size. It is observed in its normal position between the cranial aspect of the right kidney and the caudal vena cava. It is normal in appearance (uniformly hypoechoic) and shape with no evidence of a mass effect.

HOSPITAL NAME

Happy Tails VH

Spleen

The spleen is subjectively normal in size, echotexture is homogenous, and the splenic capsule is smooth with no irregularities. The blood flow through the hilus and splenic parenchyma appears normal. No focal parenchymal abnormalities are visualized.

REFERRING VET

Dr. Calpeno

Liver

The liver is subjectively large in size and hyperechoic. The visible portions of the vasculature and biliary tract appear normal. No focal nodules or cystic lesions are observed. The gallbladder lumen is moderately distended. The wall of the gall bladder is not thickened and has a smooth mucosal surface. Luminal contents are primarily anechoic. The cystic and common bile ducts are normal/not visible.

INVOICE

91753

Gastrointestinal

The stomach contains minimal luminal contents. It measures at a normal thickness of <0.36cm with some variability due to the presence of rugal folds. The distinction of the gastric wall layers is adequate and there is no impression of reduced peristaltic activity. No masses or focal lesions were observed.

The visualized areas of duodenum, jejunum and ileum have a relatively uniform diameter with minimal fluid distension. Wall thickness is normal. Bowel loops follow a curvilinear path with distinct wall layering maintaining the typical 1:3 muscularis:mucosa layer ratio. The duodenum measured as normal (between 0.13-0.38cm in wall thickness) and the jejunum measured as normal (between 0.15-0.36cm.) Visualized peristalsis appears appropriate. There were no focal lesions consistent with obstruction or a mass effect observed.

The ileocecal junction was visualized and exhibited normal intact wall layering and is subjectively of normal thickness. Sections of colon are visualized with formed fecal material and gas shadowing distally. There is no observed focal or generalized colon wall thickening or loss of layering.

Pancreas

The pancreas is normal and isoechoic to surrounding mesentery. There is no evidence of nodules or cystic lesions. There is no evidence of regional mesenteric inflammation or fluid.

Free Abdomen

There is a large volume of free abdominal fluid. No lymphadenomegaly was noted. The omentum is of normal uniform echogenicity.

Other

There is a large, solid, hypoechoic mass located toward the right middle aspect of the abdomen. This is a solid mass with occasional, hyperechoic, mineralized foci. The organ of origin is not clear. Possible differentials would be adrenal gland (seems unlikely due to size), pancreas, liver or spleen with a non-visualized attachment or a free standing mass/lymph node. The mass measures 6.86 x 4.57 cm.

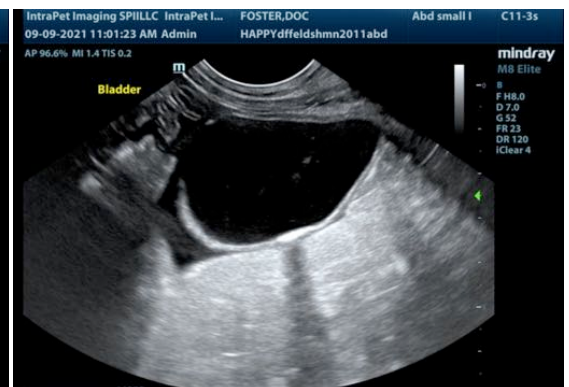
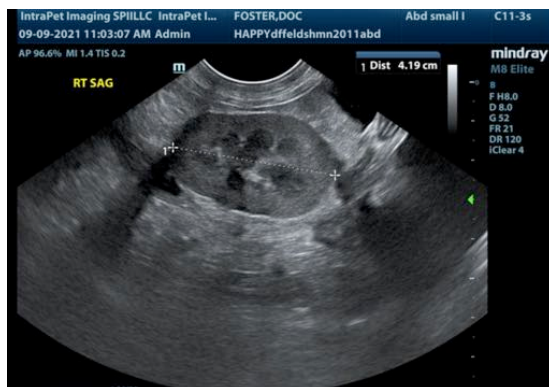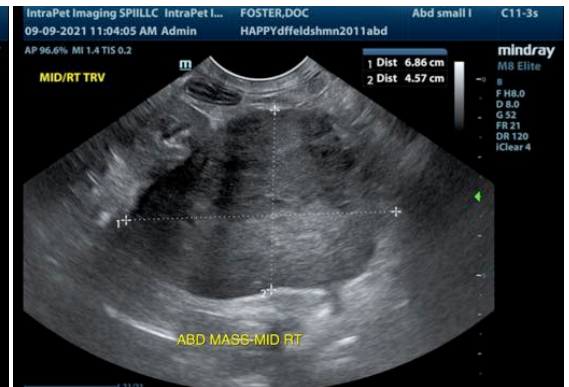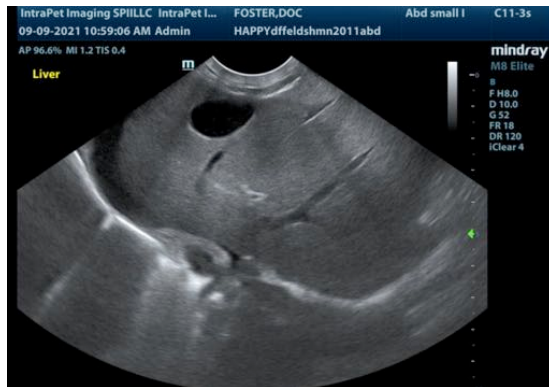
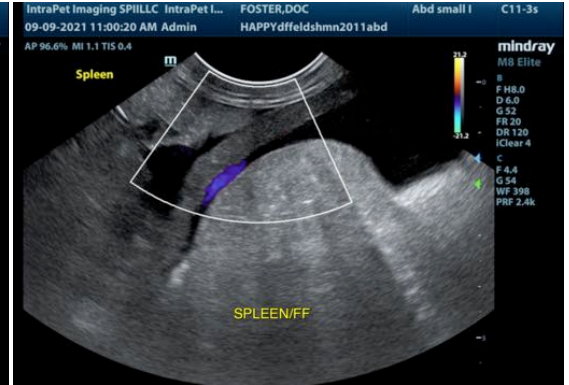
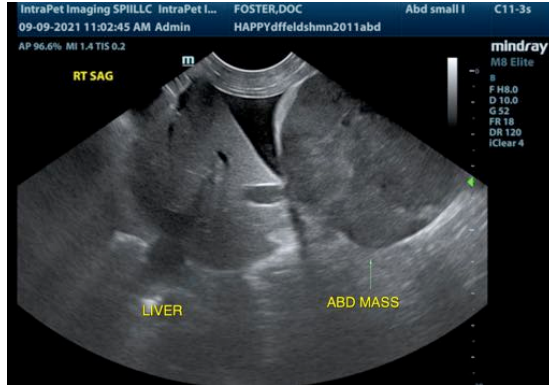ULTRASONOGRAPHIC FINDINGS

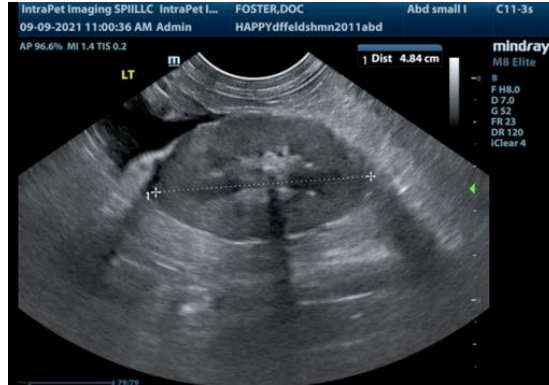PRIMARY FINDINGS:

- Large, non-cavitated abdominal mass. Organ of origin is unclear. I recommend FNA (performed during ultrasound exam) and cytology.
- Large, hyperechoic liver. Hepatic changes are non-specific and could be consistent with hepatic lipidosis, inflammatory/infectious disease, infiltrative neoplasia, or other hepatopathy. The large size of the liver could be partially due to congestion due to the pericardial effusion reported.
- Ascites. This could be due to the abdominal mass (neoplastic effusion) or could be secondary to the pericardial effusion.

INTERPRETATION OF THE FINDINGS & FURTHER RECOMMENDATIONS

There is a large abdominal mass present. You have already sampled this, which is an excellent next step. Three view thoracic radiographs are recommended (if not already done). If this is not a tumor readily treatable with chemotherapy then I recommend advanced imaging to evaluate for possible surgical removal (for therapeutic and diagnostic purposes) (depending on degree of heart disease).





The information and recommendations provided are based on the images presented by the referring veterinarian. No evaluation can be communicated regarding pathology that was not visible in the image/video clips provided.

Thank you for this referral. If the clinical or image interpretation does not parallel your findings or if I can be of any further assistance please contact me.

Kathleen Sennello DVM,MS, Diplomate ACVIM (Small animal Internal Medicine)
kathleen.sennello@sonopath.com