



PATIENT

Augie Dey

PRESENTING CLINICAL SIGNS

SPECIES

Canine

BREED

Aussie X

SEX

Neutered Male

AGE

11 Years 5 Months

WEIGHT

84 Pounds

INTERPRETED BY

Kathleen Sennello DVM,
MS, Diplomate ACVIM

IMAGING BY

Loetitia Saint-Jacques,
LVT

HOSPITAL NAME

MountainView AH

REFERRING VET

Dr. Sarah Kalivoda

INVOICE

25288

DATE

9/9/21

Chief Concern / Provisional Diagnosis: Chronic intermittent diarrhea, possible abdominal mass. 5mm mass on ventral rectum near R anal gland Relevant Medical History and Physical Exam findings: Early 2021, P presented to rDVM for GI issues. At that time, P's liver enzymes were elevated, and a mass near the stomach was seen on u/s along w/ pleural effusion on chest rads. O stated that P was taken for a second opinion, and no abdominal mass was seen. Since then, P has been doing fairly well but continues to have intermittent diarrhea. Abd u/s was recommended to determine if abdominal mass is present and look for possible cause of diarrhea. Recent Diagnostics: Relevant Laboratory Results / Abnormalities: No recent labs. Labs from rDVM in Jan 2021- elevated ALT, crea, and BUN. Current medications (include full name, dosage and frequency): VetriScience Renal Essentials FortiFlora SA Milk thistle Amantadine 100mg PO SID Heartgard, Nexgard

ULTRASONOGRAPHIC EXAMINATION OF THE ABDOMEN

Urinary System

The urinary bladder is moderately distended with anechoic urine. The Bladder wall, trigone, ureteral papillae and visible urethra (to a depth of 2cm) appear normal with no evidence of wall thickening, mucosal irregularities, masses or cystic calculi.

The prostate is normal in size (1.47 cm) and shape for this neutered male dog. The parenchyma is homogenous and the external margins are smooth. The prostatic urethra appears normal with no evidence of irregularity, invasion, mass effect or calculi.

The left kidney has a normal shape and size (5.6 cm). Overall echogenicity is normal with adequate corticomedullary distinction and a typical 1:3 cortex:medulla ratio. There is no evidence of perinephric inflammation or effusion. There is no evidence of pyelectasia, nephroliths, infarcts or hydroureter. Renal vasculature is normal.

The right kidney has a normal shape and size (6.98 cm). Overall echogenicity is normal with adequate corticomedullary distinction and a typical 1:3 cortex:medulla ratio. There is no evidence of perinephric inflammation or effusion. There is no evidence of pyelectasia, nephroliths, infarcts or hydroureter. Renal vasculature is normal.

Adrenal Glands

The left adrenal gland is normal in size measuring 0.63 cm at the caudal pole. It is observed in its normal position cranial to the left renal artery. It is normal in appearance (uniformly hypoechoic) and shape with no evidence of a mass effect.

The region of the right adrenal (between right cranial kidney and vena cava) is unremarkable, but the adrenal is not distinctly visualized. No evidence of a mass effect.

Spleen

The spleen is subjectively normal in size and irregular in shape. The spleen echotexture is heterogenous and mildly mottled. The blood flow through the hilus and splenic parenchyma appears normal. There is a very small, ill-defined, hypoechoic nodule visualized, measured 0.84 cm.

Liver



PATIENT

Augie Dey The liver is subjectively normal in size, and echogenicity with smooth peripheral margins. The parenchyma is heterogenous in echotexture with subtle, indistinct focal mottling. The visible portions of the vasculature and biliary tract appear normal. No focal nodules or cystic lesions are observed.

SPECIES

Canine The gallbladder lumen is moderately distended. The wall of the gall bladder is not thickened and has a smooth mucosal surface. Luminal contents are primarily anechoic. The cystic and common bile ducts are normal/not visible.

BREED

Aussie X **Gastrointestinal**
The stomach contains minimal luminal contents. It measures at a normal thickness of <0.7cm with some variability due to the presence of rugal folds. The distinction of the gastric wall layers is adequate and there is no impression of reduced peristaltic activity. No masses or focal lesions were observed.

SEX

Neutered Male The visualized areas of duodenum, jejunum and ileum have a relatively uniform diameter with minimal fluid distension. Wall thickness is normal. Bowel loops follow a curvilinear path with distinct wall layering maintaining the typical 1:3 muscularis:mucosa layer ratio. Jejunum wall measured 0.36, 0.28, 0.34 cm. Visualized peristalsis appears appropriate. There were no focal lesions consistent with obstruction or a mass effect observed.

AGE

11 Years 5 Months

WEIGHT

84 Pounds

The ileocecal junction was visualized and exhibited normal intact wall layering and is subjectively of normal thickness. Sections of colon are visualized with formed fecal material and gas shadowing distally. There is no observed focal or generalized colon wall thickening or loss of layering.

Pancreas

The pancreas is normal and isoechoic to surrounding mesentery. There is no evidence of nodules or cystic lesions. There is no evidence of regional mesenteric inflammation or fluid.

INTERPRETED BY

Kathleen Sennello DVM,
MS, Diplomate ACVIM

Free Abdomen

Evaluation of the peritoneal cavity did not reveal any evidence of effusion. There is a severe caudal abdominal lymphadenopathy. The sublumbar lymph nodes are prominent and hypoechoic, the right measuring 2.5 cm x 1.2 cm. The left measuring 0.96 cm x 2.3 cm. Additionally, there is a cluster of enlarged lymph nodes ventral to the urinary bladder, measuring up to 1.4 cm in diameter. There is what I suspect to be a subcutaneous lymph node on the left lateral aspect of the prepuce measuring approximately 0.69 cm x 3.5 cm. The omentum is generally of normal uniform echogenicity.

IMAGING BY

Loetitia Saint-Jacques,
LVT

HOSPITAL NAME

MountainView AH

PRIMARY FINDINGS

REFERRING VET

Dr. Sarah Kalivoda

- Caudal abdominal lymphadenopathy – The severe mesenteric lymphadenopathy is most concerning for a neoplastic process, although you can see significant lymphadenopathy in some cases of autoimmune/inflammatory disease, infectious disease (tick born disease-such as bartonella, fungal infections, FIP (cats)) etc. A fine needle aspirate with cytology is recommended for further evaluation. The caudal location of these lymph nodes would be most consistent with a rectal lesion, colonic lesion, etc.

INVOICE

25288

- Mildly mottled spleen with small hypoechoic nodule – There is a non-cavitated, hypoechoic splenic nodule visualized. Differentials include lymphoid hyperplasia, extramedullary

DATE

9/9/21



PATIENT

Augie Dey hematopoiesis, infiltrative neoplasia, inflammation, other. Cytology or histopathology would be necessary to get a definitive diagnosis.

SPECIES

Canine

- Heterogeneous liver – The diffuse hepatic changes are non-specific and could be consistent with vacuolar hepatopathy, nodular hyperplasia, inflammatory/immune-mediated disease, fibrosis, extramedullary hematopoiesis, toxic hepatopathy (e.g., copper), infiltrative neoplasia (less likely) or other hepatopathy.

BREED

Aussie X

SECONDARY FINDINGS

- The prostate is somewhat prominent, measuring 1.4 cm in diameter on the sagittal view. It appears fairly normal in this large dog. If no other source for the caudal abdominal lymphadenomegaly is found, consider fine needle aspirate of the prostate.

SEX

Neutered Male

INTERPRETATION OF THE FINDINGS & FURTHER RECOMMENDATIONS

AGE

11 Years 5 Months

There is a significant caudal abdominal lymphadenomegaly present. This would be typical for metastasis of an anal gland tumor. Perirectal tumor is recommended in the history. Consider fine needle aspirate of this lesion. Additionally, it could be consistent with a colonic lesion or anything in the pelvic region. I suspect the lymph node lateral to the prepuce is subcutaneous, and may be very readily aspirated. Otherwise, consider ultrasound guidance to aspirate one of the intrapelvic lymph nodes.

WEIGHT

84 Pounds

Additionally, the lymphadenopathy could be associated with an intestinal or colonic lesion. It is not clear if this is large or small bowel diarrhea, so a fine needle aspirate would be helpful for this issue as well. I do not see evidence of a gastric lesion on today's scan. These can be challenging due to the changing rugal folds and gas shadowing in the stomach, but this was not observed on today's scan. There are mild changes associated with the spleen and liver. Given the elevated liver values, you could consider testing for Leptospirosis and a fine needle aspirate of the liver in addition to a liver function test. No focal lesions were observed associated with the liver or the GI tract.

INTERPRETED BY

Kathleen Sennello DVM,
MS, Diplomate ACVIM

IMAGING BY

Loetitia Saint-Jacques,
LVT

HOSPITAL NAME

MountainView AH

The most common causes for primary diarrhea include GI parasitism, dietary indiscretion, bacterial dysbiosis, food allergy, IBD, and less likely intestinal neoplasia. Consider a diet trial with either a hydrolyzed protein diet, a low fat diet, or a high fiber diet (responses to food vary with individuals). Consider GI panel for evaluation of B12 levels, folate, and a PLI. If the diarrhea is progressing despite therapy, GI biopsies may be necessary. If a fine needle aspirate of the right-sided perianal mass and lymph node does not provide a diagnosis, then consider surgery to biopsy an intraabdominal lymph node, bowel and liver in addition to removing the perianal/anal gland mass. Recommend 3-view thoracic radiographs.

REFERRING VET

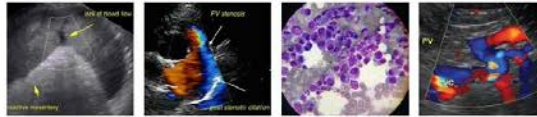
Dr. Sarah Kalivoda

INVOICE

25288

DATE

9/9/21



PATIENT

Augie Dey

SPECIES

Canine

BREED

Aussie X

SEX

Neutered Male

AGE

11 Years 5 Months

WEIGHT

84 Pounds

INTERPRETED BY

Kathleen Sennello DVM,
MS, Diplomate ACVIM

IMAGING BY

Loetitia Saint-Jacques,
LVT

HOSPITAL NAME

MountainView AH

REFERRING VET

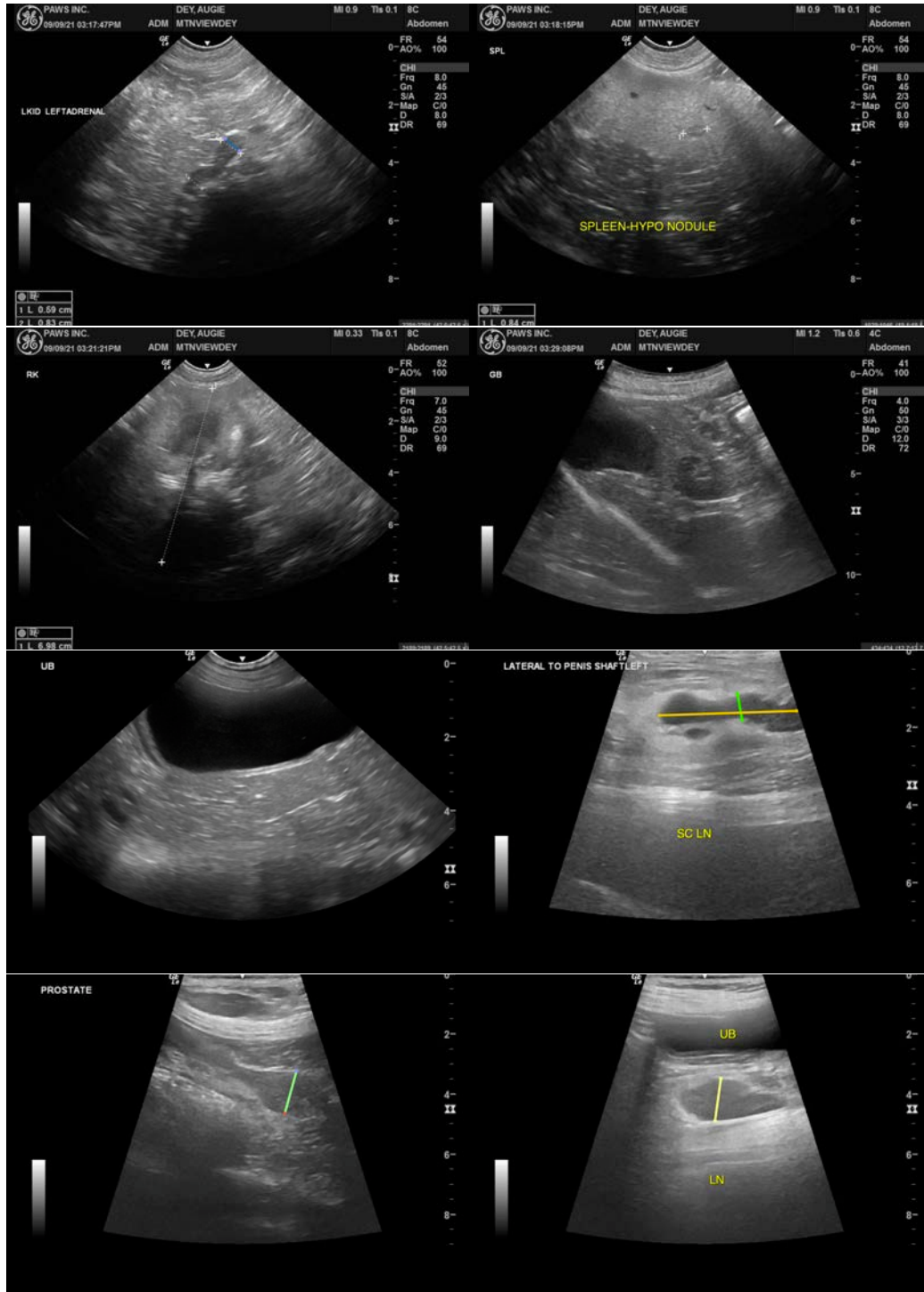
Dr. Sarah Kalivoda

INVOICE

25288

DATE

9/9/21





PATIENT

Augie Dey

SPECIES

Canine

BREED

Aussie X

SEX

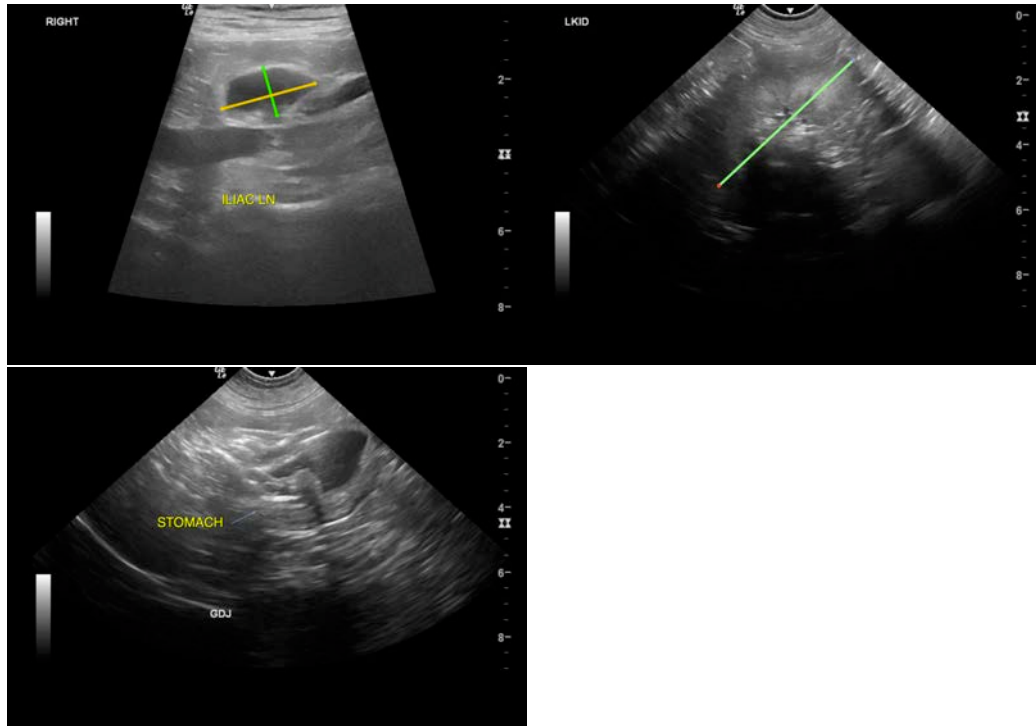
Neutered Male

AGE

11 Years 5 Months

WEIGHT

84 Pounds



INTERPRETED BY

Kathleen Sennello DVM,
MS, Diplomate ACVIM

IMAGING BY

Loetitia Saint-Jacques,
LVT

HOSPITAL NAME

MountainView AH

REFERRING VET

Dr. Sarah Kalivoda

INVOICE

25288

DATE

9/9/21

The information and recommendations provided are based on the images presented by the referring veterinarian. No evaluation can be communicated regarding pathology that was not visible in the image/video clips provided.

Thank you for this referral. If the clinical or image interpretation does not parallel your findings or if I can be of any further assistance please contact me.

Kathleen Sennello DVM,MS, Diplomate ACVIM (Small animal Internal Medicine)
kathleen.sennello@sonopath.com