

**PATIENT**

Angel Webster

**PRESENTING CLINICAL SIGNS**

Chief Concern / Provisional Diagnosis: ~elevated LE and Bile Acids~ Relevant Laboratory Results / Abnormalities: ~ 5/1/21 ALT 334 18 - 121 U/L 6/7/21 ALT 362 10 - 125 U/L 8/10/21 ALT 750 10 - 125 U/L ALP 3723 - 212 U/L 8/21/21 AST 66 16 - 55 U/L Creatine Kinase 124 10 - 200 U/L Bile Acids Preprandial / Random 3.6 0.0 - 14.9 µmol/L Bile Acids Postprandial 50.9 0.0 - 29.9 µmol/L~

**SPECIES**

Canine

**ULTRASONOGRAPHIC EXAMINATION OF THE ABDOMEN**

**BREED**

Chihuahua Long Hair

**Urinary System**

The urinary bladder is moderately distended with anechoic urine. The Bladder wall, trigone, ureteral papillae and visible urethra (to a depth of 2cm) appear normal with no evidence of wall thickening, mucosal irregularities, masses or cystic calculi.

**SEX**

Spayed Female

The left kidney has a normal shape and size (3.34 cm). Overall echogenicity is normal with adequate corticomedullary distinction and a typical 1:3 cortex:medulla ratio. There is no evidence of perinephric inflammation or effusion. There is no evidence of pyelectasia, nephroliths, infarcts or hydroureter. Renal vasculature is normal.

**AGE**

1 Year 7 Months

The right kidney has a normal shape and size (3.63 cm). Overall echogenicity is normal with adequate corticomedullary distinction and a typical 1:3 cortex:medulla ratio. There is no evidence of perinephric inflammation or effusion. There is no evidence of pyelectasia, nephroliths, infarcts or hydroureter. Renal vasculature is normal.

**WEIGHT**

10.5 Pounds

**Adrenal Glands**

The left adrenal gland is normal in size measuring 0.4 cm at the caudal pole. It is observed in its normal position cranial to the left renal artery. It is normal in appearance (uniformly hypoechoic) and shape with no evidence of a mass effect.

The right adrenal gland is normal in size measuring 0.26 cm at the caudal pole. It is observed in its normal position between the cranial aspect of the right kidney and the caudal vena cava. It is normal in appearance (uniformly hypoechoic) and shape with no evidence of a mass effect.

**INTERPRETED BY**

Kathleen Sennello DVM,  
MS, Diplomate ACVIM  
(Small Animal Internal  
Medicine)

**IMAGING PERFORMED BY**

Loetitia Saint-Jacques, RVT

**HOSPITAL NAME**

MountainView AH

**Spleen**

The spleen is subjectively normal in size, echotexture is homogenous, and the splenic capsule is smooth with no irregularities. The blood flow through the hilus and splenic parenchyma appears normal. No focal parenchymal abnormalities are visualized.

**Liver**

The liver is subjectively small in size and decreased in echogenicity with smooth peripheral margins. The parenchyma is homogenous echotexture. the portal markings appear adequate. The ratio of portal vein to vena cava is appropriate. No focal nodules or cystic lesions are observed.

**REFERRING VET**

Dr. Sarah Kalivoda

**INVOICE**

25283

The gallbladder lumen is moderately distended. The wall of the gall bladder is not thickened and has a smooth mucosal surface. Luminal contents are primarily anechoic. The cystic and common bile ducts are normal/not visible.

**DATE**

9/9/21



**PATIENT**

Angel Webster

***Gastrointestinal***

The stomach contains minimal luminal contents. It measures at a normal thickness of <0.7cm with some variability due to the presence of rugal folds. The distinction of the gastric wall layers is adequate and there is no impression of reduced peristaltic activity. No masses or focal lesions were observed.

**SPECIES**

Canine

The visualized areas of duodenum, jejunum and ileum have a relatively uniform diameter with minimal fluid distension. Wall thickness is normal. Bowel loops follow a curvilinear path with distinct wall layering maintaining the typical 1:3 muscularis:mucosa layer ratio. Jejunum wall measured 0.3 cm. Visualized peristalsis appears appropriate. There were no focal lesions consistent with obstruction or a mass effect observed.

**BREED**

Chihuahua Long Hair

**SEX**

Spayed Female

The ileocecal junction was visualized and exhibited normal intact wall layering and is subjectively of normal thickness. Sections of colon are visualized with formed fecal material and gas shadowing distally. There is no observed focal or generalized colon wall thickening or loss of layering.

***Pancreas***

**AGE**

1 Year 7 Months

The pancreas is prominent and hypoechoic as compared to the surrounding isoechoic mesentery. There is no evidence of nodules or cystic lesions. There is no evidence of regional mesenteric inflammation or fluid.

**WEIGHT**

10.5 Pounds

***Free Abdomen***

Evaluation of the peritoneal cavity did not reveal any evidence of effusion. There is a mild lymphadenopathy present. A sublumbar lymph node is visualized and measures 0.41 cm in diameter. The omentum is of normal uniform echogenicity.

**INTERPRETED BY**

Kathleen Sennello DVM,  
MS, Diplomate ACVIM  
(Small Animal Internal  
Medicine)

**ULTRASONOGRAPHIC FINDINGS**

- Subjectively small liver – I don't see any evidence of a large shunt, but the liver does appear small. Consider a non-visualized shunt, microvascular dysplasia, etc.
- Hypoechoic, prominent pancreas – The pancreatic changes are most consistent with mild pancreatitis or a recent episode of pancreatic inflammation.
- Mild mesenteric lymphadenopathy – The prominent abdominal lymph nodes are most consistent with reactive lymphadenitis or lymphoid hyperplasia. Neoplastic infiltration is considered less likely.

**IMAGING PERFORMED BY**

Loetitia Saint-Jacques, RVT

**HOSPITAL NAME**

MountainView AH

**INTERPRETATION OF THE FINDINGS & FURTHER RECOMMENDATIONS**

The liver does appear somewhat small, though I do not see any evidence of a shunt. These can be small and difficult to see with ultrasound. Additionally, the bile acids while elevated are not as elevated as you would expect to see with a typical shunt. Definitive diagnosis would likely be achieved by performing a contrast CT scan and liver biopsy (for microvascular dysplasia etc.). Alternately, you could consider having a veterinary surgeon perform a liver biopsy and grossly examine the liver at that time for evidence of an extrahepatic shunt. Unfortunately, I believe a liver biopsy would be necessary to determine the cause of the ALT elevation unless it is a transient change due to acute liver injury. Consider testing for Leptospirosis and starting Denamarin.

**REFERRING VET**

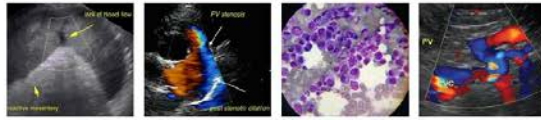
Dr. Sarah Kalivoda

**INVOICE**

25283

**DATE**

9/9/21



**PATIENT**

Angel Webster

**SPECIES**

Canine

**BREED**

Chihuahua Long Hair

**SEX**

Spayed Female

**AGE**

1 Year 7 Months

**WEIGHT**

10.5 Pounds

**INTERPRETED BY**

Kathleen Sennello DVM,  
MS, Diplomate ACVIM  
(Small Animal Internal  
Medicine)

**IMAGING PERFORMED BY**

Loetitia Saint-Jacques, RVT

**HOSPITAL NAME**

MountainView AH

**REFERRING VET**

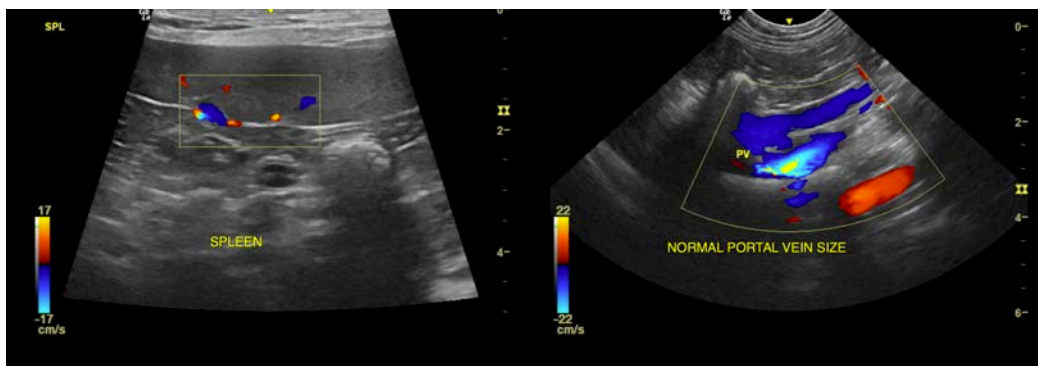
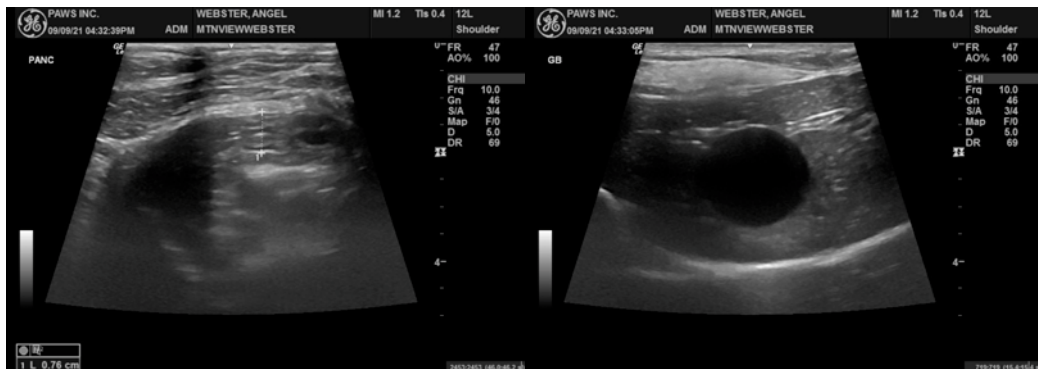
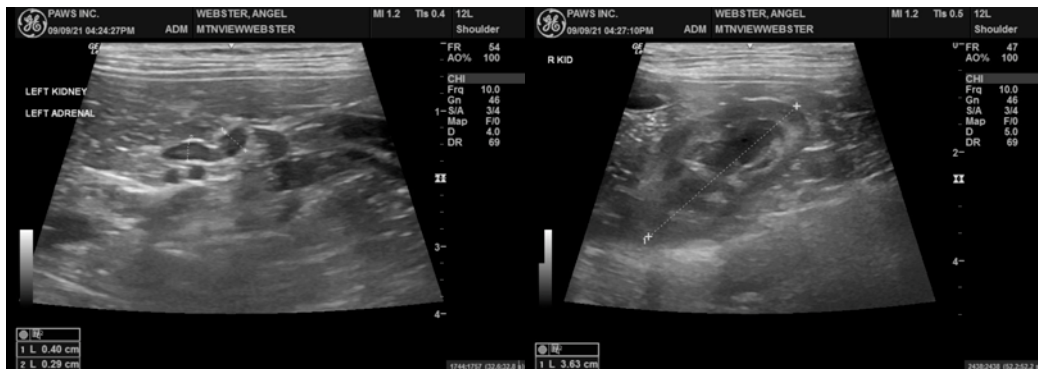
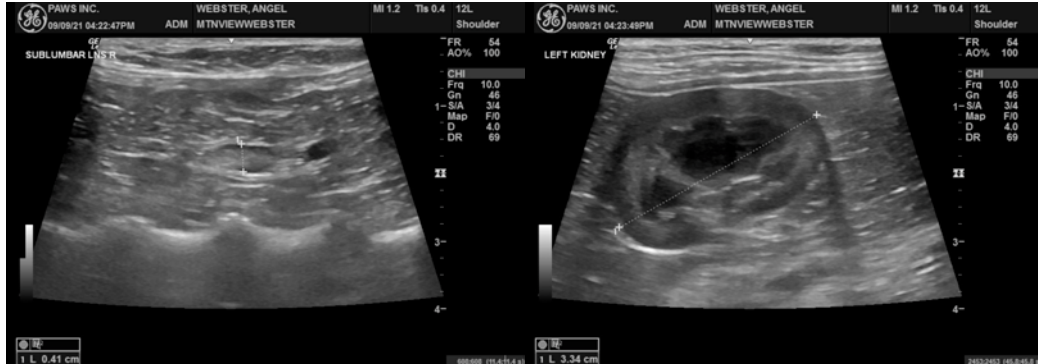Dr. Sarah Kalivoda

**INVOICE**

25283

**DATE**

9/9/21





**PATIENT**

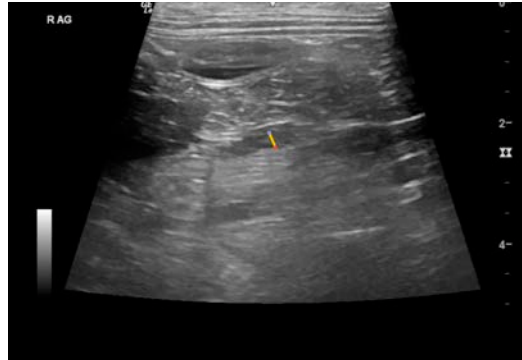
Angel Webster

**SPECIES**

Canine

**BREED**

Chihuahua Long Hair



**SEX**

Spayed Female

**AGE**

1 Year 7 Months

**WEIGHT**

10.5 Pounds

The information and recommendations provided are based on the images presented by the referring veterinarian. No evaluation can be communicated regarding pathology that was not visible in the image/video clips provided.

Thank you for this referral. If the clinical or image interpretation does not parallel your findings or if I can be of any further assistance please contact me.

Kathleen Sennello DVM,MS, Diplomate ACVIM (Small animal Internal Medicine)

kathleen.sennello@sonopath.com

**INTERPRETED BY**

Kathleen Sennello DVM,  
MS, Diplomate ACVIM  
(Small Animal Internal  
Medicine)

**IMAGING PERFORMED BY**

Loetitia Saint-Jacques, RVT

**HOSPITAL NAME**

MountainView AH

**REFERRING VET**

Dr. Sarah Kalivoda

**INVOICE**

25283

**DATE**

9/9/21