



**PATIENT**

Bella Mia Murray

**PRESENTING CLINICAL SIGNS**

Originally presented for concerns for bladder stones due to pollakiuria attention to the ear end. This was done with another DVM. Radiographic assessment normal. AUS for completion of abdominal assessment.

**SPECIES**

Canine

Abnormal PE/Chem/CBC/UA Results: Pyuria with rods recently treated with previous DVM. August: ALT 15q, ALP 228. Renal values well within normal limits. Collected fasted blood today and sterile urine just in case.

**BREED**

Mini Schnauzer

**ULTRASONOGRAPHIC EXAMINATION OF THE ABDOMEN**

**Urinary System**

**SEX**

Spayed Female

The urinary bladder is moderately distended with anechoic urine. The Bladder wall is diffusely mildly thickened (0.19 cm), and the mucosa is mildly irregular. The trigone, ureteral papillae, and visible urethra (to a depth of 2cm) appear normal with no evidence of severe mucosal irregularities, masses or cystic calculi. Findings are most consistent with bacterial cystitis or lack of urine distension.

**AGE**

9 Years

Recommend urinalysis and culture.

**WEIGHT**

15 Pounds

The left kidney has a normal shape and size (3.6 cm) with non-obstructive nephroliths/mineralizations. Overall echogenicity is normal with adequate corticomedullary distinction and a typical 1:3 cortex:medulla ratio. There is no evidence of focal perinephric inflammation or effusion. There is no evidence of pyelectasia, infarcts or hydroureter. Renal vasculature is normal.

The right kidney has a normal shape and size (3.9 cm) with small non-obstructive nephroliths/mineralizations. Overall echogenicity is normal with adequate corticomedullary distinction and a typical 1:3 cortex:medulla ratio. There is no evidence of focal perinephric inflammation or effusion. There is no evidence of pyelectasia, infarcts or hydroureter. Renal vasculature is normal.

**INTERPRETED BY**

Kathleen Sennello DVM,  
MS, Diplomate ACVIM  
(Small Animal Internal  
Medicine)

**Adrenal Glands**

The left adrenal gland is normal in size measuring 0.49 cm at the caudal pole. It is observed in its normal position cranial to the left renal artery. It is normal in appearance (uniformly hypoechoic) and shape with no evidence of a mass effect.

**IMAGING**

**PERFORMED BY**

Dr. Sorbo

The right adrenal gland is normal in size measuring 0.45 cm at the caudal pole. It is observed in its normal position between the cranial aspect of the right kidney and the caudal vena cava. It is normal in appearance (uniformly hypoechoic) and shape with no evidence of a mass effect.

**HOSPITAL NAME**

Mill Brook AC

**Spleen**

The spleen is subjectively normal in size, echotexture is homogenous, and the splenic capsule is smooth with no irregularities. The blood flow through the hilus and splenic parenchyma appears normal. No focal parenchymal abnormalities are visualized.

**REFERRING VET**

Dr. Sorbo

**Liver**

The liver is subjectively normal in size, and echogenicity with smooth peripheral margins. The parenchyma is mildly heterogenous in echotexture with subtle, indistinct focal mottling. The visible portions of the vasculature and biliary tract appear normal. No focal nodules or cystic lesions are observed.

**INVOICE**

41147

**DATE**

9/8/22



**PATIENT**

Bella Mia Murray

The gall bladder lumen is moderately distended. The wall of the gall bladder is not thickened and has a smooth mucosal surface. There is a moderate amount of non-organized echogenic debris. The cystic and common bile ducts are normal/not visible.

**SPECIES**

Canine

**Gastrointestinal**

The stomach contains moderate shadowing ingesta. It measures at a normal thickness of <0.7cm with some variability due to the presence of rugal folds. The distinction of the gastric wall layers is adequate and there is no impression of reduced peristaltic activity. No masses or focal lesions were observed.

**BREED**

Mini Schnauzer

The visualized areas of duodenum, jejunum and ileum have a relatively uniform diameter with minimal fluid distension. Wall thickness is normal. Bowel loops follow a curvilinear path with distinct wall layering maintaining the typical 1:3 muscularis:mucosa layer ratio. Jejunum wall measures 0.33 cm. Duodenum wall measured 0.41 cm. Visualized peristalsis appears appropriate. There were no focal lesions consistent with obstruction or a mass effect observed.

**SEX**

Spayed Female

The ileocecal junction was visualized and exhibited normal intact wall layering and is subjectively of normal thickness. Sections of colon are visualized with formed fecal material and gas shadowing distally. There is no observed focal or generalized colon wall thickening or loss of layering.

**AGE**

9 Years

**Pancreas**

The pancreas is normal and isoechoic to surrounding mesentery. There is no evidence of nodules or cystic lesions. There is no evidence of regional mesenteric inflammation or fluid.

**WEIGHT**

15 Pounds

**Free Abdomen**

Evaluation of the peritoneal cavity did not reveal any evidence of effusion, or subjective lymphadenomegaly. The Medial iliac nodes appear normal and there was no evidence of a caudal aortic thrombus at the bifurcation. The omentum is of normal uniform echogenicity.

**INTERPRETED BY**

Kathleen Sennello DVM,  
MS, Diplomate ACVIM  
(Small Animal Internal  
Medicine)

**ULTRASONOGRAPHIC FINDINGS**

- Mildly thickened/irregular urinary bladder wall – The bladder mucosal changes could be consistent with cystitis or artifactual due to lack of adequate luminal distension. Bladder neoplasia cannot be ruled out but is considered unlikely in this patient.
- Mildly heterogeneous liver – The diffuse hepatic changes are non-specific and could be consistent with vacuolar hepatopathy, nodular hyperplasia, inflammatory/immune-mediated disease, fibrosis, extramedullary hematopoiesis, toxic hepatopathy (e.g., copper), infiltrative neoplasia (less likely) or other hepatopathy.
- Moderate gallbladder debris – The significance of the aggregated gallbladder debris is unclear. This could represent an early mucocele, cholestasis, or may be secondary to fasting but seems unlikely to be causing a current issue. Recommend continued monitoring.
- Hard shadowing material visualized within the gastric lumen – Correlate with the feeding history and abdominal radiographs. If the patient was adequately fasted consider such differentials as delayed gastric emptying, a partial outflow tract obstruction (none seen) or ingested foreign material.

**IMAGING PERFORMED BY**

Dr. Sorbo

**HOSPITAL NAME**

Mill Brook AC

**REFERRING VET**

Dr. Sorbo

**INVOICE**

41147

**INTERPRETATION OF THE FINDINGS & FURTHER RECOMMENDATIONS**

No stones or mass lesions are visualized in the urinary bladder, but the bladder wall is slightly irregular and thickened. These findings are most consistent with cystitis/lack of urine distention of the urinary

**DATE**

9/8/22



**PATIENT**

bladder. Recommend urinalysis and culture.

Bella Mia Murray

The liver is moderately heterogeneous. This is a non-specific finding. No focal lesions were visualized associated with the liver, but there was a moderate amount of debris in the gallbladder. There was no significant inflammation surrounding the gallbladder, so I suspect this is an incidental finding, but continued monitoring is warranted. For further evaluation of the liver enzyme elevation, you could consider:

**SPECIES**

Canine

**BREED**

Mini Schnauzer

**SEX**

Spayed Female

**AGE**

9 Years

**WEIGHT**

15 Pounds

- Consider close evaluation of history for possible toxic changes examine medications, diet, dietary indiscretion etc...
- Consider PCR on urine/serum for leptospirosis (if not on antibiotics)/serology if recent antibiotic history
- If not already done, consider pre and post prandial bile acids to evaluate liver function
- If the ALP is significantly elevated relative to the ALT and symptoms consistent with Cushing's are present, consider adrenal function testing (ACTH stim)
- Consider Fine needle aspirate if round cell neoplasia is on your differentia list (25 g needle, normal coags)
- If no response to supportive care (Denamarin, fluids, antibiotics, +/- ursodiol etc.) Consider liver biopsy with samples obtained for histopathology, culture, and copper levels.

**INTERPRETED BY**

Kathleen Sennello DVM,  
MS, Diplomate ACVIM  
(Small Animal Internal  
Medicine)

There is focal shadowing material visualized within the gastric lumen. Correlate this with feeding history and abdominal radiographs. If the patient was adequately fasted, consider the possibility of ingested foreign material. There is no evidence of an obstruction.

The spleen is somewhat "full", but I did not see any focal lesions. If there is concern about an area at the head of the spleen, then consider a recheck evaluation in 4-6 weeks. I feel that the head of the spleen is always more difficult to evaluate.

**IMAGING PERFORMED BY**

Dr. Sorbo

**HOSPITAL NAME**

Mill Brook AC

**REFERRING VET**

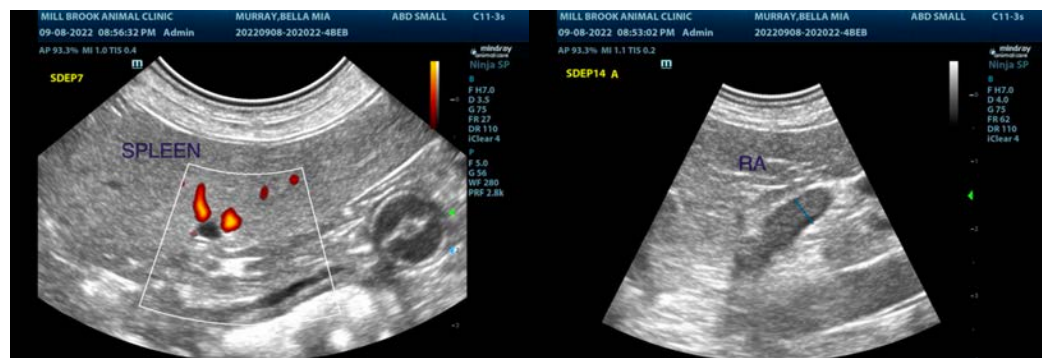
Dr. Sorbo

**INVOICE**

41147

**DATE**

9/8/22





**PATIENT**

Bella Mia Murray

**SPECIES**

Canine

**BREED**

Mini Schnauzer

**SEX**

Spayed Female

**AGE**

9 Years

**WEIGHT**

15 Pounds

**INTERPRETED BY**

Kathleen Sennello DVM,  
MS, Diplomate ACVIM  
(Small Animal Internal  
Medicine)

**IMAGING  
PERFORMED BY**

Dr. Sorbo

**HOSPITAL NAME**

Mill Brook AC

**REFERRING VET**

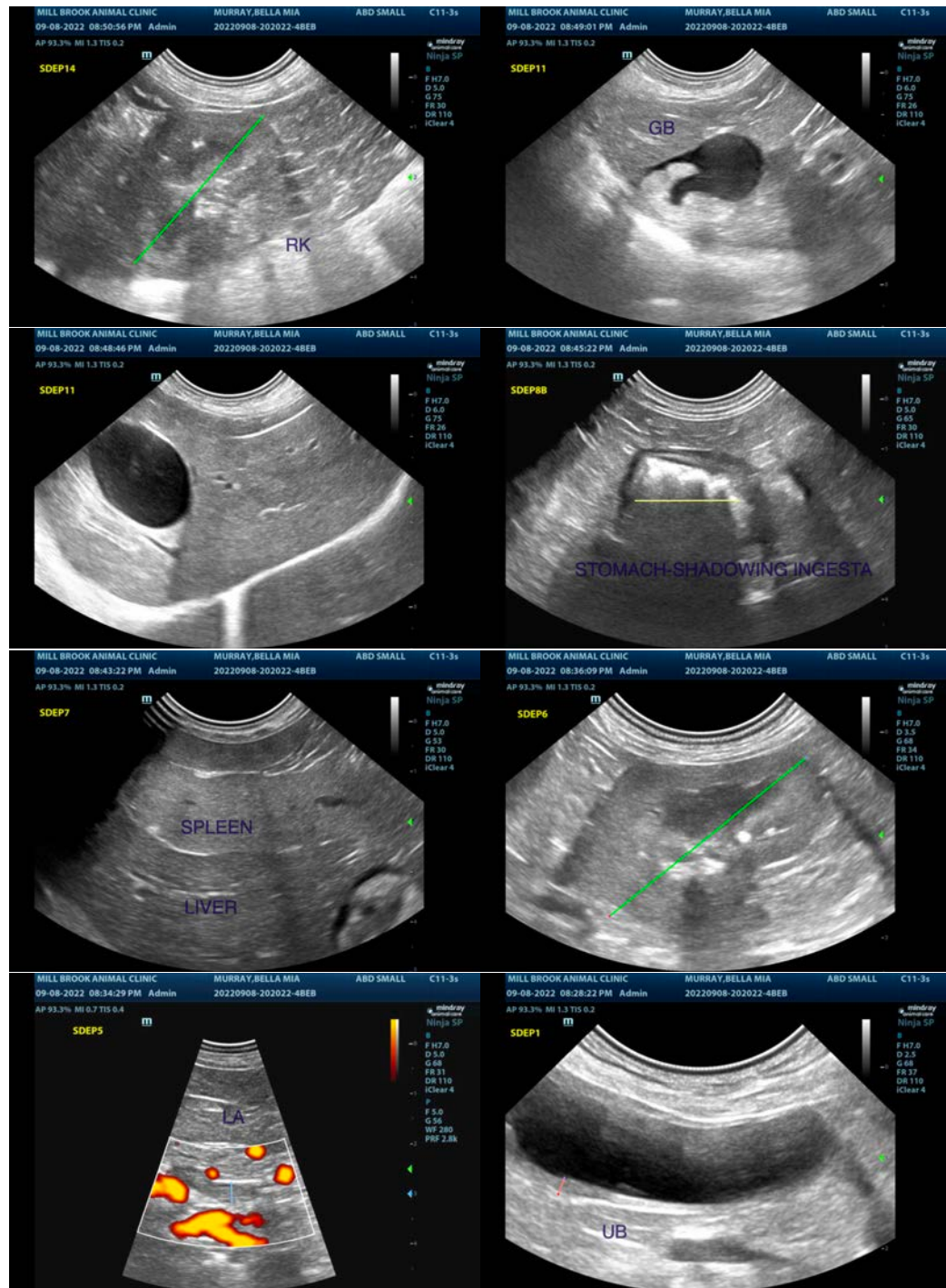
Dr. Sorbo

**INVOICE**

41147

**DATE**

9/8/22





**PATIENT**

Bella Mia Murray

**SPECIES**

Canine

**BREED**

Mini Schnauzer

**SEX**

Spayed Female

**AGE**

9 Years

**WEIGHT**

15 Pounds

**INTERPRETED BY**

Kathleen Sennello DVM,  
MS, Diplomate ACVIM  
(Small Animal Internal  
Medicine)

**IMAGING  
PERFORMED BY**

Dr. Sorbo

**HOSPITAL NAME**

Mill Brook AC

**REFERRING VET**

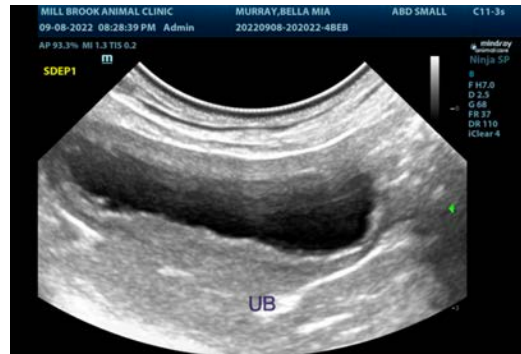Dr. Sorbo

**INVOICE**

41147

**DATE**

9/8/22



The information and recommendations provided are based on the images presented by the referring veterinarian/sonographer. No evaluation can be communicated regarding pathology that was not visible in the image/video clips provided.

Thank you for this referral. If the clinical or image interpretation does not parallel your findings or if I can be of any further assistance please contact me.

Kathleen Sennello DVM,MS, Diplomate ACVIM (Small animal Internal Medicine)

kathleen.sennello@sonopath.com