



**PATIENT**

Nacho Flores

**SPECIES**

Canine

**BREED**

Beagle

**SEX**

Neutered Male

**AGE**

9 Years

**WEIGHT**

37 Pounds

**INTERPRETED BY**

Kathleen Sennello DVM,  
MS, Diplomate ACVIM  
(Small Animal Internal  
Medicine)

**IMAGING  
PERFORMED BY**

Dr. Cassels-Conway

**HOSPITAL NAME**

Central Broward AH

**REFERRING VET**

Dr. Cassels-Conway

**INVOICE**

41089

**DATE**

9/7/22

**PRESENTING CLINICAL SIGNS**

History of splenic mass on tail of spleen, hepatomegaly and prostatomegaly, last AUS performed 5/6/21. P has been neutered since. AUS performed today to recheck splenic nodule. Bloodwork pending.

Abnormal PE/Chem/CBC/UA Results: 5/6/21 CBC: WNL CHEM: WNL T4: WNL U/A: 1.036, 2+ protein, 2+ bili PT WNL PTT WNL Fibrinogen WNL DDimer WNL Platelet WNL

**ULTRASONOGRAPHIC EXAMINATION OF THE ABDOMEN**

**Urinary System**

The urinary bladder is moderately distended with anechoic urine. The Bladder wall, trigone, ureteral papillae and visible urethra (to a depth of 2cm) appear normal with no evidence of wall thickening, mucosal irregularities, masses or cystic calculi.

The prostate is normal in size (1.2 cm) and shape for this neutered male dog. The parenchyma is homogenous and the external margins are smooth. The prostatic urethra appears normal with no evidence of irregularity, invasion, mass effect or calculi. (Previous measurements prior to recent neutering were 4.1 cm x 2.9 cm).

The left kidney has a normal shape and size (5.45 cm). Overall echogenicity is normal with adequate corticomedullary distinction and a typical 1:3 cortex:medulla ratio. There is no evidence of focal perinephric inflammation or effusion. There is no evidence of pyelectasia, nephroliths, infarcts or hydroureter. Renal vasculature is normal.

The right kidney has a normal shape and size (5.08 cm). Overall echogenicity is normal with adequate corticomedullary distinction and a typical 1:3 cortex:medulla ratio. There is no evidence of focal perinephric inflammation or effusion. There is no evidence of pyelectasia, nephroliths, infarcts or hydroureter. Renal vasculature is normal.

**Adrenal Glands**

The left adrenal gland is normal in size measuring 0.54 cm at the caudal pole. It is observed in its normal position cranial to the left renal artery. It is normal in appearance (uniformly hypoechoic) and shape with no evidence of a mass effect.

The right adrenal gland is normal in size measuring 0.70 cm at the caudal pole. It is observed in its normal position between the cranial aspect of the right kidney and the caudal vena cava. It is normal in appearance (uniformly hypoechoic) and shape with no evidence of a mass effect.

**Spleen**

The spleen is subjectively normal in size, echotexture is homogenous, and the splenic capsule is smooth with no irregularities. The blood flow through the hilus and splenic parenchyma appears normal. There is a hypoechoic, slightly cavitated mass lesion towards the tail of the spleen measuring 1.87 cm x 1.29 cm (previous lesion size was 1.34 cm x 1.19 cm when scanned 5/6/21).

**Liver**

The liver is subjectively normal in size, and echogenicity with smooth peripheral margins. The parenchyma is heterogenous in echotexture with subtle, indistinct focal mottling. The visible portions of the vasculature and biliary tract appear normal. No focal nodules or cystic lesions are observed.



**PATIENT**

Nacho Flores

The gall bladder lumen is moderately distended. The wall of the gall bladder is not thickened and has a smooth mucosal surface. There is a moderate amount of non-organized echogenic debris. The cystic and common bile ducts are normal/not visible.

**SPECIES**

Canine

**Gastrointestinal**

The stomach contains minimal luminal contents. It measures at a normal thickness of <0.7cm with some variability due to the presence of rugal folds. The distinction of the gastric wall layers is adequate and there is no impression of reduced peristaltic activity. No masses or focal lesions were observed.

**BREED**

Beagle

The visualized areas of duodenum, jejunum and ileum have a relatively uniform diameter with minimal fluid distension. Wall thickness is normal. Bowel loops follow a curvilinear path with distinct wall layering maintaining the typical 1:3 muscularis:mucosa layer ratio. The duodenum measured as normal (between 0.3-0.5cm in wall thickness) and the jejunum measured as normal (between 0.2-0.47cm.)

**SEX**

Neutered Male

Visualized peristalsis appears appropriate. There were no focal lesions consistent with obstruction or a mass effect observed.

**AGE**

9 Years

The ileocecal junction was visualized and exhibited normal intact wall layering and is subjectively of normal thickness. Sections of colon are visualized with formed fecal material and gas shadowing distally. There is no observed focal or generalized colon wall thickening or loss of layering.

**Pancreas**

The pancreas is normal and isoechoic to surrounding mesentery. There is no evidence of nodules or cystic lesions. There is no evidence of regional mesenteric inflammation or fluid.

**WEIGHT**

37 Pounds

**Free Abdomen**

Evaluation of the peritoneal cavity did not reveal any evidence of effusion, or subjective lymphadenomegaly. The Medial iliac nodes appear normal and there was no evidence of a caudal aortic thrombus at the bifurcation. The omentum is of normal uniform echogenicity.

**INTERPRETED BY**

Kathleen Sennello DVM,  
MS, Diplomate ACVIM  
(Small Animal Internal  
Medicine)

**ULTRASONOGRAPHIC FINDINGS**

- Hypoechoic, irregular splenic nodule – There is a non-cavitated, hypoechoic splenic nodule visualized. Differentials include lymphoid hyperplasia, extramedullary hematopoiesis, infiltrative neoplasia, inflammation, other. Cytology or histopathology would be necessary to get a definitive diagnosis.
- Mildly heterogeneous liver – The diffuse hepatic changes are non-specific and could be consistent with vacuolar hepatopathy, nodular hyperplasia, inflammatory/immune-mediated disease, fibrosis, extramedullary hematopoiesis, toxic hepatopathy (e.g., copper), infiltrative neoplasia (less likely) or other hepatopathy. In the absence of liver enzyme elevations, the significance of this is unclear.
- Moderate gallbladder debris – The significance of the aggregated gallbladder debris is unclear. This could represent an early mucocele, cholestasis, or may be secondary to fasting but seems unlikely to be causing a current issue. Recommend continued monitoring.

**IMAGING PERFORMED BY**

Dr. Cassels-Conway

**HOSPITAL NAME**

Central Broward AH

**REFERRING VET**

Dr. Cassels-Conway

**INVOICE**

41089

**DATE**

9/7/22

**INTERPRETATION OF THE FINDINGS & FURTHER RECOMMENDATIONS**

The lesion visualized in the tail of the spleen is persistent and slightly larger. It was previously mixed echogenicity and now it is much more hypoechoic and has a small cavitated area. These findings may an aggressive neoplasm less likely, as you would expect more progression in this amount of time, but it still does look somewhat concerning. Consider a fine needle aspirate. Additionally, there is some debris in



**PATIENT**

Nacho Flores

the gallbladder. Correlate with liver enzyme values. If significantly elevated, consider starting Ursodiol.

The prostate has markedly improved and has reduced in size by over 50%.

The liver appears persistently heterogeneous but not focal lesions have developed.

**SPECIES**

Canine

**BREED**

Beagle

**SEX**

Neutered Male

**AGE**

9 Years

**WEIGHT**

37 Pounds

**INTERPRETED BY**

Kathleen Sennello DVM,  
MS, Diplomate ACVIM  
(Small Animal Internal  
Medicine)

**IMAGING  
PERFORMED BY**

Dr. Cassels-Conway

**HOSPITAL NAME**

Central Broward AH

**REFERRING VET**

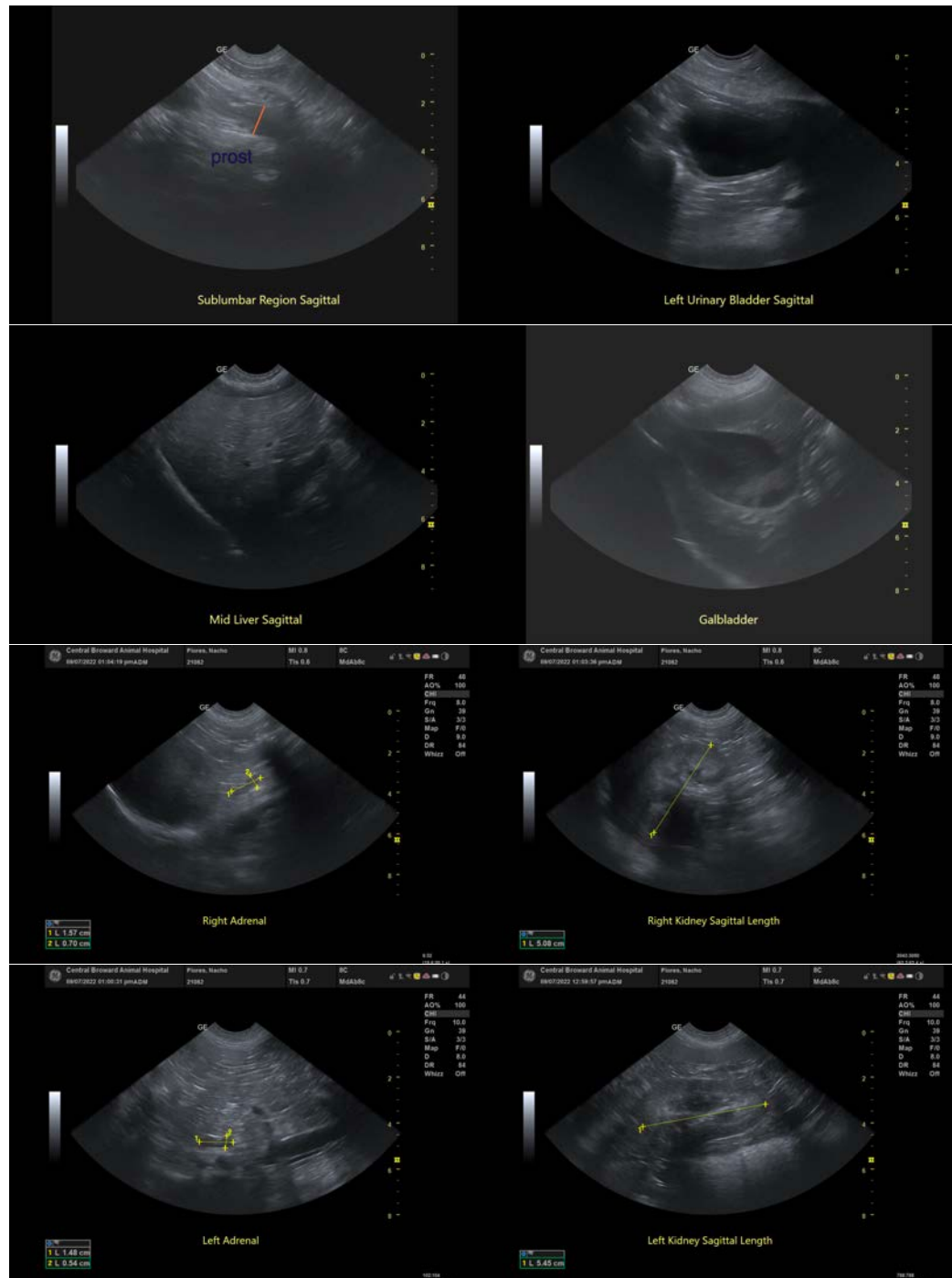
Dr. Cassels-Conway

**INVOICE**

41089

**DATE**

9/7/22





**PATIENT**

Nacho Flores

**SPECIES**

Canine

**BREED**

Beagle

**SEX**

Neutered Male

**AGE**

9 Years

**WEIGHT**

37 Pounds

**INTERPRETED BY**

Kathleen Sennello DVM,  
MS, Diplomate ACVIM  
(Small Animal Internal  
Medicine)

**IMAGING  
PERFORMED BY**

Dr. Cassels-Conway

**HOSPITAL NAME**

Central Broward AH

**REFERRING VET**

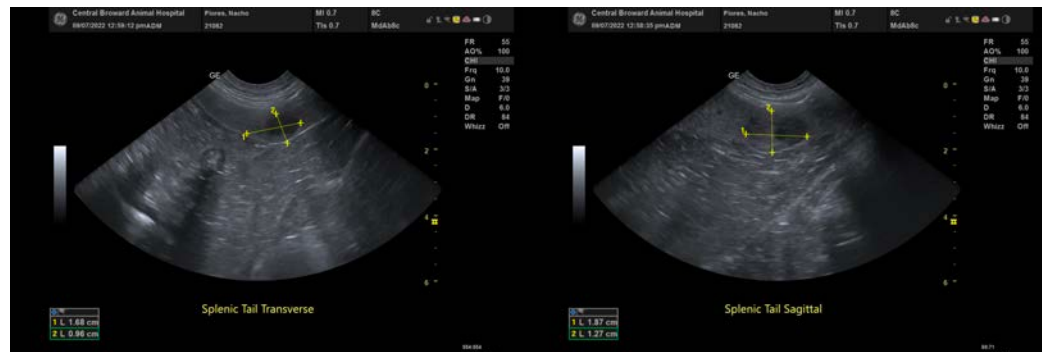
Dr. Cassels-Conway

**INVOICE**

41089

**DATE**

9/7/22



The information and recommendations provided are based on the images presented by the referring veterinarian/sonographer. No evaluation can be communicated regarding pathology that was not visible in the image/video clips provided.

Thank you for this referral. If the clinical or image interpretation does not parallel your findings or if I can be of any further assistance please contact me.

Kathleen Sennello DVM,MS, Diplomate ACVIM (Small animal Internal Medicine)

kathleen.sennello@sonopath.com