

**DATE PRESENTING CLINICAL SIGNS**

9/7/21 Acting "spaced out" and seems off for several days. Pacing/neurologic.

**PATIENT** Current Medications: Gabapentin 100mg (2 BID) started 9/2/21.

Daisy Superior Lab Results & Radiographs: RF lameness, shoulder r/o referred IVDD, muscle strain, other. Weight loss.

Suspect senility but concerned about weight loss.

Date of Previous IntraPet Ultrasound: No previous

Sedation: not needed

**SPECIES** Stat Report: not requested

Canine

**ULTRASONOGRAPHIC EXAMINATION OF THE ABDOMEN**

**BREED** *Urinary System*

Pit Bull

The urinary bladder is moderately distended with anechoic urine. The Bladder wall, trigone, ureteral papillae and visible urethra (to a depth of 2cm) appear normal with no evidence of wall thickening, mucosal irregularities, masses or cystic calculi.

**SEX**

Spayed Female

The left kidney has a normal shape and size (5.88 cm). Overall echogenicity is slightly hyperechoic with poor corticomedullary distinction and a typical 1:3 cortex:medulla ratio. There is no evidence of perinephric inflammation or effusion. There is no evidence of pyelectasia, nephroliths, infarcts or hydroureter. Renal vasculature is normal.

**AGE**

2008

**WEIGHT**

60 Pounds

The right kidney has a normal shape and size (5.82 cm). Overall echogenicity is slightly hyperechoic with poor corticomedullary distinction and a typical 1:3 cortex:medulla ratio. There is no evidence of perinephric inflammation or effusion. There is no evidence of pyelectasia, nephroliths, infarcts or hydroureter. Renal vasculature is normal.

**INTERPRETED BY**

Kathleen Sennello DVM,  
MS, Diplomate ACVIM  
(Small Animal Internal  
Medicine)

**Adrenal Glands**

The left adrenal gland is normal in size measuring 0.62 cm at the caudal pole. It is observed in its normal position cranial to the left renal artery. It is normal in appearance (uniformly hypoechoic) and shape with no evidence of a mass effect.

The right adrenal gland is normal in size measuring 0.71 cm at the caudal pole. It is observed in its normal position between the cranial aspect of the right kidney and the caudal vena cava. It is normal in appearance (uniformly hypoechoic) and shape with no evidence of a mass effect.

**HOSPITAL NAME**

Greenbrier Vet Clinic

**Spleen**

The spleen is subjectively normal in size. The spleen echotexture is heterogenous and mottled, the splenic capsule is smooth with no irregularities. The blood flow through the hilus and splenic parenchyma appears normal. No focal parenchymal abnormalities are visualized.

**REFERRING VET**

Dr. Allen

**Liver**

The liver is subjectively normal in size, and echogenicity with smooth peripheral margins. The parenchyma is mildly heterogenous in echotexture with subtle, indistinct focal mottling. The visible portions of the vasculature and biliary tract appear normal. No focal nodules or cystic lesions are observed.

**INVOICE**

25210

The gall bladder lumen is moderately distended. The wall of the gall bladder is not thickened and has a smooth mucosal surface. There is a mild amount of non-organized echogenic debris. The cystic and common bile ducts are normal/not visible.

### ***Gastrointestinal***

The stomach contains minimal luminal contents. It measures at a normal thickness of <0.7cm with some variability due to the presence of rugal folds. The distinction of the gastric wall layers is adequate and there is no impression of reduced peristaltic activity. No masses or focal lesions were observed.

The visualized areas of duodenum, jejunum and ileum have a relatively uniform diameter with minimal fluid distension. Wall thickness is normal. Bowel loops follow a curvilinear path with distinct wall layering maintaining the typical 1:3 muscularis:mucosa layer ratio. The duodenum measured as normal (between 0.3-0.5cm in wall thickness) and the jejunum measured as normal (between 0.2-0.47cm.) Visualized peristalsis appears appropriate. There were no focal lesions consistent with obstruction or a mass effect observed.

The ileocecal junction was visualized and exhibited normal intact wall layering and is subjectively of normal thickness. Sections of colon are visualized with formed fecal material and gas shadowing distally. There is no observed focal or generalized colon wall thickening or loss of layering.

### ***Pancreas***

The pancreas is normal and isoechoic to surrounding mesentery. There is no evidence of nodules or cystic lesions. There is no evidence of regional mesenteric inflammation or fluid.

### ***Free Abdomen***

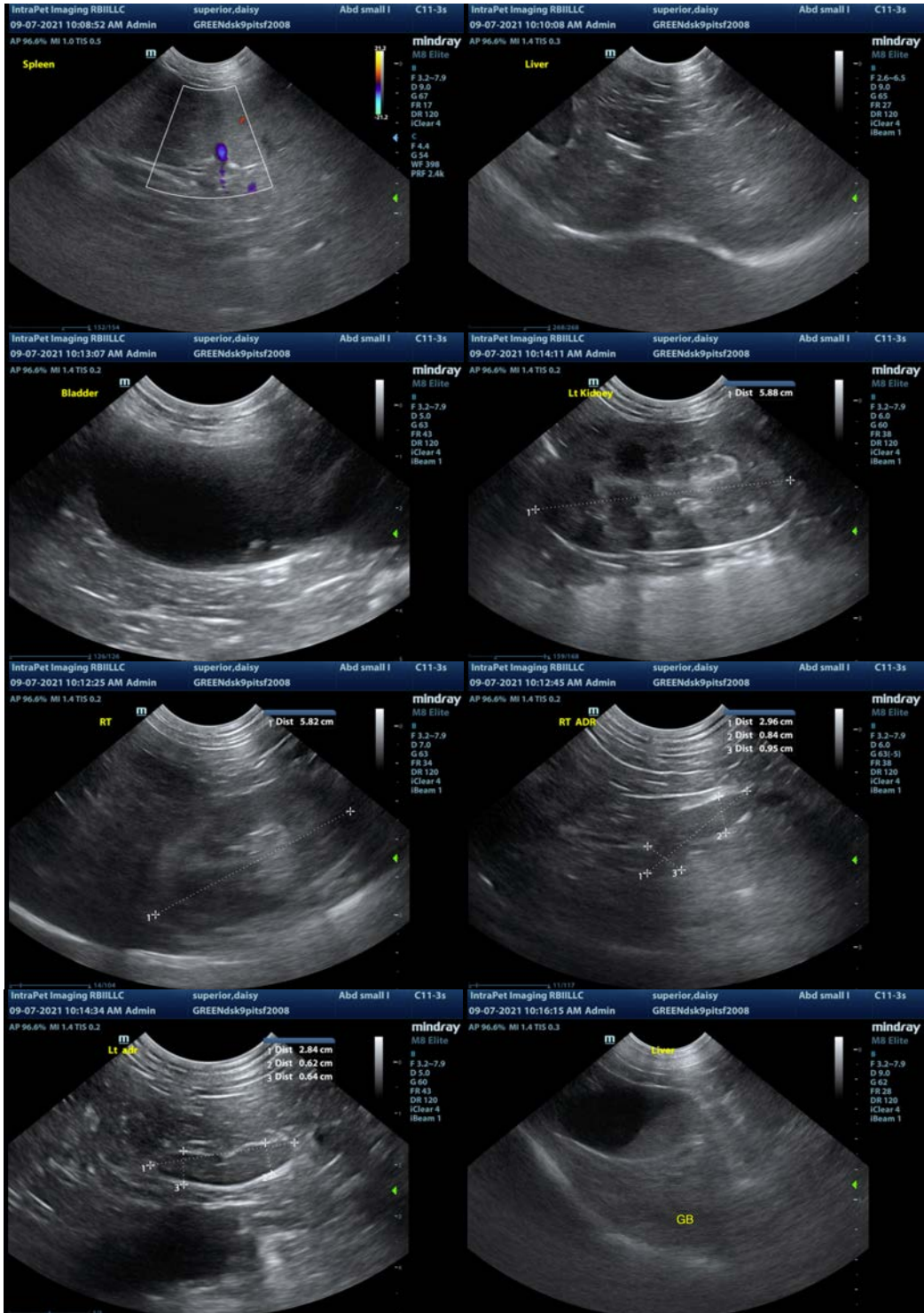
Evaluation of the peritoneal cavity did not reveal any evidence of effusion, or subjective lymphadenomegaly. The Medial iliac nodes appear normal and there was no evidence of a caudal aortic thrombus at the bifurcation. The omentum is of normal uniform echogenicity.

## **ULTRASONOGRAPHIC FINDINGS**

- Large, mottled spleen – The diffuse splenic changes are non-specific and could be consistent with lymphoid hyperplasia, extramedullary hematopoiesis, infiltrative neoplasia, inflammation, other. Cytology or histopathology would be necessary to get a definitive diagnosis. This is a subjective mild finding and could be consistent with age related changes.
- Heterogeneous liver – The hepatic changes are consistent with age-related parenchymal remodeling and are not considered clinically significant at this time.
- Mild gallbladder sludge – The significance of the aggregated gallbladder sludge is unclear. This could represent an early mucocele, cholestasis, or may be secondary to fasting.
- Decreased corticomedullary distinction in both kidneys – The bilateral renal findings are consistent with age-related change.

## **INTERPRETATION OF THE FINDINGS & FURTHER RECOMMENDATIONS**

Most of the abnormalities visualized on today's exam are mild and likely age related. I do not see an obvious cause for the reported neurologic signs. Consider a liver function test and ammonia level if liver disease is suspected. Otherwise, recommend referral to a veterinarian neurologist for evaluation for possible intracranial disease (?).



**The information and recommendations provided are based on the images presented by the referring veterinarian. No evaluation can be communicated regarding pathology that was not visible in the image/video clips provided.**

Thank you for this referral. If the clinical or image interpretation does not parallel your findings or if I can be of any further assistance please contact me.

Kathleen Sennello DVM,MS, Diplomate ACVIM (Small animal Internal Medicine)  
kathleen.sennello@sonopath.com