

PATIENT

Meela Knowles

PRESENTING CLINICAL SIGNS

Fractious- needed sedation dexdormitor/torb/ketamine. Owner requests abdominal ultrasound, owner thinks issues may be related to her liver, pancreas or gallbladder- possibly something in her lower intestine. Per owner's emails on the records: periods of lethargy, coughing, open mouth breathing, constipation, inappetance, nausea, Currently on prednisone and appetite stimulants. BP in-house = 150/110; WNL for in-hospital
Abnormal PE/Chem/CBC/UA Results: FELV/FIV negative- SPO2 97%- BUN/CREA/SDMA are always in normal range and her USG fluctuates between low and well concentrated. Recent USG was 1.050. Neutropenia.

SPECIES

Feline

BREED

DSH

ULTRASONOGRAPHIC EXAMINATION OF THE ABDOMEN

SEX

Urinary System

Spayed Female

The urinary bladder is moderately distended with anechoic urine. The Bladder wall, trigone, ureteral papillae and visible urethra (to a depth of 2cm) appear normal with no evidence of wall thickening, mucosal irregularities, masses or cystic calculi.

AGE

10 Years

The left kidney has a normal shape and size (4.01 cm). Overall echogenicity is normal with adequate corticomedullary distinction and a typical 1:3 cortex:medulla ratio. There is no evidence of perinephric inflammation or effusion. There is no evidence of pyelectasia, nephroliths, infarcts or hydroureter. Renal vasculature is normal.

WEIGHT

14 Pounds

The right kidney has a normal shape and size (3.2 cm). Overall echogenicity is normal with adequate corticomedullary distinction and a typical 1:3 cortex:medulla ratio. There is no evidence of perinephric inflammation or effusion. There is no evidence of pyelectasia, nephroliths, infarcts or hydroureter. Renal vasculature is normal.

INTERPRETED BY

Kathleen Sennello DVM,
MS, Diplomate ACVIM
(Small Animal Internal
Medicine)

Adrenal Glands

The left adrenal gland is normal in size measuring 0.36 cm at the caudal pole. It is observed in its normal position cranial to the left renal artery. It is normal in appearance (uniformly hypoechoic) and shape with no evidence of a mass effect.

IMAGING PERFORMED BY

Loetitia Saint-Jacques, RVT

The right adrenal gland is normal in size measuring 0.34 cm at the caudal pole. It is observed in its normal position between the cranial aspect of the right kidney and the caudal vena cava. It is normal in appearance (uniformly hypoechoic) and shape with no evidence of a mass effect.

HOSPITAL NAME

Options Vet Care

Spleen

The spleen is subjectively normal/borderline large in size, measuring 1.11 cm (normal is <1.0 cm), echotexture is homogenous, and the splenic capsule is smooth with no irregularities. The blood flow through the hilus and splenic parenchyma appears normal. No focal parenchymal abnormalities are visualized.

REFERRING VET

Dr. Jeffrey Pearson

Liver

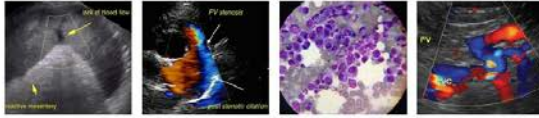
INVOICE

25988

The liver is large in size with smooth peripheral margins. The parenchyma is hyperechoic and homogenous in echotexture. The visible portions of the vasculature and biliary tract appear normal. No focal nodules or cystic lesions are observed.

DATE

9/30/21



PATIENT

Meela Knowles The gallbladder lumen is moderately distended. The wall of the gall bladder is not thickened and has a smooth mucosal surface. Luminal contents are primarily anechoic. The cystic and common bile ducts are normal/not visible.

SPECIES

Gastrointestinal

Feline

The stomach contains minimal luminal contents. It measures at a normal thickness of <0.36cm with some variability due to the presence of rugal folds. The distinction of the gastric wall layers is adequate and there is no impression of reduced peristaltic activity. No masses or focal lesions were observed.

BREED

DSH

The visualized areas of duodenum, jejunum and ileum have a relatively uniform diameter with minimal fluid distension. Wall thickness is normal. Bowel loops follow a curvilinear path with distinct wall layering maintaining the typical 1:3 muscularis:mucosa layer ratio. Jejunum wall measured 0.19 cm.

SEX

Spayed Female

Visualized peristalsis appears appropriate. There were no focal lesions consistent with obstruction or a mass effect observed.

AGE

10 Years

The ileocecal junction was visualized and exhibited normal intact wall layering and is subjectively of normal thickness. Sections of colon are visualized with formed fecal material and gas shadowing distally. There is no observed focal or generalized colon wall thickening or loss of layering.

Pancreas

WEIGHT

14 Pounds

The pancreas is prominent and hypoechoic as compared to the surrounding isoechoic mesentery. There is no evidence of nodules or cystic lesions. There is no evidence of regional mesenteric inflammation or fluid.

Free Abdomen

INTERPRETED BY

Kathleen Sennello DVM,
MS, Diplomate ACVIM
(Small Animal Internal
Medicine)

Evaluation of the peritoneal cavity did not reveal any evidence of effusion. Mildly prominent cluster of lymph nodes noted around the ileocecal junction measuring 0.39, 0.35, 0.29 cm. The omentum is of normal uniform echogenicity.

PRIARY FINDINGS

- Large, hyperechoic liver – Hepatic changes are non-specific and could be consistent with hepatic lipidosis, inflammatory/infectious disease, infiltrative neoplasia, or other hepatopathy.
- Prominent, hypoechoic pancreas – The pancreatic changes are most consistent with mild pancreatitis or a recent episode of pancreatic inflammation.

IMAGING PERFORMED BY

Loetitia Saint-Jacques, RVT

HOSPITAL NAME

Options Vet Care

SECONDARY FINDINGS

- Borderline enlarged spleen – This can be seen with inflammation or infiltrative disease, but this can also be normal for some bigger cats. Cytology or histopathology would be necessary to know definitively.
- Cluster of prominent mesenteric lymph nodes around the ileocecal junction – The prominent abdominal lymph nodes are most consistent with reactive lymphadenitis or lymphoid hyperplasia. Neoplastic infiltration is considered less likely.

REFERRING VET

Dr. Jeffrey Pearson

INVOICE

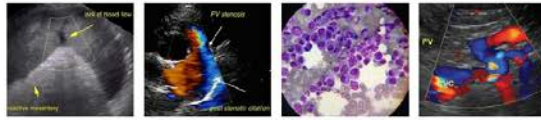
25988

INTERPRETATION OF THE FINDINGS & FURTHER RECOMMENDATIONS

DATE

9/30/21

The liver is hyperechoic and large in size. This is a non-specific finding that could be associated with fat deposition if anorexia is significant (lipidosis), inflammation, infiltrative disease such as round cell neoplasia, normal fat deposition in overweight cats, etc. If liver values are normal, then options are to



PATIENT

Meela Knowles consider liver function test +/- fine needle aspirate of the liver.

SPECIES

Feline The pancreas is somewhat prominent. Consider GI panel with a quantitative fPLI, TLI, cobalamin and folate to further evaluate for pancreatic and small intestinal disease.

BREED

DSH Additionally, there is a small cluster of prominent lymph nodes around the ileocecal junction. These are not enlarged, but could be associated with inflammation, which can be seen with some types of small intestinal disease. It is possible that the Prednisone is suppressing some of these lesions. It is not uncommon for a pet with gastrointestinal disease to have relatively mild or no lesions on ultrasound. If metabolic diseases are ruled out, then consider primary GI causes such as GI parasitism, mild pancreatitis, bacterial dysbiosis, food allergy, IBD, and less likely intestinal neoplasia.

SEX

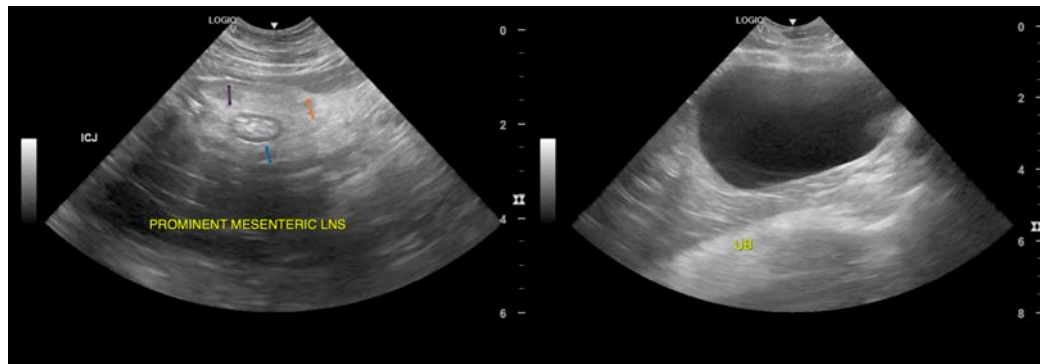
Spayed Female You could consider evaluation for food allergy, IBD/intestinal neoplasia by trying a diet trial with a novel protein/hydrolyzed prescription diet, starting a probiotic, and if symptoms progress, consider obtaining GI biopsies.

AGE

10 Years

WEIGHT

14 Pounds



INTERPRETED BY

Kathleen Sennello DVM,
MS, Diplomate ACVIM
(Small Animal Internal
Medicine)

IMAGING PERFORMED BY

Loetitia Saint-Jacques, RVT

HOSPITAL NAME

Options Vet Care

REFERRING VET

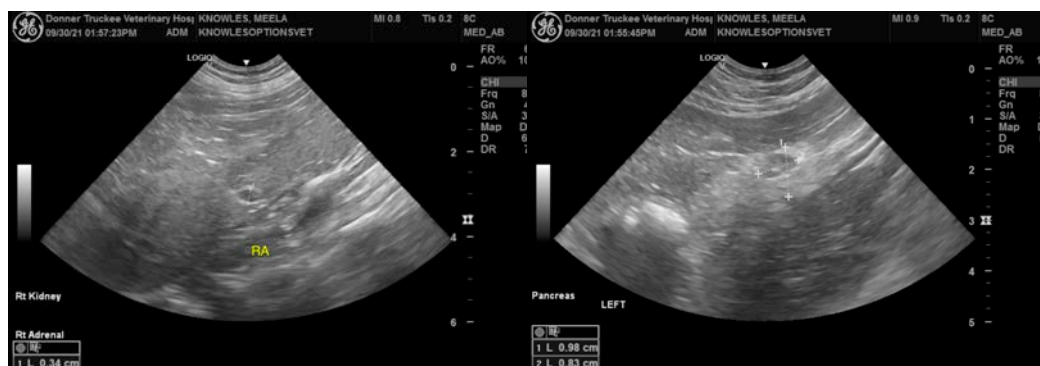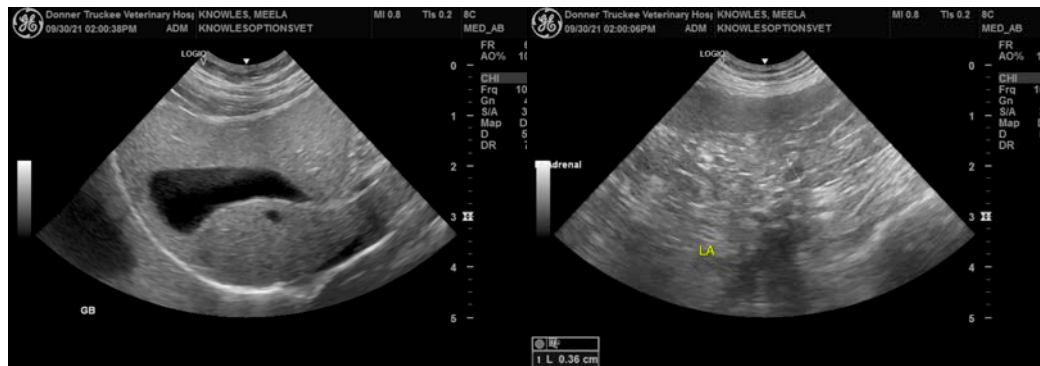
Dr. Jeffrey Pearson

INVOICE

25988

DATE

9/30/21





PATIENT

Meela Knowles

SPECIES

Feline

BREED

DSH

SEX

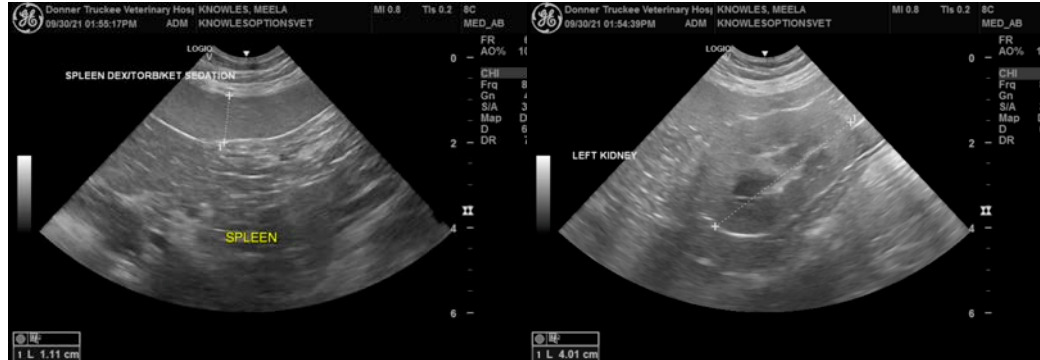
Spayed Female

AGE

10 Years

WEIGHT

14 Pounds



The information and recommendations provided are based on the images presented by the referring veterinarian. No evaluation can be communicated regarding pathology that was not visible in the image/video clips provided.

Thank you for this referral. If the clinical or image interpretation does not parallel your findings or if I can be of any further assistance please contact me.

Kathleen Sennello DVM,MS, Diplomate ACVIM (Small animal Internal Medicine)

kathleen.sennello@sonopath.com

INTERPRETED BY

Kathleen Sennello DVM,
MS, Diplomate ACVIM
(Small Animal Internal
Medicine)

IMAGING PERFORMED BY

Loetitia Saint-Jacques, RVT

HOSPITAL NAME

Options Vet Care

REFERRING VET

Dr. Jeffrey Pearson

INVOICE

25988

DATE

9/30/21