



**PATIENT**

Buddy Sullivan

**PRESENTING CLINICAL SIGNS**

PU/PD that resolves on antibiotics decreased app today no v/d  
Abnormal PE/Chem/CBC/UA Results: chem WNL UA USG 1.010

**SPECIES**

Canine

**ULTRASONOGRAPHIC EXAMINATION OF THE ABDOMEN**

**Urinary System**

**BREED**

Beagle

The urinary bladder is moderately distended with anechoic urine. The Bladder wall, trigone, ureteral papillae and visible urethra (to a depth of 2cm) appear normal with no evidence of wall thickening, mucosal irregularities, masses or cystic calculi.

**SEX**

Neutered Male

The prostate is normal in size (0.92 cm) and shape for this neutered male dog. The parenchyma is homogenous and the external margins are smooth. The prostatic urethra appears normal with no evidence of irregularity, invasion, mass effect or calculi.

**AGE**

12 Years

The left kidney has a normal shape and size (4.9 cm). Overall echogenicity is normal with adequate corticomedullary distinction and a typical 1:3 cortex:medulla ratio. There is no evidence of perinephric inflammation or effusion. There is no evidence of pyelectasia, nephroliths, infarcts or hydroureter. Renal vasculature is normal.

**WEIGHT**

27 Pounds

The right kidney has a normal shape and size (5.1 cm). Overall echogenicity is normal with adequate corticomedullary distinction and a typical 1:3 cortex:medulla ratio. There is no evidence of perinephric inflammation or effusion. There is no evidence of pyelectasia, nephroliths, infarcts or hydroureter. Renal vasculature is normal.

**Adrenal Glands**

**INTERPRETED BY**

Kathleen Sennello DVM,  
MS, Diplomate ACVIM  
(Small Animal Internal  
Medicine)

The left adrenal gland is normal in size measuring 0.74 cm at the caudal pole. It is observed in its normal position cranial to the left renal artery. It is normal in appearance (uniformly hypoechoic) and shape with no evidence of a mass effect.

**IMAGING PERFORMED BY**

Dr. Scott

The right adrenal gland is normal in size measuring 0.64 cm at the caudal pole. It is observed in its normal position between the cranial aspect of the right kidney and the caudal vena cava. It is normal in appearance (uniformly hypoechoic) and shape with no evidence of a mass effect.

**Spleen**

**HOSPITAL NAME**

Ho-Ho-Kus VH

The spleen is subjectively normal in size, echotexture is homogenous, and the splenic capsule is smooth with no irregularities. The blood flow through the hilus and splenic parenchyma appears normal. No focal parenchymal abnormalities are visualized.

**Liver**

**REFERRING VET**

Dr. Wagner

The liver is large in size, and hypoechoic with smooth peripheral margins. The parenchyma is heterogenous in echotexture with subtle, indistinct focal mottling. The visible portions of the vasculature and biliary tract appear normal. There are too numerous to count ill-defined, hypoechoic nodules visualized within the hepatic parenchyma, varying in size from 0.3-1.1 cm.

**INVOICE**

25975

The gall bladder lumen is moderately distended. The wall of the gall bladder is not thickened and has a smooth mucosal surface. There is a moderate amount of non-organized echogenic debris. The cystic and common bile ducts are normal/not visible.

**DATE**

9/30/21



**PATIENT**

Buddy Sullivan

***Gastrointestinal***

The stomach contains minimal luminal contents. It measures at a normal thickness of <0.7cm with some variability due to the presence of rugal folds. The distinction of the gastric wall layers is adequate and there is no impression of reduced peristaltic activity. No masses or focal lesions were observed.

**SPECIES**

Canine

The visualized areas of duodenum, jejunum and ileum have a relatively uniform diameter with minimal fluid distension. Wall thickness is normal. Bowel loops follow a curvilinear path with distinct wall layering maintaining the typical 1:3 muscularis:mucosa layer ratio. Jejunum wall measured 0.37 cm.

**BREED**

Beagle

Visualized peristalsis appears appropriate. There were no focal lesions consistent with obstruction or a mass effect observed.

**SEX**

Neutered Male

The ileocecal junction was visualized and exhibited normal intact wall layering and is subjectively of normal thickness. Sections of colon are visualized with formed fecal material and gas shadowing distally. There is no observed focal or generalized colon wall thickening or loss of layering.

***Pancreas***

The pancreas is normal and isoechoic to surrounding mesentery. There is no evidence of nodules or cystic lesions. There is no evidence of regional mesenteric inflammation or fluid.

**AGE**

12 Years

***Free Abdomen***

Evaluation of the peritoneal cavity did not reveal any evidence of effusion, or subjective lymphadenomegaly. The Medial iliac nodes appear normal and there was no evidence of a caudal aortic thrombus at the bifurcation. The omentum is of normal uniform echogenicity.

**WEIGHT**

27 Pounds

**PRIMARY FINDINGS**

- Large, heterogeneous liver with ill-defined, hypoechoic nodules – The diffuse hepatic changes are non-specific and could be consistent with vacuolar hepatopathy, nodular hyperplasia, inflammatory/immune-mediated disease, fibrosis, extramedullary hematopoiesis, toxic hepatopathy (e.g., copper), infiltrative neoplasia (less likely) or other hepatopathy.

**INTERPRETED BY**

Kathleen Sennello DVM,  
MS, Diplomate ACVIM  
(Small Animal Internal  
Medicine)

**SECONDARY FINDINGS**

- Moderate gallbladder sludge – The significance of the aggregated gallbladder sludge is unclear. This could represent an early mucocele, cholestasis, or may be secondary to fasting.

**IMAGING PERFORMED BY**

Dr. Scott

**INTERPRETATION OF THE FINDINGS & FURTHER RECOMMENDATIONS**

**HOSPITAL NAME**

Ho-Ho-Kus VH

The most significant abnormality observed on today's scan is the irregular, heterogeneous liver. This is a non-specific finding that is difficult to interpret without any history of liver enzyme elevations. Consider a liver function test +/- fine needle aspirate of the liver, as sometimes you can have abnormal liver function despite normal liver values. Recommend urinalysis and culture. If other symptoms of Cushing's are present, you could consider adrenal function testing, although this would be a very atypical case.

**REFERRING VET**

Dr. Wagner

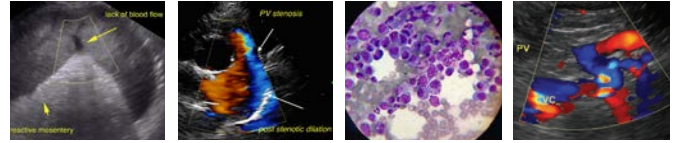
In these situations, I always have the owner quantitate water intake at home, check numerous specific gravities at home, evaluate for diet changes, new treats, anything that is different in the environment that could change behavior, and then work my way through an extensive list of differentials once these things are proven unlikely. Recommend 3-view thoracic radiographs to rule out intrathoracic disease.

**INVOICE**

25975

**DATE**

9/30/21



**PATIENT**

Buddy Sullivan

**SPECIES**

Canine

**BREED**

Beagle

**SEX**

Neutered Male

**AGE**

12 Years

**WEIGHT**

27 Pounds

**INTERPRETED BY**

Kathleen Sennello DVM,  
MS, Diplomate ACVIM  
(Small Animal Internal  
Medicine)

**IMAGING  
PERFORMED BY**

Dr. Scott

**HOSPITAL NAME**

Ho-Ho-Kus VH

**REFERRING VET**

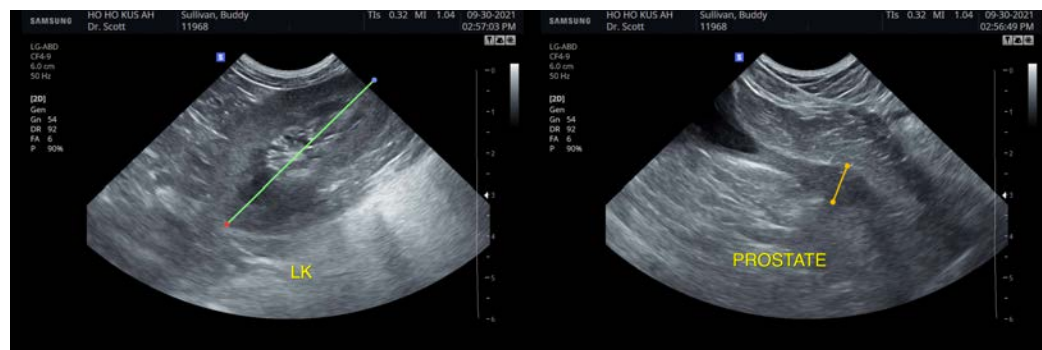
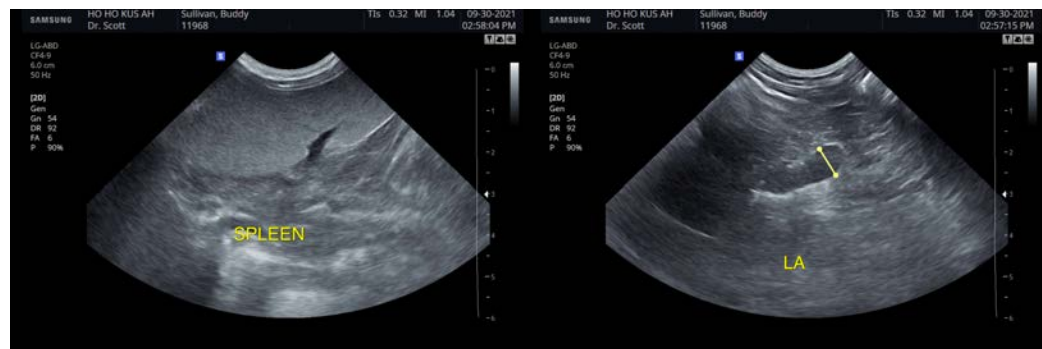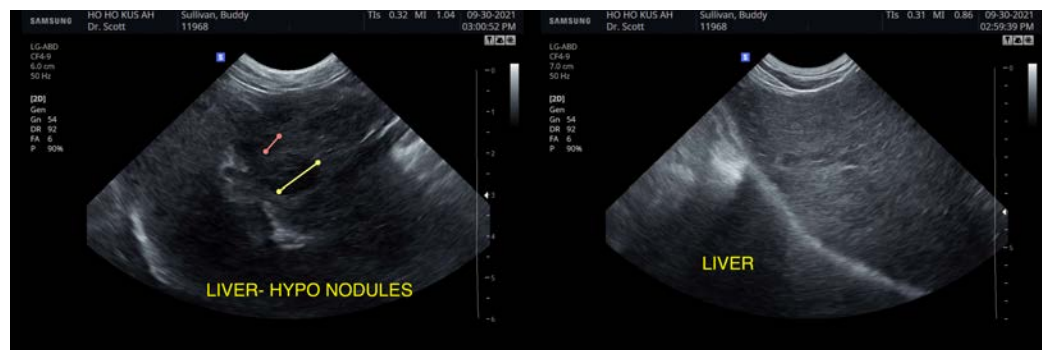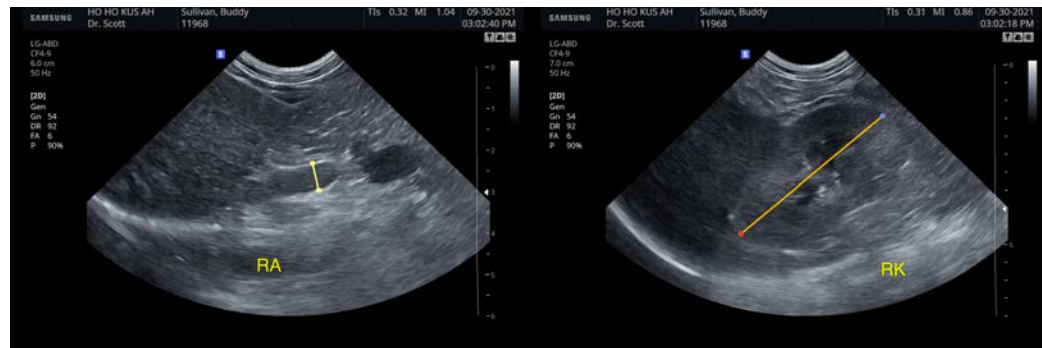
Dr. Wagner

**INVOICE**

25975

**DATE**

9/30/21





**PATIENT**

Buddy Sullivan

**SPECIES**

Canine

**BREED**

Beagle

**SEX**

Neutered Male

**AGE**

12 Years

**WEIGHT**

27 Pounds

**INTERPRETED BY**

Kathleen Sennello DVM,  
MS, Diplomate ACVIM  
(Small Animal Internal  
Medicine)

**IMAGING  
PERFORMED BY**

Dr. Scott

**HOSPITAL NAME**

Ho-Ho-Kus VH

**REFERRING VET**

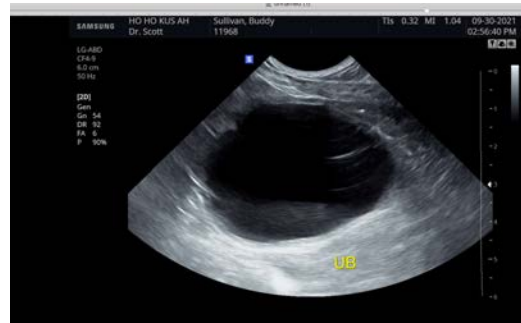Dr. Wagner

**INVOICE**

25975

**DATE**

9/30/21



The information and recommendations provided are based on the images presented by the referring veterinarian. No evaluation can be communicated regarding pathology that was not visible in the image/video clips provided.

Thank you for this referral. If the clinical or image interpretation does not parallel your findings or if I can be of any further assistance please contact me.

Kathleen Sennello DVM,MS, Diplomate ACVIM (Small animal Internal Medicine)  
kathleen.sennello@sonopath.com