

**DATE PRESENTING CLINICAL SIGNS**

9/29/22

Persistently elevated ALT and AlkP, non-responsive to medical management, otherwise asymptomatic. P obese and mild to moderate dental dz, remainder of PE unremarkable.

PATIENT

Olivia Gardocki

Current Medications: Denamarin started April 2022, o gave 1 month, restarted in July. Dasuquin (last 5 months). Rimadyl 75mg 1/2 tablet as needed, up to BID - started in April, given intermittently since.

Lab Results: ALT 278, AlkP 272 (8/19/22). ALT 277, AlkP 180 (7/19/22)

ALT 209, AlkP 140 (2/14/22)

SPECIES

Canine

Date of Previous IntraPet Ultrasound: No previous.

Sedation: Not required to complete full diagnostic ultrasound.

Stat Report: Not requested.

BREED

Terrier

ULTRASONOGRAPHIC EXAMINATION OF THE ABDOMEN**SEX**

Spayed Female

Urinary System

The urinary bladder is moderately distended with anechoic urine. The Bladder wall, trigone, ureteral papillae and visible urethra (to a depth of 2cm) appear normal with no evidence of wall thickening, mucosal irregularities, masses or cystic calculi.

AGE

9/12/13

The left kidney has a normal shape and size. Overall echogenicity is normal with adequate corticomedullary distinction and a typical 1:3 cortex:medulla ratio. There is no evidence of focal perinephric inflammation or effusion. There is no evidence of pyelectasia, nephroliths, infarcts or hydroureter. Renal vasculature is normal.

WEIGHT

41.6 Pounds

The right kidney has a normal shape and size (6.49 cm). Overall echogenicity is normal with adequate corticomedullary distinction and a typical 1:3 cortex:medulla ratio. There is no evidence of focal perinephric inflammation or effusion. There is no evidence of pyelectasia, nephroliths, infarcts or hydroureter. Renal vasculature is normal.

INTERPRETED BY

Kathleen Sennello DVM,
MS, Diplomate ACVIM
(Small Animal Internal
Medicine)

Adrenal Glands

The left adrenal gland is large in size measuring 1.16 cm at the cranial pole, 0.75 cm at the caudal pole, and 2.43 cm in length. It is observed in its normal position cranial to the left renal artery. It is abnormal in appearance in that there is a hyperechoic nodule in the cranial pole measuring 1.19 cm x 1.17 cm.

IMAGING PERFORMED BY

Stephanie Warga
RDCS, RVT

The right adrenal gland is normal in size measuring 0.40 cm at the caudal pole. It is observed in its normal position between the cranial aspect of the right kidney and the caudal vena cava. It is normal in appearance (uniformly hypoechoic) and shape with no evidence of a mass effect.

HOSPITAL NAME

Banfield Columbia

Spleen

The spleen is subjectively normal in size, echotexture is homogenous, and the splenic capsule is smooth with no irregularities. The blood flow through the hilus and splenic parenchyma appears normal. No focal parenchymal abnormalities are visualized.

REFERRING VET

Dr. Scherping

Liver

The liver is subjectively normal in size, and echogenicity with smooth peripheral margins. The parenchyma is heterogenous in echotexture with subtle, indistinct focal mottling. The visible portions of the vasculature and biliary tract appear normal. No focal nodules or cystic lesions are observed.

INVOICE

41753

The gall bladder lumen is moderately distended. The wall of the gall bladder is not thickened and has a smooth mucosal surface. There is a mild amount of non-organized echogenic debris. The cystic and common bile ducts are normal/not visible.

Gastrointestinal

The stomach is moderately dilated with fluid and irregular shadowing material most consistent with normal ingesta and gas. It measures at a normal thickness of <0.7cm with some variability due to the presence of rugal folds. The distinction of the gastric wall layering is adequate and there is no impression of reduced peristaltic activity. No masses or focal lesions were observed.

The visualized areas of duodenum, jejunum and ileum have a relatively uniform diameter with minimal fluid distension. Wall thickness is normal. Bowel loops follow a curvilinear path with distinct wall layering maintaining the typical 1:3 muscularis:mucosa layer ratio. Jejunum wall measures 0.36 cm. Visualized peristalsis appears appropriate. There were no focal lesions consistent with obstruction or a mass effect observed.

The ileocecal junction was visualized and exhibited normal intact wall layering and is subjectively of normal thickness. Sections of colon are visualized with formed fecal material and gas shadowing distally. There is no observed focal or generalized colon wall thickening or loss of layering.

Pancreas

The pancreas is normal and isoechoic to surrounding mesentery. There is no evidence of nodules or cystic lesions. There is no evidence of regional mesenteric inflammation or fluid.

Free Abdomen

Evaluation of the peritoneal cavity did not reveal any evidence of effusion, or subjective lymphadenomegaly. The Medial iliac nodes appear normal and there was no evidence of a caudal aortic thrombus at the bifurcation. The omentum is of normal uniform echogenicity.

ULTRASONOGRAPHIC FINDINGS

- Hyperechoic nodule in the cranial pole of the left adrenal gland – Left adrenomegaly could be consistent with neoplasia (e.g., adenoma, carcinoma, pheochromocytoma), hyperplasia, inflammation, other.
- Heterogeneous liver - The liver is subjectively normal in size, and echogenicity with smooth peripheral margins. The parenchyma is heterogenous in echotexture with subtle, indistinct focal mottling. The visible portions of the vasculature and biliary tract appear normal. No focal nodules or cystic lesions are observed.
- Mild gallbladder debris – The significance of the aggregated gallbladder debris is unclear. This could represent an early mucocele, cholestasis, or may be secondary to fasting but seems unlikely to be causing a current issue. Recommend continued monitoring.
- Moderate ingesta within the gastric lumen – Correlate with feeding history. If the patient was adequately fasted, consider the possibility of delayed gastric emptying or partial outflow tract obstruction (none observed).

INTERPRETATION OF THE FINDINGS & FURTHER RECOMMENDATIONS

There is a hyperechoic nodule visualized associated with the left adrenal gland. There is no obvious vascular invasion observed. These lesions can be benign or neoplastic and can secrete hormones or be non-active. Consider the following recommendations:

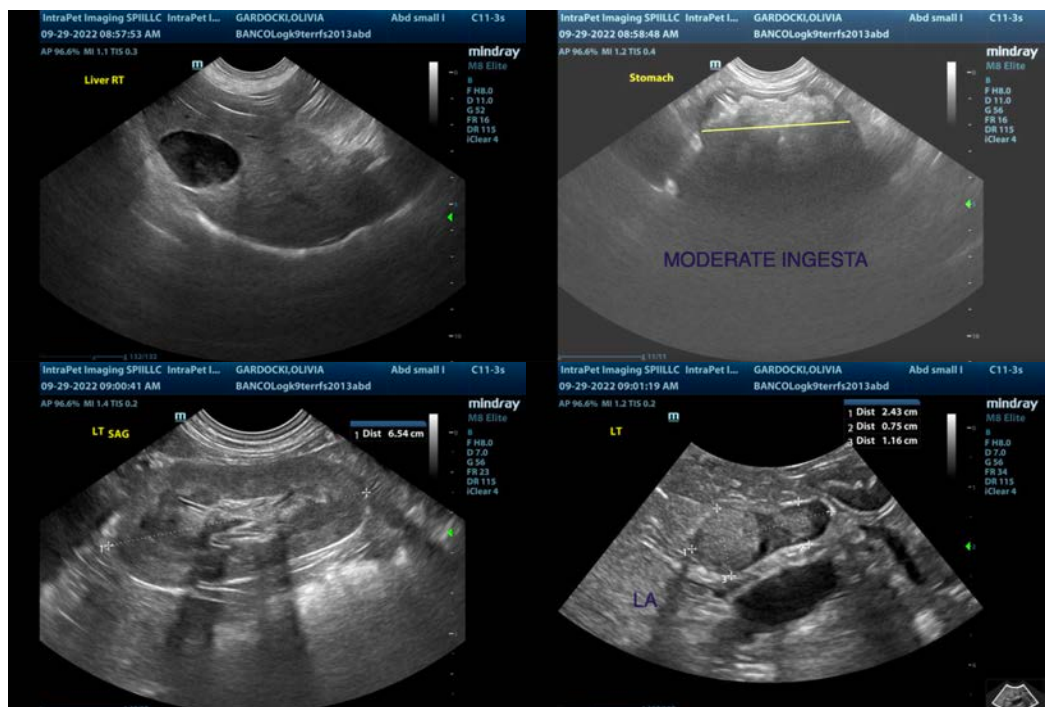
- If signs of Cushing's are present, consider adrenal function testing. I prefer an ACTH stimulation test combined with an adrenal panel to the University of Tennessee's endocrine lab to look for atypical adrenal hormones as well as cortisol. (other testing can suffice)

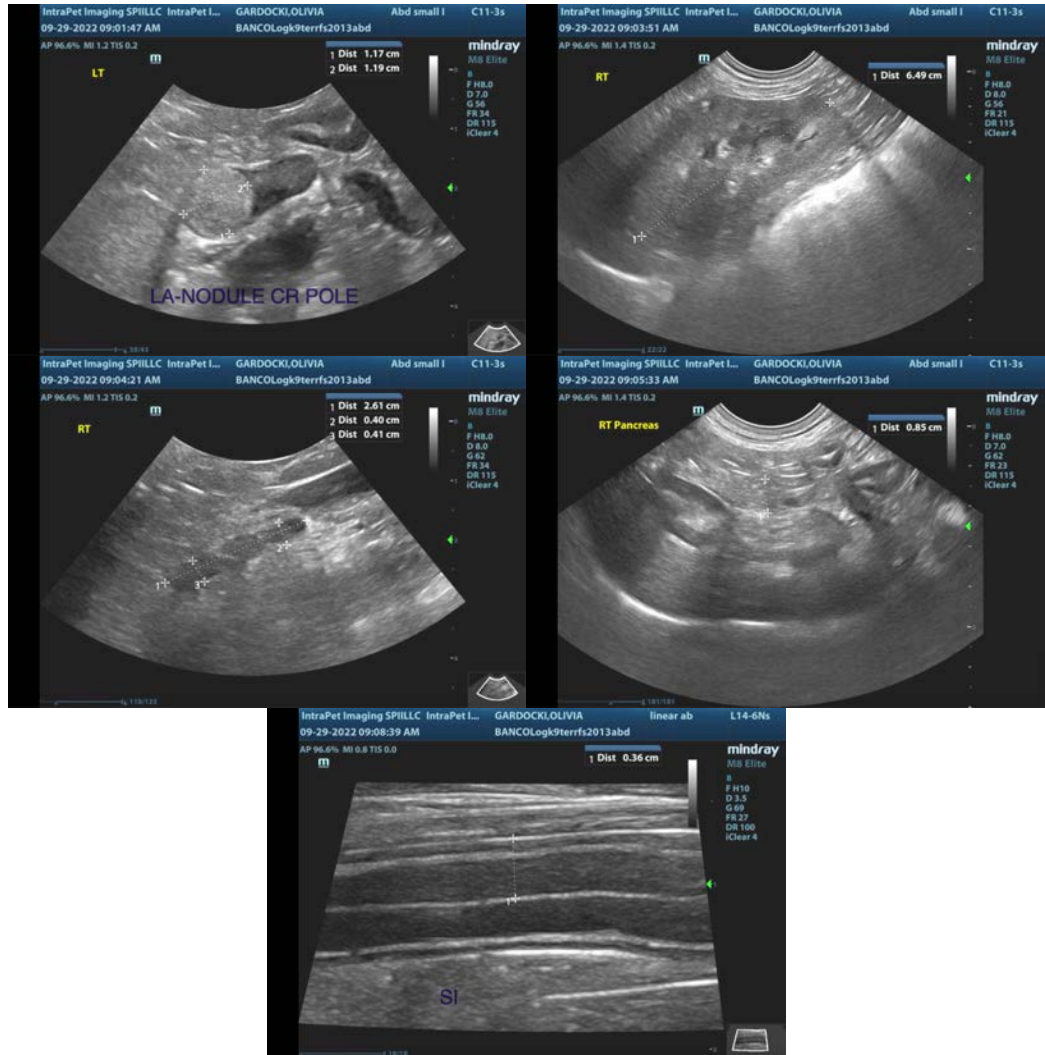
- If adrenal dependent cushings is suspected and supported by adrenal function testing consider medical therapy with lysodren or trilostane and/or consider surgical removal (recommend referral to a board certified veterinary surgeon and possible pre op CT)-This can be a challenging surgery with significant risk for complication
- Recommend blood pressure evaluation-if hypertensive consider testing catecholamine levels for a possible pheochromocytoma
- Due to the invasive nature of these masses a CT scan is recommended to evaluate for metastasis and vascular invasion.
- If no symptoms of cushings are present, consider either referral for surgery or if surgery is not an option consultation with a veterinary oncologist regarding chemotherapeutic options and continued monitoring with ultrasound (in 4-6 weeks) can be considered.
- Some aggressive adrenal tumors can grow quickly and there is risk for acute hemorrhage from vascular invasion.

Recommend three view thoracic radiographs to evaluate for possible concurrent thoracic disease/involvement.

The adrenal nodule visualized appears fairly well encapsulated and would likely be a good candidate for surgical removal.

No focal lesions are visualized associated with the liver. Findings could be consistent with a vacuolar hepatopathy. Recommend a liver function test and a possible fine needle aspirate of the liver +/- testing for Leptospirosis if appropriate.





The information and recommendations provided are based on the images presented by the referring veterinarian/sonographer. No evaluation can be communicated regarding pathology that was not visible in the image/video clips provided.

Thank you for this referral. If the clinical or image interpretation does not parallel your findings or if I can be of any further assistance please contact me.

Kathleen Sennello DVM,MS, Diplomate ACVIM (Small animal Internal Medicine)
 kathleen.sennello@sonopath.com