

IMAGING PERFORMED BY

IntraPet.com



**SonoPath**

Clinical Sonography & Telectology

EDUCATIONAL TELECONSULTATION SERVICES™

1-800-838-4268 info@sonopath.com SonoPath.com

**DATE PRESENTING CLINICAL SIGNS**

9/29/22 Had previous U/S on 8/2, need recheck to evaluate increased panting and increased urination. Has hx of adrenalectomy done 4/22.

**PATIENT**

Lucy Debolt  
Current Medications: Hydroxyzine 25mg BID, Wellactin.  
Date of Previous IntraPet Ultrasound: 8/2/22. See attached.  
Sedation: Not required to complete full diagnostic ultrasound.  
Stat Report: Not requested.

**SPECIES**

Canine

**BREED**

Multi-Poo

**SEX**

Spayed Female

**AGE**

11/17/11

**WEIGHT**

35.6 Pounds

**INTERPRETED BY**

Kathleen Sennello DVM,  
MS, Diplomate ACVIM  
(Small Animal Internal  
Medicine)

**IMAGING PERFORMED BY**

Stephanie Warga  
RDMS, RVT

**HOSPITAL NAME**

White Marsh AH

**REFERRING VET**

Dr. Danna

**INVOICE**

41756

**ULTRASONOGRAPHIC EXAMINATION OF THE ABDOMEN**

**Urinary System**

The urinary bladder is moderately distended with anechoic urine. The Bladder wall, trigone, ureteral papillae and visible urethra (to a depth of 2cm) appear normal with no evidence of wall thickening, mucosal irregularities, masses or cystic calculi. Cystocentesis was performed during the ultrasound evaluation.

The left kidney has a normal shape and size (5.6 cm) with small non-obstructive nephroliths. Overall echogenicity is normal with adequate corticomedullary distinction and a typical 1:3 cortex:medulla ratio. There is no evidence of focal perinephric inflammation or effusion. There is no evidence of pyelectasia, infarcts or hydronephrosis. Renal vasculature is normal.

The right kidney has a normal shape and size (5.82 cm) with small non-obstructive nephroliths. Overall echogenicity is normal with adequate corticomedullary distinction and a typical 1:3 cortex:medulla ratio. There is no evidence of focal perinephric inflammation or effusion. There is no evidence of pyelectasia, infarcts or hydronephrosis. Renal vasculature is normal.

**Adrenal Glands**

The left adrenal gland is surgically absent. Adrenalectomy for an adenocarcinoma 4/22.

The right adrenal gland is normal/borderline large measuring 0.91 cm at the cranial pole, 0.72 cm at the caudal pole, and 2.88 cm in length. It is observed in its normal position between the cranial aspect of the right kidney and the caudal vena cava. It is abnormal in appearance in that there is a hyperechoic nodule on the cranial pole measuring 0.79 cm x 0.79 cm (previous measurement 0.72 cm x 0.68 cm).

**Spleen**

The spleen is subjectively normal in size and the echotexture is homogenous. The splenic capsule is smooth with no visible irregularities. Rare discrete focal hyperechoic, perivascular parenchymal abnormalities are present. The appearance of these lesions is most consistent with benign splenic myelolipomas. The blood flow through the hilus and splenic parenchyma appears normal.

**Liver**

The liver is large in size, and normal in echogenicity with smooth peripheral margins. The parenchyma is heterogenous in echotexture with subtle, indistinct focal mottling. The visible portions of the vasculature and biliary tract appear normal. No focal nodules or cystic lesions are observed.

The gall bladder lumen is significantly distended. Some areas of the wall appear mildly thickened with adherent debris. There is a large amount of primarily non-organized echogenic debris. There is no evidence of bile duct dilation.

### ***Gastrointestinal***

The stomach contains minimal luminal contents. It measures at a normal thickness of <0.7cm with some variability due to the presence of rugal folds. The distinction of the gastric wall layers is adequate and there is no impression of reduced peristaltic activity. No masses or focal lesions were observed.

The visualized areas of duodenum, jejunum and ileum have a relatively uniform diameter with minimal fluid distension. Wall thickness is normal. Bowel loops follow a curvilinear path with distinct wall layering maintaining the typical 1:3 muscularis:mucosa layer ratio. The duodenum measured as normal (between 0.3-0.5cm in wall thickness) and the jejunum measured as normal (between 0.2-0.47cm.) Visualized peristalsis appears appropriate. There were no focal lesions consistent with obstruction or a mass effect observed.

The ileocecal junction was visualized and exhibited normal intact wall layering and is subjectively of normal thickness. Sections of colon are visualized with formed fecal material and gas shadowing distally. There is no observed focal or generalized colon wall thickening or loss of layering.

### ***Pancreas***

The pancreas is normal and isoechoic to surrounding mesentery. There is no evidence of nodules or cystic lesions. There is no evidence of regional mesenteric inflammation or fluid.

### ***Free Abdomen***

Evaluation of the peritoneal cavity did not reveal any evidence of effusion, or subjective lymphadenomegaly. The Medial iliac nodes appear normal and there was no evidence of a caudal aortic thrombus at the bifurcation. The omentum is of normal uniform echogenicity.

### ***Other***

A brief view of the heart was submitted. No significant pericardial effusion was seen.

## **PRIMARY FINDINGS**

- Large, heterogeneous liver – The diffuse hepatic changes are non-specific and could be consistent with vacuolar hepatopathy, nodular hyperplasia, inflammatory/immune-mediated disease, fibrosis, extramedullary hematopoiesis, toxic hepatopathy (e.g., copper), infiltrative neoplasia (less likely) or other hepatopathy. The previously described hypoechoic nodules are not as prominent on today's scan.
- Large gallbladder debris – A large amount of debris is evident in the gall bladder with no evidence of a mucocele or associated inflammation at this time. This could represent an early mucocele or cholestasis, with minimal evidence of associated inflammation at this time. Continued monitoring of labwork and ultrasound are warranted for progression of this lesion. Ursodiol therapy could be considered.
- Hyperechoic nodule in the cranial pole of the right adrenal gland – Right adrenomegaly could be consistent with neoplasia (e.g., adenoma, carcinoma, pheochromocytoma), hyperplasia, inflammation, other. This nodule appears slightly, but not significantly larger than the previous scan on 8/2/22.

## **SECONDARY FINDINGS**

- Surgically absent left adrenal gland – adenocarcinoma diagnosed 4/22.
- Small non-obstructive nephroliths visualized in both kidneys – The hyperechoic mineralized foci observed at the corticomedullary junction of the left/right kidney are consistent with small, non-obstructive nephroliths.

- Hyperechoic foci visualized within the spleen – Findings are most consistent with benign myelolipomas.

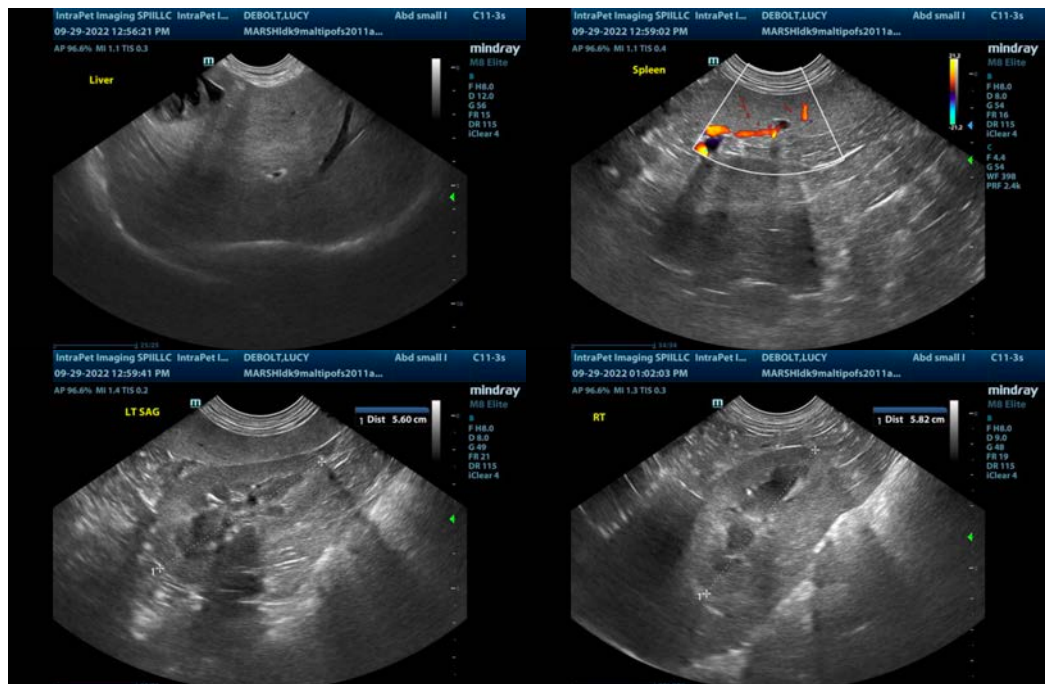
### INTERPRETATION OF THE FINDINGS & FURTHER RECOMMENDATIONS

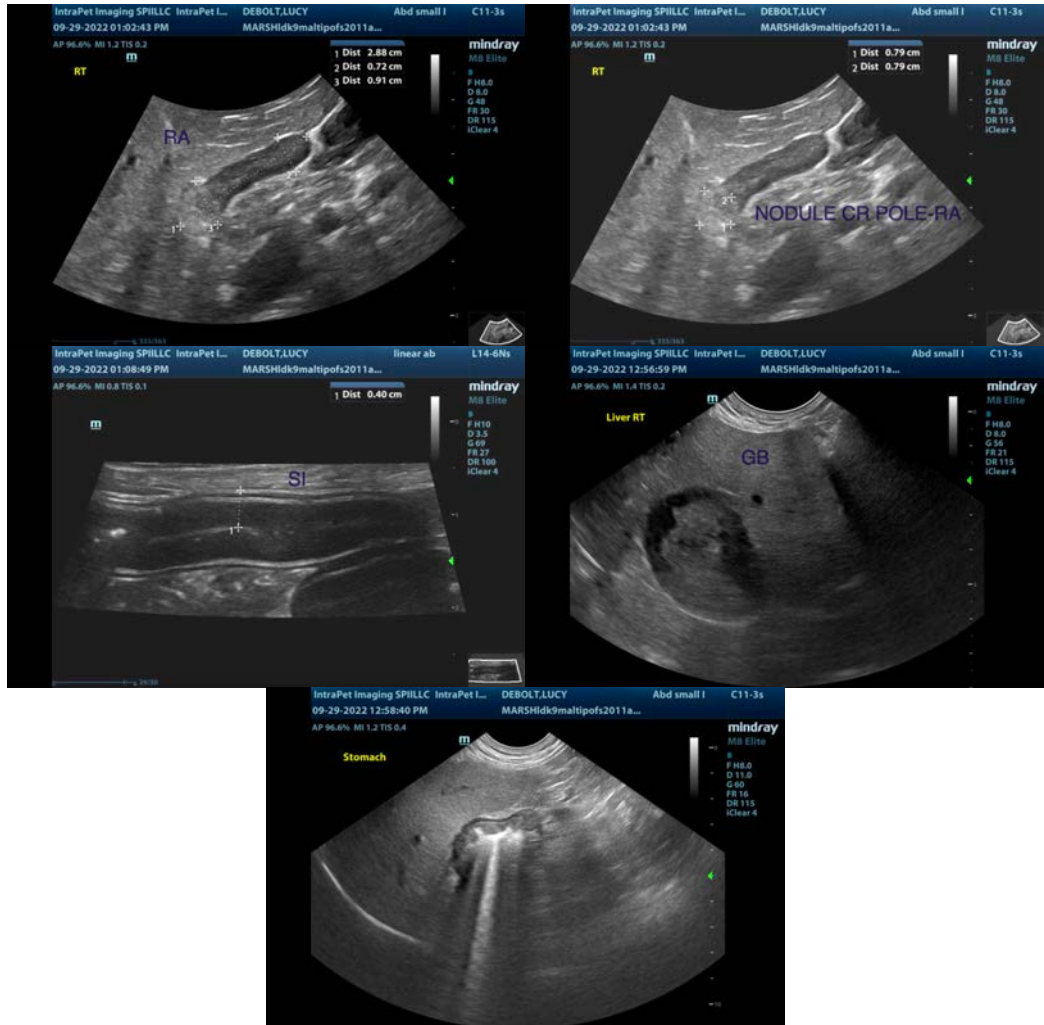The nodule previously visualized in the right adrenal gland appears slightly larger but not significantly larger. Recommendations previously made 8/2/22 are still appropriate. If symptoms have progressed, you could consider adrenalectomy (recommend referral to a veterinary surgeon with capability for post-operative management of a bilateral adrenalectomy). Alternately, if not already done, consider an adrenal panel to the University of Tennessee combined with an ACTH stimulation test to look for active hormone production, which could potentially be medically treated.

Recommend three view thoracic radiographs to evaluate for possible concurrent thoracic disease/involvement.

The changes observed in the liver are likely most consistent with a vacuolar hepatopathy/steroid hepatopathy. The previously described hypoechoic nodules are less apparent on today's scan.

There is a large amount of gallbladder debris present on today's scan. If liver enzymes are elevating, consider starting Ursodiol and continued monitoring of the gallbladder. Recommend recheck of the adrenal gland in 2-3 months.





The information and recommendations provided are based on the images presented by the referring veterinarian/sonographer. No evaluation can be communicated regarding pathology that was not visible in the image/video clips provided.

Thank you for this referral. If the clinical or image interpretation does not parallel your findings or if I can be of any further assistance please contact me.

Kathleen Sennello DVM,MS, Diplomate ACVIM (Small animal Internal Medicine)  
 kathleen.sennello@sonopath.com