



PATIENT

Indy Hay

SPECIES

Canine

BREED

St. Poodle

SEX

Neutered Male

AGE

5 Years

WEIGHT

27 kg

INTERPRETED BY

Kathleen Sennello
DVM, MS, Diplomate
ACVIM (Small Animal
Internal Medicine)

IMAGING PERFORMED BY

Kelly Reschny

HOSPITAL NAME

Main Street AH

REFERRING VET

Dr. Brochu

INVOICE

25855

DATE

9/29/21

PRESENTING CLINICAL SIGNS

Decreased appetite for the last month or so, vomiting couple times a week. Decreased muscle mass in last couple months. - M2 muscle wasting spine, forelimbs and hindlimbs - M1 jaundice - approx 10% body mass loss since January - would not allow full oral or rectal exam - solid bowel movements - Still lots of energy but decreased overall - drinking seems normal - urine a bit darker per owner
Abnormal PE/Chem/CBC/UA Results: Please see attached labs

ULTRASONOGRAPHIC EXAMINATION OF THE ABDOMEN

Urinary System

The urinary bladder is moderately distended with anechoic urine. The Bladder wall, trigone, ureteral papillae and visible urethra (to a depth of 2cm) appear normal with no evidence of wall thickening, mucosal irregularities, masses or cystic calculi.

The visualized areas of prostate and surrounding tissue appear normal. Unfortunately, the prostate is not fully visualized likely due to its intrapelvic location. Correlate with rectal exam findings.

The right kidney has a normal shape and size (6.98 cm). Overall echogenicity is normal with adequate corticomedullary distinction and a typical 1:3 cortex:medulla ratio. There is no evidence of perinephric inflammation or effusion. There is no evidence of pyelectasia, nephroliths, infarcts or hydroureter. Renal vasculature is normal.

The left kidney has a normal shape and size (7.51 cm). Overall echogenicity is normal with adequate corticomedullary distinction and a typical 1:3 cortex:medulla ratio. There is no evidence of perinephric inflammation or effusion. There is no evidence of pyelectasia, nephroliths, infarcts or hydroureter. Renal vasculature is normal.

Adrenal Glands

The left adrenal gland is normal in size measuring 0.57 cm. It is observed in its normal position cranial to the left renal artery. It is normal in appearance (uniformly hypoechoic) and shape with no evidence of a mass effect.

The right adrenal gland is normal in size measuring 0.63 cm. It is observed in its normal position between the cranial aspect of the right kidney and the caudal vena cava. It is normal in appearance (uniformly hypoechoic) and shape with no evidence of a mass effect.

Spleen

The spleen echotexture is homogenous, and the splenic capsule is smooth with no irregularities. The spleen is subjectively normal in size with no focal parenchymal abnormalities. The blood flow through the hilus and splenic parenchyma appears normal.

Liver

The liver is small and irregular. The parenchyma is heterogenous in echotexture with subtle, indistinct focal mottling. The visible portions of the vasculature and biliary tract appear normal. The liver is diffusely nodular and irregular with a somewhat shrunken/cirrhotic appearance.

The gall bladder lumen is moderately distended. The wall of the gall bladder is not thickened and has a smooth mucosal surface. Luminal contents are primarily anechoic. The cystic and common bile ducts are normal/not visible.



PATIENT

Indy Hay

Gastrointestinal

The stomach appears contains minimal luminal contents. It measures at a normal thickness of XX cm with some variability due to the presence of rugal folds. The distinction of the gastric wall layers is adequate and there is no impression of reduced peristaltic activity. No masses or focal lesions were observed.

SPECIES

Canine

The visualized areas of duodenum, jejunum and ileum have a relatively uniform diameter with minimal fluid distension. Wall thickness is normal. Bowel loops follow a curvilinear path with distinct wall layering maintaining the typical 1:3 muscularis:mucosa layer ratio. Visualized peristalsis appears appropriate. There were no focal lesions consistent with obstruction or a mass effect observed.

BREED

St. Poodle

The ileocecal junction was visualized and exhibited normal intact wall layering and is subjectively of normal thickness. Sections of colon are visualized with formed fecal material and gas shadowing distally. There is no observed focal or generalized colon wall thickening or loss of layering.

SEX

Neutered Male

Pancreas

The pancreas is normal and isoechoic to surrounding mesentery. There is no evidence of nodules or cystic lesions. There is no evidence of regional mesenteric inflammation or fluid.

AGE

5 Years

Free Abdomen

A large amount of anechoic free fluid is present. No lymphadenopathy. The omentum is of normal echogenicity.

WEIGHT

27 kg

ULTRASONOGRAPHIC FINDINGS

- Small, heterogeneous, diffusely nodular liver – The diffuse hepatic changes are non-specific and could be consistent with vacuolar hepatopathy, nodular hyperplasia, inflammatory/immune-mediated disease, fibrosis, extramedullary hematopoiesis, toxic hepatopathy (e.g., copper), infiltrative neoplasia (less likely) or other hepatopathy. The somewhat shrunken, irregular appearance of the liver is concerning for possible cirrhosis. Recommend biopsy to confirm.
- Large amount of free fluid – Primary differential would be portal hypertension, though other differentials should be considered.

INTERPRETED BY

Kathleen Sennello
DVM, MS, Diplomate
ACVIM (Small Animal
Internal Medicine)

INTERPRETATION OF THE FINDINGS & FURTHER RECOMMENDATIONS

The biliary tract appears normal, making a primary hepatopathy the most likely cause of the elevated bilirubin reported. Based on the appearance of the liver, I'm concerned about an end stage cirrhotic liver. Recommend a biopsy of the liver to assess prognosis and treatment options (provided coagulation parameters will allow). Consider potential historical exposure to toxins or chronic inflammatory disease. You could consider Leptospirosis testing. Culture and copper levels should be performed at the time of biopsy. Recommend 3-view thoracic radiographs.

IMAGING PERFORMED BY

Kelly Reschny

HOSPITAL NAME

Main Street AH

REFERRING VET

Dr. Brochu

INVOICE

25855

DATE

9/29/21



PATIENT

Indy Hay

SPECIES

Canine

BREED

St. Poodle

SEX

Neutered Male

AGE

5 Years

WEIGHT

27 kg

INTERPRETED BY

Kathleen Sennello
DVM, MS, Diplomate
ACVIM (Small Animal
Internal Medicine)

IMAGING PERFORMED BY

Kelly Reschny

HOSPITAL NAME

Main Street AH

REFERRING VET

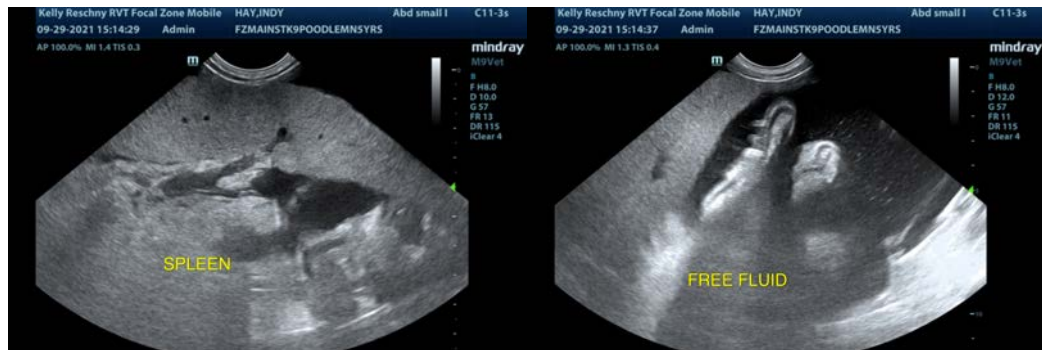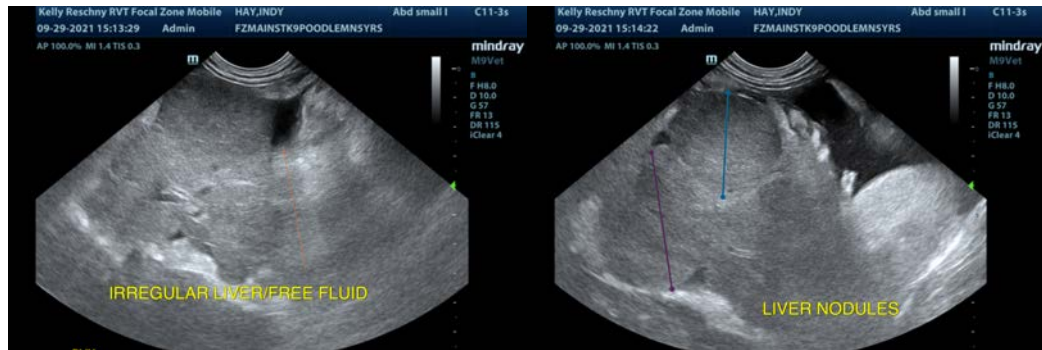
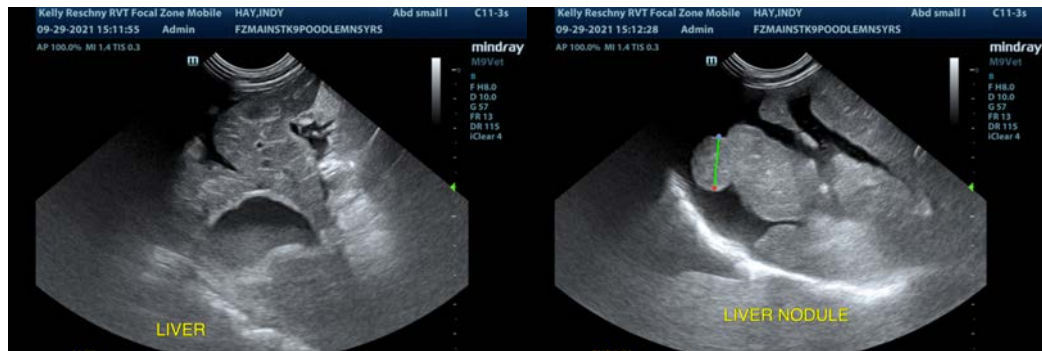
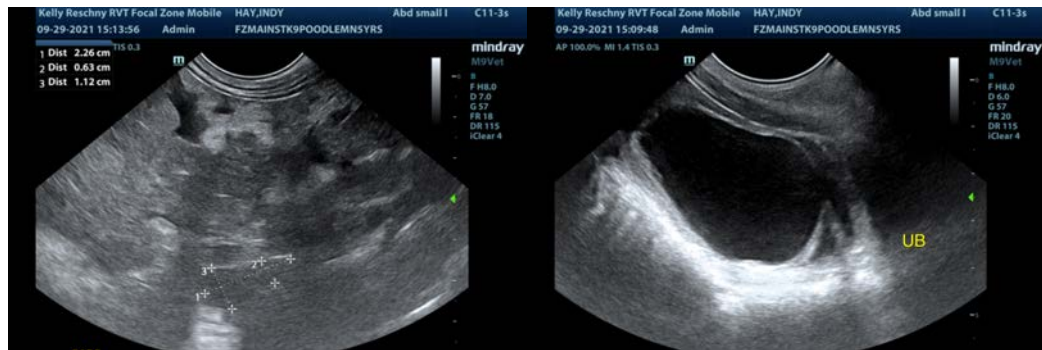
Dr. Brochu

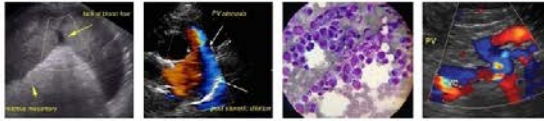
INVOICE

25855

DATE

9/29/21





PATIENT

Indy Hay

The information and recommendations provided are based on the images presented by the referring veterinarian. No evaluation can be communicated regarding pathology that was not visible in the image/video clips provided.

SPECIES

Canine

Thank you for this referral. If the clinical or image interpretation does not parallel your findings or if I can be of any further assistance please contact me.

BREED

St. Poodle

Kathleen Sennello DVM, MS, Diplomate ACVIM (Small Animal Internal Medicine)
info@sonopath.com

SEX

Neutered Male

AGE

5 Years

WEIGHT

27 kg

INTERPRETED BY

Kathleen Sennello
DVM, MS, Diplomate
ACVIM (Small Animal
Internal Medicine)

**IMAGING
PERFORMED BY**

Kelly Reschny

HOSPITAL NAME

Main Street AH

REFERRING VET

Dr. Brochu

INVOICE

25855

DATE

9/29/21