

**DATE**

9/29/21

**PRESENTING CLINICAL SIGNS**

History: Cholecystectomy with liver biopsy 8/2019 by CVSS. Pathology revealed mucocele and mild periportal lymphoplasmacytic hepatitis. Mild chronic elevated liver enzymes since then. Recently liver values have gotten much higher. Has become pu/pd with intermittent poor appetite.

**PATIENT**

Coley Blank

Current Medications: Ursodiol 60mg q24hr, Denamarin.

Lab Results: high alk phos, alt, ggt, mildly elevated Ca, high precision PSL.

Radiographs: Not provided by the veterinarian.

Date of Previous IntraPet Ultrasound: No previous IntraPet scans.

Sedation: Sedation not required for scan.

Stat Report: STAT report not requested by the veterinarian.

**SPECIES**

Canine

**BREED**

Schnoodle

**SEX**

Spayed Female

**AGE**

10/06

**WEIGHT**

14.8 lbs

**ULTRASONOGRAPHIC EXAMINATION OF THE ABDOMEN****Urinary System**

The urinary bladder is moderately distended with anechoic urine. The Bladder wall, trigone, ureteral papillae and visible urethra (to a depth of 2cm) appear normal with no evidence of wall thickening, mucosal irregularities, masses or cystic calculi.

The left kidney has a normal shape and size (4.62 cm). Overall echogenicity is normal with adequate corticomedullary distinction and a typical 1:3 cortex:medulla ratio. There is no evidence of perinephric inflammation or effusion. Non-obstructive nephroliths were noted and measured 0.28 cm and 0.18 cm. There is no evidence of pyelectasia, infarcts or hydroureter. Renal vasculature is normal.

The right kidney has a normal shape and size (4.35 cm). Overall echogenicity is normal with adequate corticomedullary distinction and a typical 1:3 cortex:medulla ratio. There is no evidence of perinephric inflammation or effusion. Numerous, small, non-obstructive nephroliths were noted. There is no evidence of pyelectasia, infarcts or hydroureter. Renal vasculature is normal.

**INTERPRETED BY**

Kathleen Sennello  
DVM, MS, Diplomate  
ACVIM (Small Animal  
Internal Medicine)

**Adrenal Glands**

The left adrenal gland is normal in size measuring 0.58 cm at the caudal pole It is observed in its normal position cranial to the left renal artery. It is normal in appearance (uniformly hypoechoic) and shape with no evidence of a mass effect.

The right adrenal gland is normal in size measuring 0.69 cm at the caudal pole It is observed in its normal position between the cranial aspect of the right kidney and the caudal vena cava. It is normal in appearance (uniformly hypoechoic) and shape with no evidence of a mass effect.

**HOSPITAL NAME**

Stevenson Village VH

**Spleen**

The spleen is subjectively normal in size, echotexture is homogenous, and the splenic capsule is smooth with no irregularities. The blood flow through the hilus and splenic parenchyma appears normal. No focal parenchymal abnormalities are visualized.

**REFERRING VET**

Dr. Feinberg

**INVOICE**

92079

**Liver**

The liver is subjectively normal in size, and echogenicity with somewhat rounded margins. The parenchyma is heterogenous in echotexture with subtle, indistinct focal mottling. The visible portions of the vasculature and biliary tract appear normal. The right side of the liver appears more discretely rounded almost creating the appearance of a mass effect, but there is no discrete margins or change in echogenicity. Additionally there are too numerous to count, small, hyperechoic foci throughout the parenchyma and a 0.96 cm, hyperechoic nodule visualized in the right side. The gallbladder is absent as it was surgically removed 8/19.

### ***Gastrointestinal***

The stomach contains minimal luminal contents. It measures at a normal thickness of <0.7cm with some variability due to the presence of rugal folds. The distinction of the gastric wall layers is adequate and there is no impression of reduced peristaltic activity. No masses or focal lesions were observed.

The visualized areas of duodenum, jejunum and ileum have a relatively uniform diameter with minimal fluid distension. Wall thickness is normal. Bowel loops follow a curvilinear path with distinct wall layering maintaining the typical 1:3 muscularis:mucosa layer ratio. The duodenum measured as normal (0.47 cm) and the jejunum measured as normal (0.38 cm). Visualized peristalsis appears appropriate. There were no focal lesions consistent with obstruction or a mass effect observed.

The ileocecal junction was visualized and exhibited normal intact wall layering and is subjectively of normal thickness. Sections of colon are visualized with formed fecal material and gas shadowing distally. There is no observed focal or generalized colon wall thickening or loss of layering.

### ***Pancreas***

The pancreas is prominent and hypoechoic as compared to the surrounding isoechoic mesentery. There is no evidence of nodules or cystic lesions. There is no evidence of regional mesenteric inflammation or fluid.

### ***Free Abdomen***

Evaluation of the peritoneal cavity did not reveal any evidence of effusion, or subjective lymphadenomegaly. The Medial iliac nodes appear normal and there was no evidence of a caudal aortic thrombus at the bifurcation. The omentum is of normal uniform echogenicity.

## **ULTRASONOGRAPHIC FINDINGS**

### **PRIMARY FINDINGS:**

- Large, irregular, heterogenous liver with hyperechoic foci/nodule. The diffuse hepatic changes are non-specific and could be consistent with vacuolar hepatopathy, nodular hyperplasia, inflammatory/immune-mediated disease, fibrosis, extramedullary hematopoiesis, toxic hepatopathy (e.g., copper), infiltrative neoplasia (less likely) or other hepatopathy.
- Prominent, hypoechoic pancreas. The pancreatic changes are most consistent with moderate pancreatitis/pancreatic infiltration. I recommend fPLI testing and continued monitoring for improvement or possible development of a pancreatic abscess. Consider FNA if not improving.

### **SECONDARY FINDINGS:**

- Non-obstructive nephroliths in both kidneys. The hyperechoic mineralized foci observed at the corticomedullary junction of the left/right kidney are consistent with small, non-obstructive nephroliths.
- No gallbladder visualized-surgically removed 8/19.

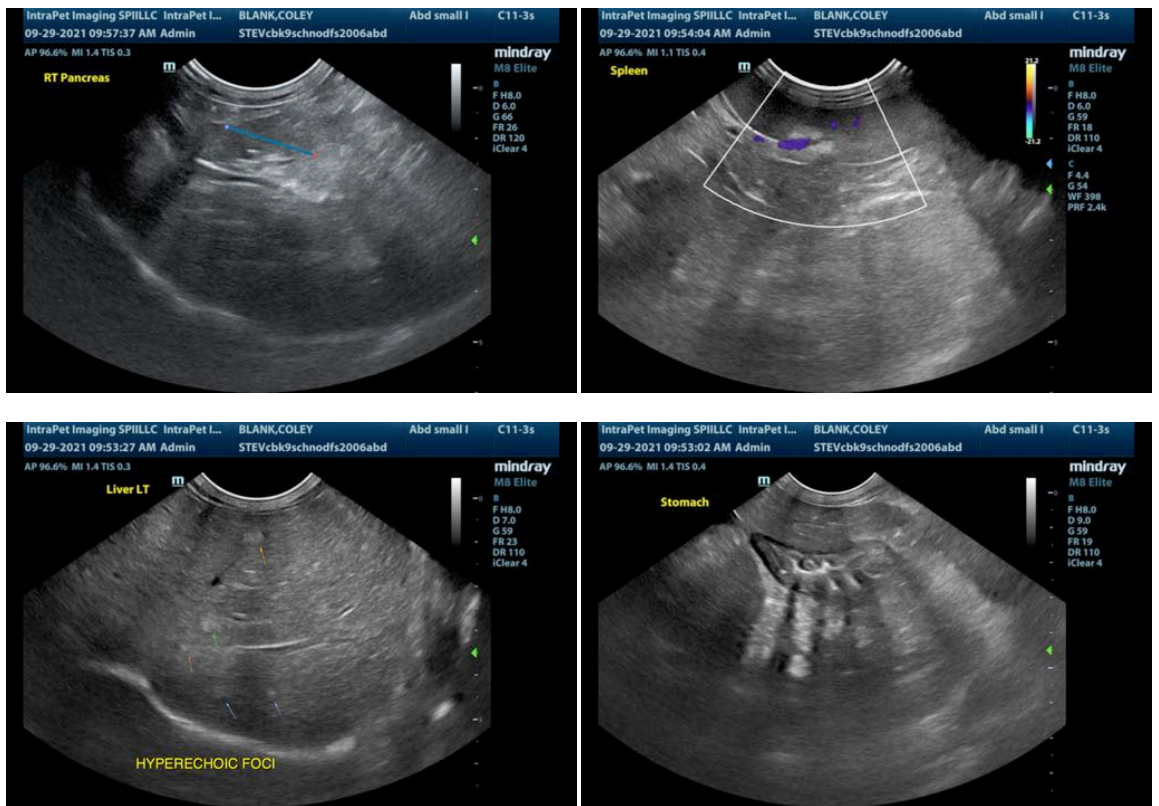
## **INTERPRETATION OF THE FINDINGS & FURTHER RECOMMENDATIONS**

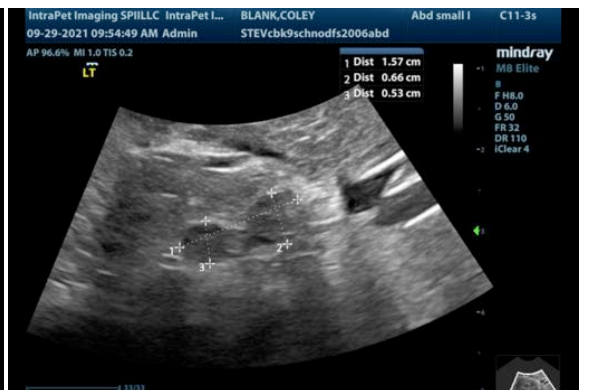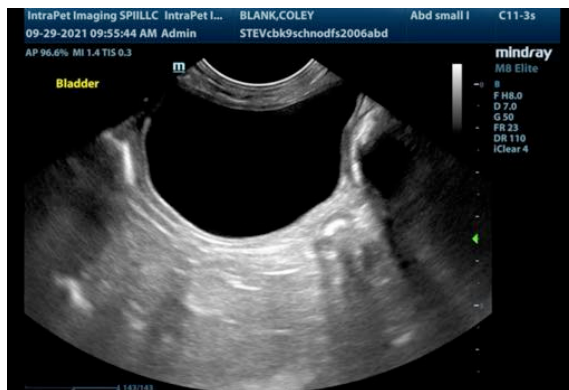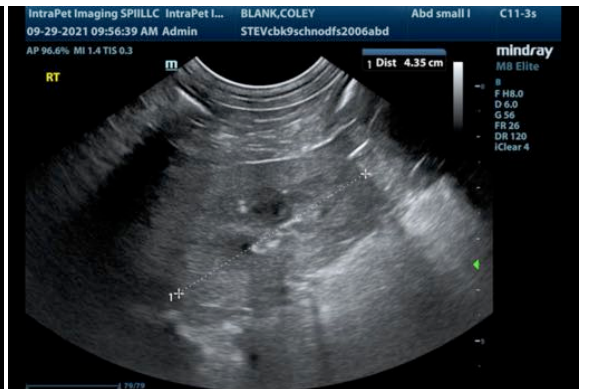
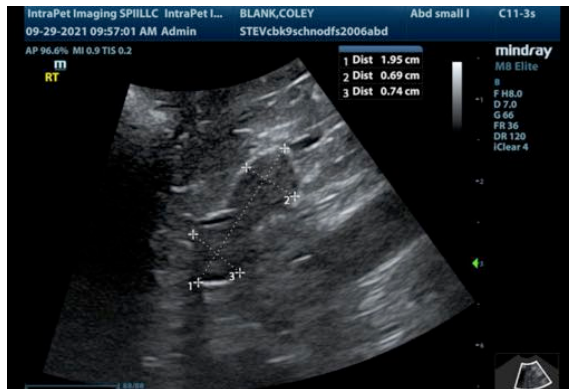
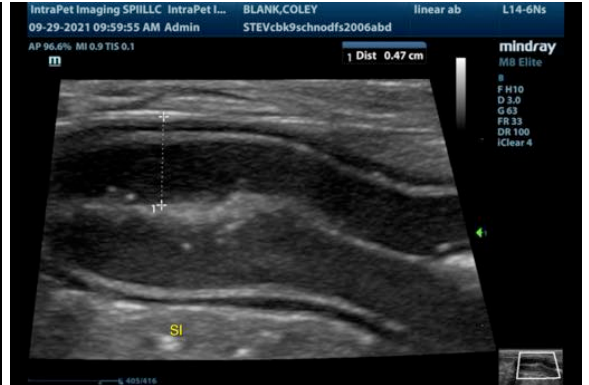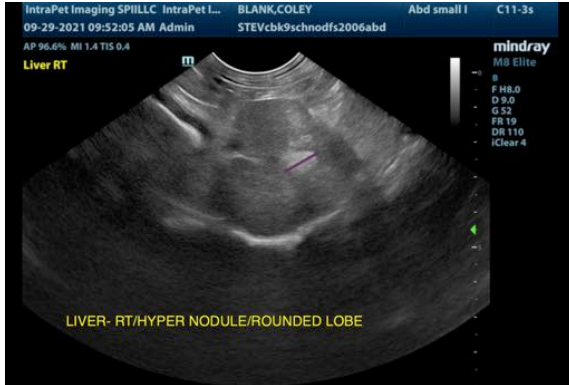I am concerned that you may be progressive liver disease in this patient. The liver changes are non-specific and diffuse. Consider the following:

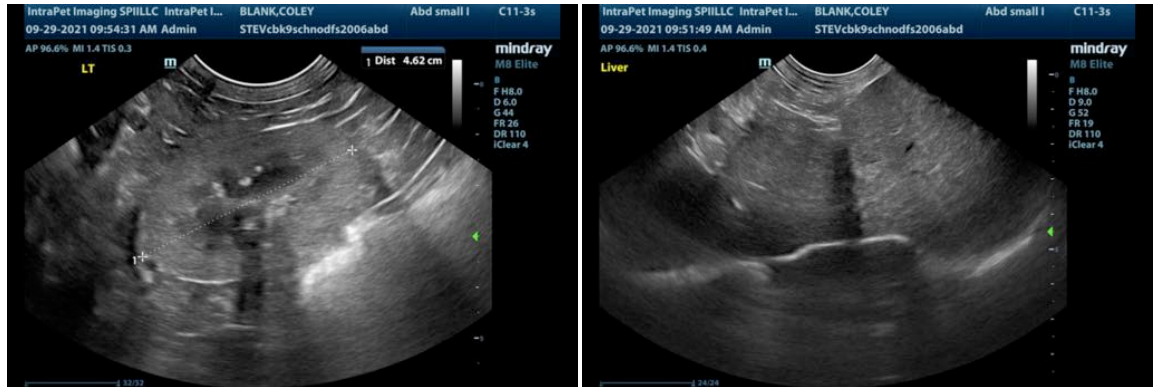
- Consider close evaluation of history for possible toxic changes examine medications, diet, dietary indiscretion etc...
- Consider PCR on urine/serum for leptospirosis (if not on antibiotics)/serology if recent antibiotic history
- If not already done, consider pre and post prandial bile acids to evaluate liver function

Induction phenomenon is the common cause for a very elevated ALP. These are systemic illnesses that turn on the liver enzyme. Causes of these include Cushing's disease, dental disease, arthritis and numerous others. In many cases the exact cause is unclear, but as long as ultrasound and bile acids are normal most patients do not have progressive changes in their liver. Although liver biopsy is not routinely performed vacuolar hepatopathy is noted on most biopsies. This is often progressive, but in rare cases can be more significant and linked to liver failure. Based on the history provided the biopsies were not consistent with the vacuolar hepatopathy and additionally there is a significant ALT elevation so there is concern for a more aggressive disease process.

- If signs of Cushing's disease are present I recommend endocrine function testing to evaluate for Cushing's disease.
- Consider FNA to rule out round cell neoplasia.
- If bile acids are abnormal consider re-biopsy of the liver to determine current status.
- Recommend continued long term use of Denamarin and Ursodiol.
- Recommend urinalysis and culture to rule out other causes of PU/PD.







The information and recommendations provided are based on the images presented by the referring veterinarian. No evaluation can be communicated regarding pathology that was not visible in the image/video clips provided.

Thank you for this referral. If the clinical or image interpretation does not parallel your findings or if I can be of any further assistance please contact me.

Kathleen Sennello DVM,MS, Diplomate ACVIM (Small animal Internal Medicine)  
kathleen.sennello@sonopath.com