

**DATE PRESENTING CLINICAL SIGNS**

9/2822

PUPD, likely primary polydipsia based on prior USG. Initially underweight and requiring more calories than he should to gain appropriately and maintain normal BCS/MCS, better on more calories but probably should not need this much, intermittent diarrhea, questionable polyphagia. Low baseline cortisol. Also, history of heart murmur that is now 4/6 (CVCA evaluation scheduled for October). Also, potentially cryptorchid based on PE today.

**PATIENT**

Copper Olsen

**SPECIES**

Canine

**BREED**

Hound X

**SEX**

Intact Male

**AGE**

6/23/22

**WEIGHT**

8.1 kg

**INTERPRETED BY**

Kathleen Sennello DVM,  
MS, Diplomate ACVIM  
(Small Animal Internal  
Medicine)

**IMAGING PERFORMED BY**

Andi Parkinson RDMS

**HOSPITAL NAME**

Nexus Vet Specialists

**REFERRING VET**

Dr. Steele

**INVOICE**

41720

Current Medications: None.

Lab Results: 9/26: Cortisol 1.85. 9/14: USG 1.004 (midday sample at rDVM visit). 9/9: CBC--PLT 597K,, lymphs 5829, monos 1005. Chem--ALP 189, phos 9.2, low Na/K ratio of 26 (Na 143,K 5.4). UA--USG 1.038 (first morning sample), pH 6.0, trace protein, struvite crystals and otherwise quiet sediment. 8/25: UA (first morning) USG 1.042, pH 6.0, trace protein.

Date of Previous IntraPet Ultrasound: No previous.

Sedation: Patient sedated with Torbugesic.

Stat Report: Not requested.

**ULTRASONOGRAPHIC EXAMINATION OF THE ABDOMEN****Urinary System**

The urinary bladder is moderately distended with anechoic urine. The Bladder wall, trigone, ureteral papillae and visible urethra (to a depth of 2cm) appear normal with no evidence of wall thickening, mucosal irregularities, masses or cystic calculi.

The visualized areas of prostate and surrounding tissue appear normal. Unfortunately, the prostate is not fully visualized likely due to its intrapelvic location. Correlate with rectal exam findings.

The left kidney has a normal shape and size (5.67 cm). Overall echogenicity is normal with adequate corticomedullary distinction and a typical 1:3 cortex:medulla ratio. There is no evidence of focal perinephric inflammation or effusion. There is no evidence of pyelectasia, nephroliths, infarcts or hydroureter. Renal vasculature is normal.

The right kidney has a normal shape and size (5.75 cm). Overall echogenicity is normal with adequate corticomedullary distinction and a typical 1:3 cortex:medulla ratio. There is no evidence of focal perinephric inflammation or effusion. There is no evidence of pyelectasia, nephroliths, infarcts or hydroureter. Renal vasculature is normal.

**Adrenal Glands**

The left adrenal gland is normal/borderline small measuring 0.36 cm at the caudal pole. It is observed in its normal position cranial to the left renal artery. It is normal in appearance (uniformly hypoechoic) and shape with no evidence of a mass effect.

The right adrenal gland is normal/borderline small, measuring 0.30 cm at the caudal pole. It is observed in its normal position between the cranial aspect of the right kidney and the caudal vena cava. It is normal in appearance (uniformly hypoechoic) and shape with no evidence of a mass effect.

**Spleen**

The spleen is subjectively normal in size, echotexture is homogenous, and the splenic capsule is smooth with no irregularities. The blood flow through the hilus and splenic parenchyma appears normal. No focal parenchymal abnormalities are visualized.

### ***Liver***

The liver is subjectively normal in size, and echogenicity with smooth peripheral margins. The parenchyma is homogenous echotexture. The visible portions of the vasculature and biliary tract appear normal. No focal nodules or cystic lesions are observed.

The gallbladder lumen is moderately distended. The wall of the gall bladder is not thickened and has a smooth mucosal surface. Luminal contents are mild and primarily anechoic. The cystic and common bile ducts are normal/not visible.

### ***Gastrointestinal***

The stomach contains minimal luminal contents. It measures at a normal thickness of <0.7cm with some variability due to the presence of rugal folds. The distinction of the gastric wall layers is adequate and there is no impression of reduced peristaltic activity. No masses or focal lesions were observed.

The visualized areas of duodenum, jejunum and ileum have a relatively uniform diameter with minimal fluid distension. Wall thickness is normal. Bowel loops follow a curvilinear path with distinct wall layering maintaining the typical 1:3 muscularis:mucosa layer ratio. Duodenum wall measures 0.40 cm. Jejunum wall measures 0.33 cm. Visualized peristalsis appears appropriate. There were no focal lesions consistent with obstruction or a mass effect observed.

The ileocecal junction was visualized and exhibited normal intact wall layering and is subjectively of normal thickness. Sections of colon are visualized with formed fecal material and gas shadowing distally. There is no observed focal or generalized colon wall thickening or loss of layering.

### ***Pancreas***

The pancreas is normal and isoechoic to surrounding mesentery. There is no evidence of nodules or cystic lesions. There is no evidence of regional mesenteric inflammation or fluid.

### ***Free Abdomen***

Evaluation of the peritoneal cavity did not reveal any evidence of effusion. There are prominent mesenteric lymph nodes and lymph nodes around the ileocecal junction measuring 0.59, 0.45, 0.39 cm. The omentum is of normal echogenicity.

### ***Other***

Both the testicles are located within the scrotum.

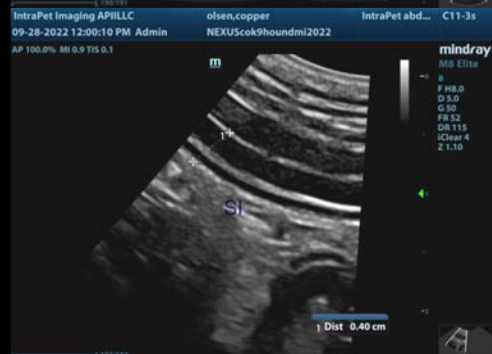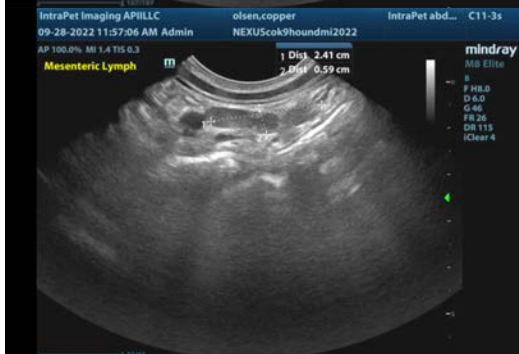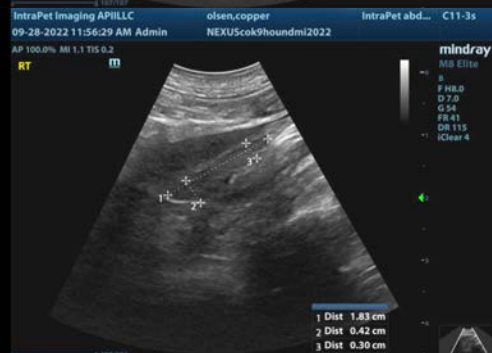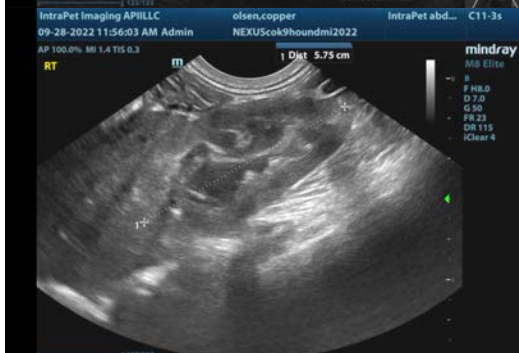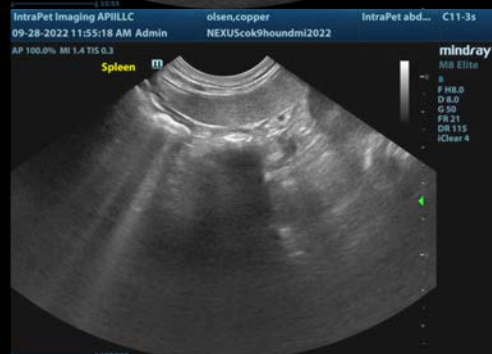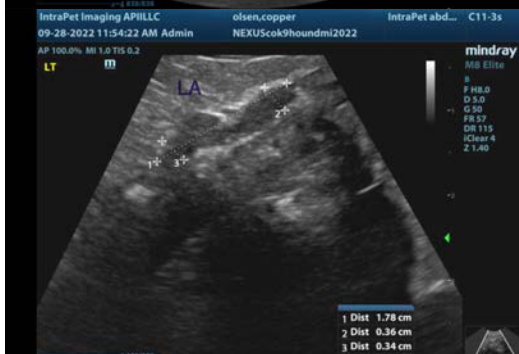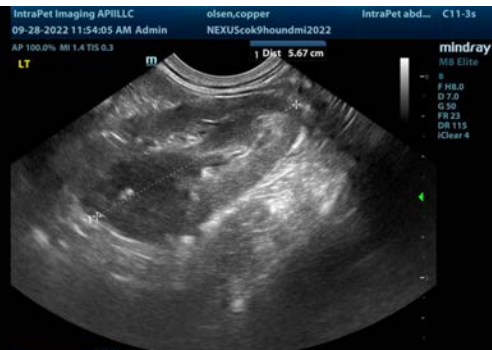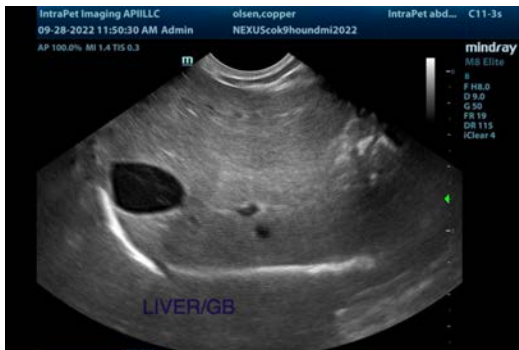## **ULTRASONOGRAPHIC FINDINGS**

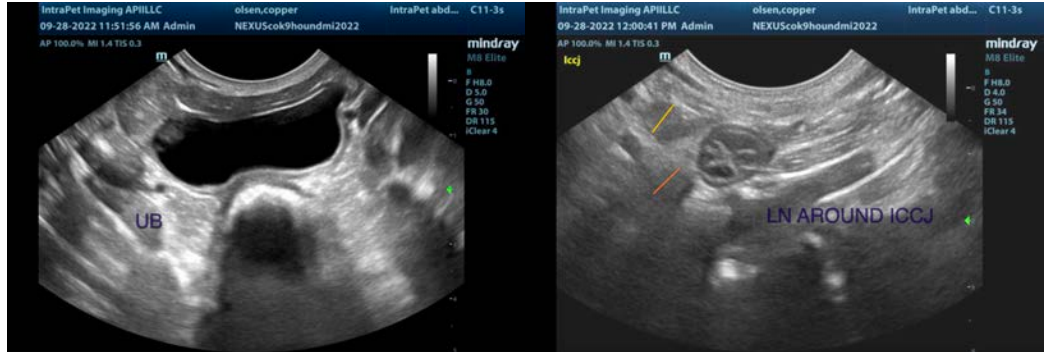
- Prominent mesenteric lymph node – The prominent abdominal lymph nodes are most consistent with reactive lymphadenitis or lymphoid hyperplasia. Neoplastic infiltration is considered less likely. Prominent lymph nodes likely these are common in young dogs.
- Borderline small adrenal glands – This could be normal for such a young dog. Consider screening for Addison's.

## **INTERPRETATION OF THE FINDINGS & FURTHER RECOMMENDATIONS**

The ultrasonographic findings in today's scan are mild/likely normal for a dog this young, but include prominent mesenteric lymph nodes and borderline small adrenals.

Further diagnostic and therapeutic recommendations regarding this exam to be made by Dr. Cara Steele.





The information and recommendations provided are based on the images presented by the referring veterinarian/sonographer. No evaluation can be communicated regarding pathology that was not visible in the image/video clips provided.

Thank you for this referral. If the clinical or image interpretation does not parallel your findings or if I can be of any further assistance please contact me.

Kathleen Sennello DVM,MS, Diplomate ACVIM (Small animal Internal Medicine)  
kathleen.sennello@sonopath.com