**DATE**

9/27/21

PRESENTING CLINICAL SIGNS

History: Presenting Complaint: Drinking More; Eating More Than Normal. Date: 09-27-2021 Notes: Trouble jumping up on chair, noticed June-July. 3mo ago starting to seem like he was starving although diet has not changed. He is drinking 2 bowls of water per day when previously 1 bowl would have lasted a few days. (Diet: Little Caesar's wet + 1c RR dry + treat in AM and PM). Now he is urinating in the house, very unlike patient. Weight gain from 22 to 25 pounds despite cutting treats down. rDVM 9/4: BW, Rx ABX (for fever), and Denamarin (inc LES). rDVM 9/20 not improving: rads = dec disk space, Rx Pred, another ABX, cont. Denamarin. No improvement. O stopped giving Pred on Friday. Assessment: 8 YO MN JRT X- PC: ADR; PU/PD/PP; weight gain.

PATIENT

Sven Kues

SPECIES

Canine

BREEDJack Russell Terrier
Mix**SEX**

Neutered male

AGE

8/15/13

WEIGHT

25 lbs

INTERPRETED BYKathleen Sennello
DVM, MS, Diplomate
ACVIM (Small Animal
Internal Medicine)**HOSPITAL NAME**Animal Emergency
Hospital**REFERRING VET**

Dr. Jones

INVOICE

92045

Plan: SWO: Discussed the elevated LES - rec rechecking. Strongly rec testing for Cushing's with rDVM. Will need to be washed out of the Pred before testing though. In the meantime, consider AUS. O would like to proceed with dx here. Start with BW today, AUS tomorrow as drop-off.

Current Medications: Denamarin.

Lab Results: Attached separately within request form.

Radiographs: Decreased disc space.

Date of Previous IntraPet Ultrasound: No previous IntraPet scans.

Sedation: Sedation not required for scan.

Stat Report: STAT report not requested by the veterinarian.

ULTRASONOGRAPHIC EXAMINATION OF THE ABDOMEN**Urinary System**

The urinary bladder is moderately distended with anechoic urine. The Bladder wall, trigone, ureteral papillae and visible urethra (to a depth of 2cm) appear normal with no evidence of wall thickening, mucosal irregularities, masses or cystic calculi.

The left kidney has a normal shape and size (4.88 cm). Overall echogenicity is normal with adequate corticomedullary distinction and a typical 1:3 cortex:medulla ratio. There is no evidence of perinephric inflammation or effusion. Small, non-obstructive stones were noted in the left kidney. There is no evidence of pyelectasia, infarcts or hydroureter. Renal vasculature is normal.

The right kidney has a normal shape and size (5.35 cm). Overall echogenicity is normal with adequate corticomedullary distinction and a typical 1:3 cortex:medulla ratio. There is no evidence of perinephric inflammation or effusion. A 0.65 cm, non-obstructive nephrolith was noted. There is no evidence of pyelectasia, infarcts or hydroureter. Renal vasculature is normal.

Adrenal Glands

The left adrenal gland is normal in size measuring 0.52 cm at the caudal pole It is observed in its normal position cranial to the left renal artery. It is normal in appearance (uniformly hypoechoic) and shape with no evidence of a mass effect.

The right adrenal gland is normal in size measuring 0.48 cm at the caudal pole It is observed in its normal position between the cranial aspect of the right kidney and the caudal vena cava. It is normal in appearance (uniformly hypoechoic) and shape with no evidence of a mass effect.

Spleen

The spleen is subjectively normal in size, echotexture is homogenous, and the splenic capsule is smooth with no irregularities. The blood flow through the hilus and splenic parenchyma appears normal. No focal parenchymal abnormalities are visualized.

Liver

The liver is subjectively large in size, and echogenicity with smooth peripheral margins. The parenchyma is heterogenous in echotexture with subtle, indistinct focal mottling. The visible portions of the vasculature and biliary tract appear normal. No focal nodules or cystic lesions are observed. The gallbladder lumen is moderately distended. The wall of the gallbladder is not thickened and has a smooth mucosal surface. There is a moderate amount of non-organized echogenic debris. The cystic and common bile ducts are normal/not visible.

Gastrointestinal

The stomach contains minimal luminal contents. It measures at a normal thickness of <0.7cm with some variability due to the presence of rugal folds. The distinction of the gastric wall layers is adequate and there is no impression of reduced peristaltic activity. No masses or focal lesions were observed.

The visualized areas of duodenum, jejunum and ileum have a relatively uniform diameter with minimal fluid distension. Wall thickness is normal. Bowel loops follow a curvilinear path with distinct wall layering maintaining the typical 1:3 muscularis:mucosa layer ratio. The duodenum measured as normal and the jejunum measured as normal (0.32 cm). Visualized peristalsis appears appropriate. There were no focal lesions consistent with obstruction or a mass effect observed.

The ileocecal junction was visualized and exhibited normal intact wall layering and is subjectively of normal thickness. Sections of colon are visualized with formed fecal material and gas shadowing distally. There is no observed focal or generalized colon wall thickening or loss of layering.

Pancreas

The pancreas is normal and isoechoic to surrounding mesentery. There is no evidence of nodules or cystic lesions. There is no evidence of regional mesenteric inflammation or fluid.

Free Abdomen

Evaluation of the peritoneal cavity did not reveal any evidence of effusion, or subjective lymphadenomegaly. The Medial iliac nodes appear normal and there was no evidence of a caudal aortic thrombus at the bifurcation. The omentum is of normal uniform echogenicity.

ULTRASONOGRAPHIC FINDINGS

PRIMARY FINDINGS:

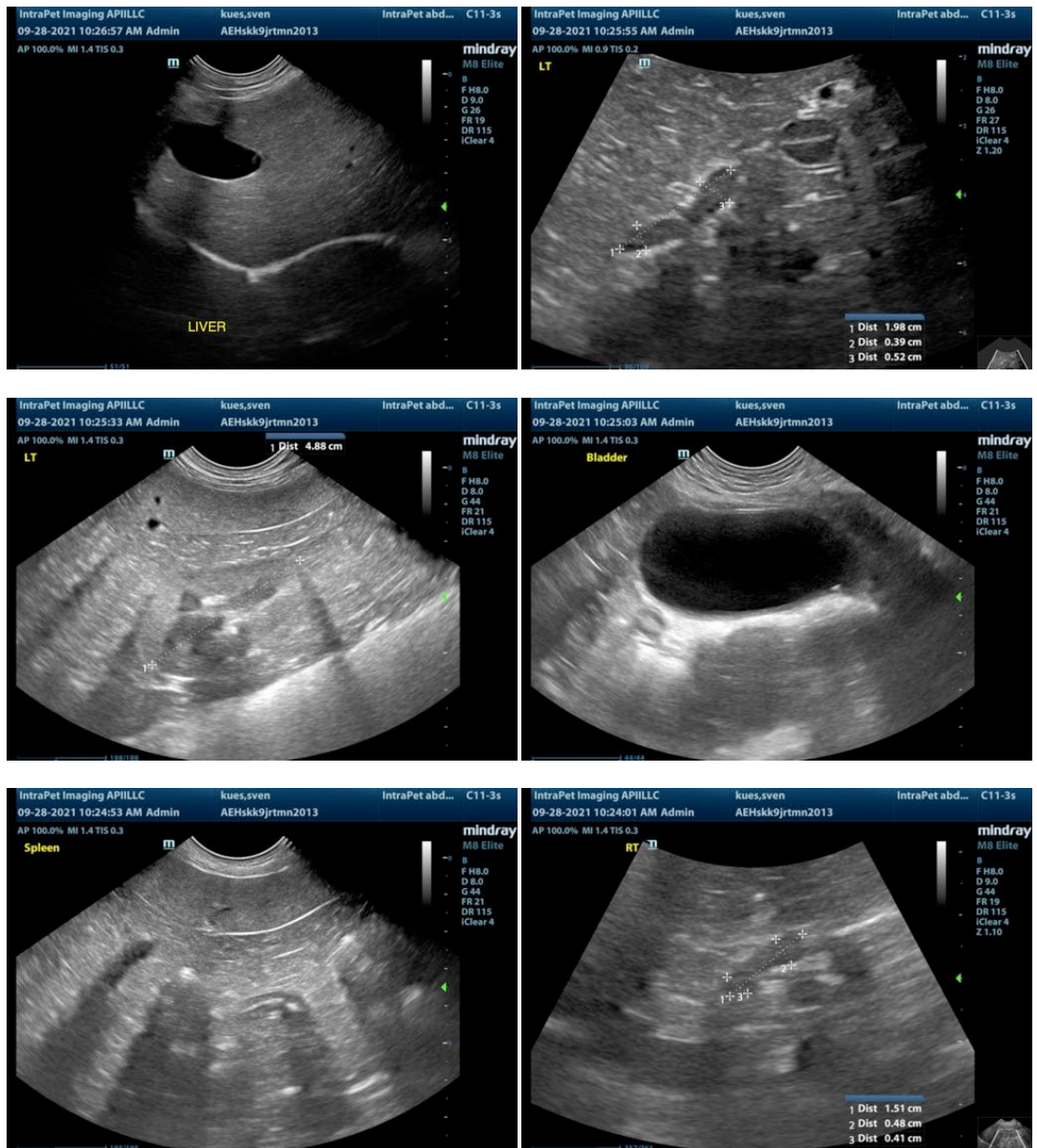
- Large, heterogenous liver. The diffuse hepatic changes are non-specific and could be consistent with vacuolar hepatopathy, nodular hyperplasia, inflammatory/immune-mediated disease, fibrosis, extramedullary hematopoiesis, toxic hepatopathy (e.g., copper), infiltrative neoplasia (less likely) or other hepatopathy. This is likely associated with the recent prednisone use.
- Moderate gallbladder sludge. The significance of the aggregated gallbladder debris is unclear. This could represent an early mucocele, cholestasis, or may be secondary to fasting.

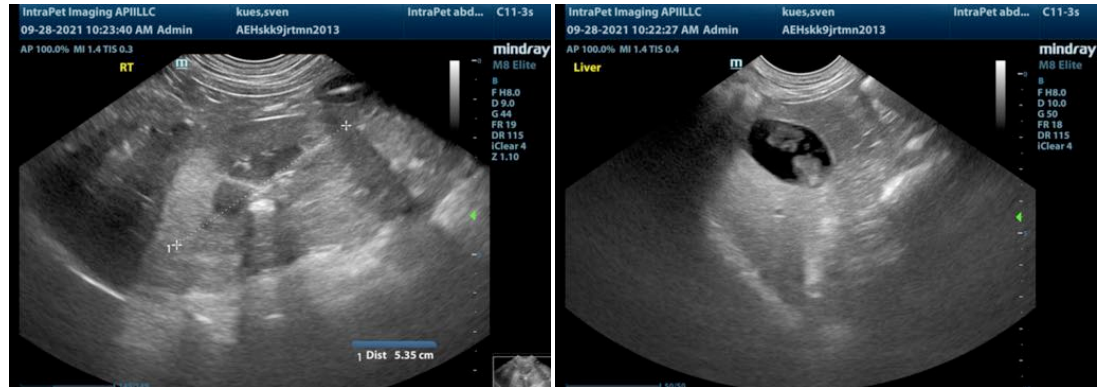
SECONDARY FINDINGS:

Small, non-obstructive nephroliths visualized in both kidneys. The hyperechoic mineralized foci observed at the corticomedullary junction of the left/right kidney are consistent with small, non-obstructive nephroliths.

INTERPRETATION OF THE FINDINGS & FURTHER RECOMMENDATIONS

There were no significant focal lesions observed on today's scan. I suspect much of the increased thirst, polyphagia and elevated liver enzymes could be associated with the current Prednisone use. I recommend tapering and reevaluation approximately 8 weeks after discontinuing all steroid therapy. If the patient is getting worse during this period alternate causes will need to be considered.





The information and recommendations provided are based on the images presented by the referring veterinarian. No evaluation can be communicated regarding pathology that was not visible in the image/video clips provided.

Thank you for this referral. If the clinical or image interpretation does not parallel your findings or if I can be of any further assistance please contact me.

Kathleen Sennello DVM,MS, Diplomate ACVIM (Small animal Internal Medicine)
kathleen.sennello@sonopath.com