



PATIENT

Duncan Peppel

SPECIES

Canine

BREED

Miniature Poodle

SEX

Neutered male

AGE

14.8 years

WEIGHT

17.8 lbs

INTERPRETED BY

Kathleen Sennello
DVM, MS, Diplomate
ACVIM (Small Animal
Internal Medicine)

IMAGING PERFORMED BY

Dr. Mengine

HOSPITAL NAME

Stoney Creek VH

REFERRING VET

Dr. Mengine

INVOICE

92029

DATE

9/28/21

PRESENTING CLINICAL SIGNS

History: Patient had AUS elsewhere in 3/21, identified a liver mass in L craniomedial liver (5.4 x 5.7 x 7.1cm), bilateral nephroliths in renal pelvises with partial pelvic dilation in both kidneys, and multiple round cystic calculi (6-7mm diameter). Patient has stable labwork except a slowly increasing SDMA and chronic bacteruria. Patient is doing well except for intermittent inappetence, ultrasound is to assess progression of these findings

ULTRASONOGRAPHIC EXAMINATION OF THE ABDOMEN

Urinary System

The urinary bladder is moderately distended with echogenic urine. The Bladder wall, trigone, ureteral papillae and visible urethra (to a depth of 2cm) appear normal with no evidence of wall thickening, mucosal irregularities or masses. There are at least two, moderate sized, shadowing stones in the urinary bladder that measured approximately 1.03 cm and 0.98 cm. The stones were visualized in the dependent portion of the urinary bladder. These findings should be correlated with abdominal radiographs.

The prostate was normal at 0.74 cm.

The left kidney has a normal shape and size (5.27 cm). Overall echogenicity is slightly hyperechoic with poor corticomedullary distinction and a typical 1:3 cortex:medulla ratio. There is no evidence of perinephric inflammation or effusion. The left kidney has a non-obstructive nephrolith that measured 0.32 cm and pyelectasia that measured 0.32 cm. There is no evidence of infarcts or hydroureter. Renal vasculature is normal.

The right kidney has a normal shape and size (XXcm). Overall echogenicity is slightly hyperechoic with poor corticomedullary distinction and a typical 1:3 cortex:medulla ratio. There is no evidence of perinephric inflammation or effusion. There are multiple, shadowing nephroliths visualized in the renal pelvis. The renal pelvis is dilated at 0.7 cm. This is consistent with possible partial obstruction/previous obstruction. There is no evidence of infarcts or hydroureter. Renal vasculature is normal.

Adrenal Glands

The left adrenal gland is normal in size measuring 0.4 cm at the caudal pole It is observed in its normal position cranial to the left renal artery. It is normal in appearance (uniformly hypoechoic) and shape with no evidence of a mass effect.

The right adrenal gland is normal in size measuring 0.46 cm at the caudal pole It is observed in its normal position between the cranial aspect of the right kidney and the caudal vena cava. It is normal in appearance (uniformly hypoechoic) and shape with no evidence of a mass effect.

Spleen

The spleen is subjectively normal in size, echotexture is homogenous, and the splenic capsule is smooth with no irregularities. The blood flow through the hilus and splenic parenchyma appears normal. No focal parenchymal abnormalities are visualized.



PATIENT

Liver

Duncan Peppel

The liver is subjectively large in size, and echogenicity with smooth peripheral margins. The parenchyma is heterogenous in echotexture with subtle, indistinct focal mottling. The visible portions of the vasculature and biliary tract appear normal. There is a large, solid, irregular, isoechoic mass effect that is visualized in the right side of the liver measuring 5.88 x 5.41 cm (previous measurement 3/21 was 5.4 x 5.7 x 7.1 cm). The gallbladder lumen is moderately distended. The wall of the gallbladder is not thickened and has a smooth mucosal surface. There is a moderate amount of non-organized echogenic debris. The cystic and common bile ducts are normal/not visible.

SPECIES

Canine

BREED

Miniature Poodle

Gastrointestinal

SEX

Neutered male

The stomach contains minimal luminal contents. It measures at a normal thickness of <0.7cm with some variability due to the presence of rugal folds. The distinction of the gastric wall layers is adequate and there is no impression of reduced peristaltic activity. No masses or focal lesions were observed.

AGE

14.8 years

The visualized areas of duodenum, jejunum and ileum have a relatively uniform diameter with minimal fluid distension. Wall thickness is normal. Bowel loops follow a curvilinear path with distinct wall layering maintaining the typical 1:3 muscularis:mucosa layer ratio. The duodenum measured as normal (0.37 cm) and the jejunum measured as normal (0.36 cm). Visualized peristalsis appears appropriate. There were no focal lesions consistent with obstruction or a mass effect observed.

WEIGHT

17.8 lbs

The ileocecal junction was visualized and exhibited normal intact wall layering and is subjectively of normal thickness. Sections of colon are visualized with formed fecal material and gas shadowing distally. There is no observed focal or generalized colon wall thickening or loss of layering.

INTERPRETED BY

Kathleen Sennello
DVM, MS, Diplomate
ACVIM (Small Animal
Internal Medicine)

Pancreas

The pancreas is normal and isoechoic to surrounding mesentery. There is no evidence of nodules or cystic lesions. There is no evidence of regional mesenteric inflammation or fluid.

IMAGING PERFORMED BY

Dr. Mengine

Free Abdomen

Evaluation of the peritoneal cavity did not reveal any evidence of effusion, or subjective lymphadenomegaly. The Medial iliac nodes appear normal and there was no evidence of a caudal aortic thrombus at the bifurcation. The omentum is of normal uniform echogenicity.

HOSPITAL NAME

Stoney Creek VH

ULTRASONOGRAPHIC FINDINGS

REFERRING VET

Dr. Mengine

PRIMARY FINDINGS:

Large, irregular, isoechoic liver mass. Findings favor a primary liver mass (benign or malignant). Measurements appear somewhat similar to the previous scan.

INVOICE

92029

Cystic calculi. I suspect there are at least two bladder stones present. I recommend abdominal radiographs to evaluate size and number of stones present.

DATE

9/28/21

Bilateral nephroliths and bilateral renal pyelectasia. Pyelectasia of the kidneys could be consistent with pyelonephritis, chronic renal disease, secondary to PU/PD or fluid therapy (if applicable), other. The stones visualized in the right kidney could be partially obstructive causing intermittent or mild



PATIENT pyelectasia.

Duncan Peppel Bilaterally decreased corticomedullary distinction in both kidneys. Mild loss of corticomedullary distinction in both kidneys could be consistent with chronic degenerative disease or interstitial nephrosis.

SPECIES

Canine

SECONDARY FINDINGS:

BREED Miniature Poodle
Moderate gallbladder sludge. The significance of the aggregated gallbladder debris is unclear. This could represent an early mucocele, cholestasis, or may be secondary to fasting.

SEX

Neutered male

INTERPRETATION OF THE FINDINGS & FURTHER RECOMMENDATIONS

AGE

14.8 years

The ultrasonographic findings visualized seem relatively static. It is difficult to accurately measure the hepatic mass due to its irregular shape. The changes in the kidneys are significant and there could be pyelonephritis or partial obstruction although the pyelectasia is relatively mild in both kidneys. Consider urinalysis, culture and blood pressure evaluation if not already performed.

WEIGHT

17.8 lbs

The bladder stones may be slightly larger than previously reported, but it is difficult to assess this with ultrasound and radiographs are much more adequate. Consider abdominal radiographs and thoracic radiographs to monitor. If the bladder stones are clinical consider cystotomy if surgical intervention for the hepatic mass is considered. I recommend CT scan for further evaluation.

INTERPRETED BY

Kathleen Sennello
DVM, MS, Diplomate
ACVIM (Small Animal
Internal Medicine)

IMAGING PERFORMED BY

Dr. Mengine

HOSPITAL NAME

Stoney Creek VH

REFERRING VET

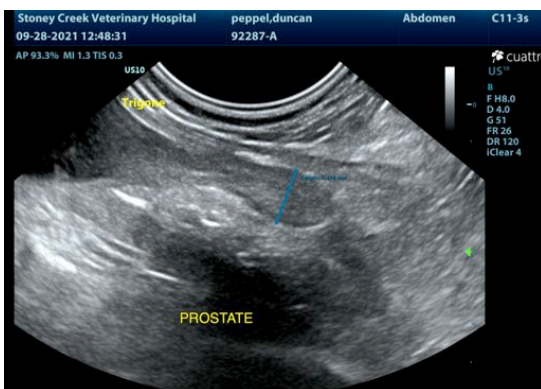
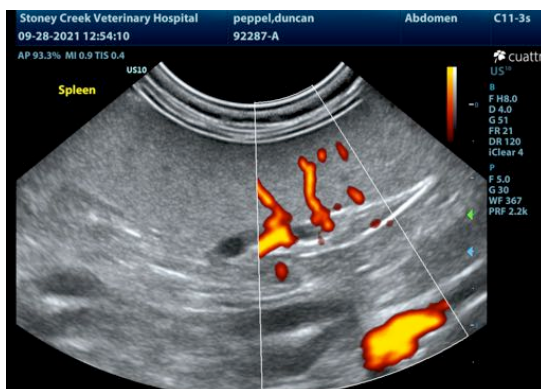
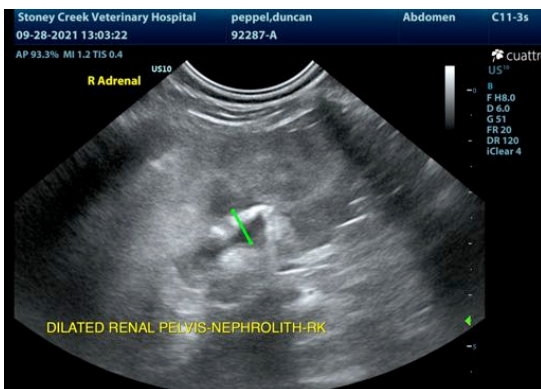
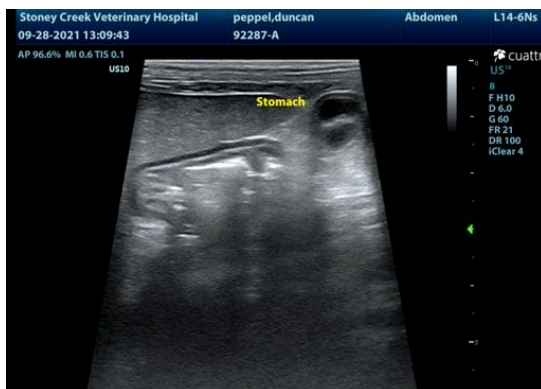
Dr. Mengine

INVOICE

92029

DATE

9/28/21





PATIENT

Duncan Peppel

SPECIES

Canine

BREED

Miniature Poodle

SEX

Neutered male

AGE

14.8 years

WEIGHT

17.8 lbs

INTERPRETED BY

Kathleen Sennello
DVM, MS, Diplomate
ACVIM (Small Animal
Internal Medicine)

IMAGING PERFORMED BY

Dr. Mengine

HOSPITAL NAME

Stoney Creek VH

REFERRING VET

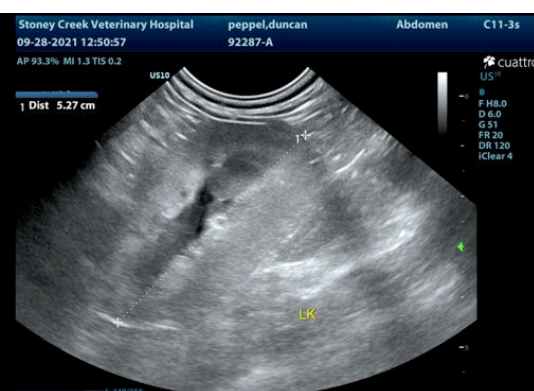
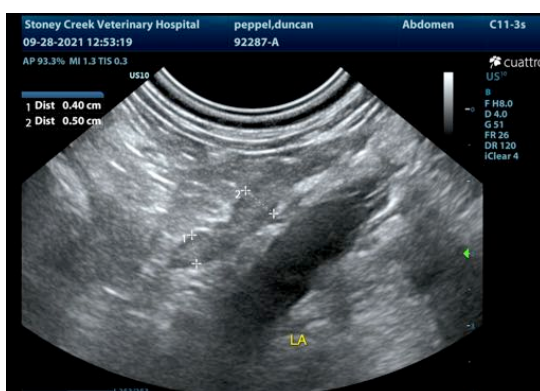
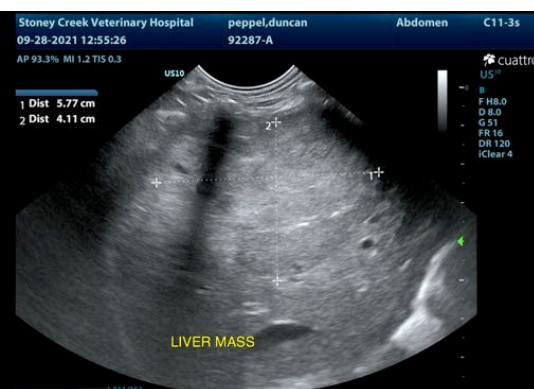
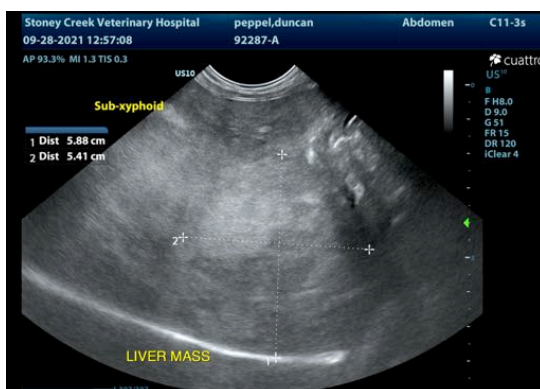
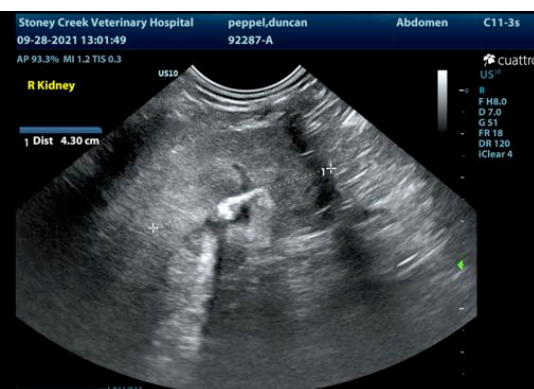
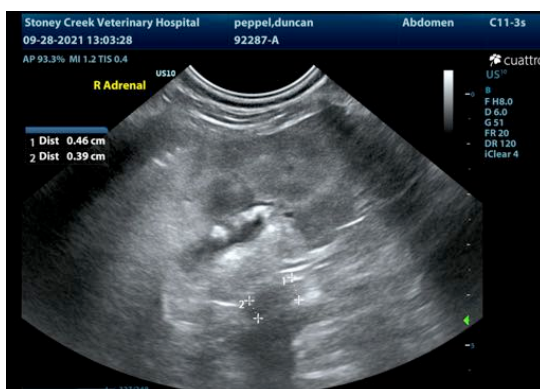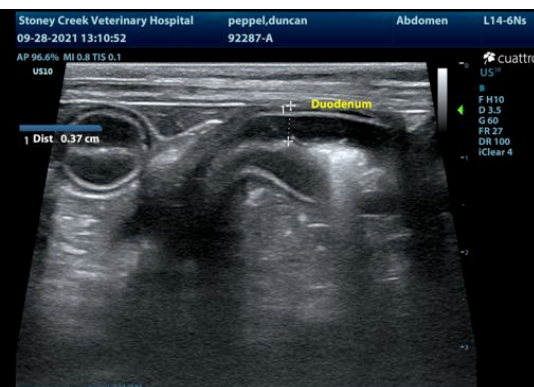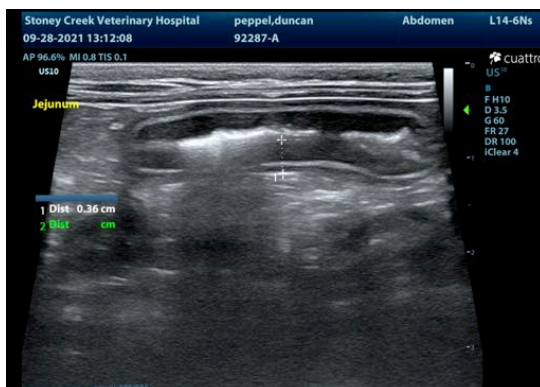
Dr. Mengine

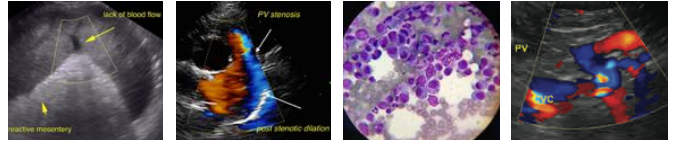
INVOICE

92029

DATE

9/28/21





PATIENT

Duncan Peppel

SPECIES

Canine

BREED

Miniature Poodle

SEX

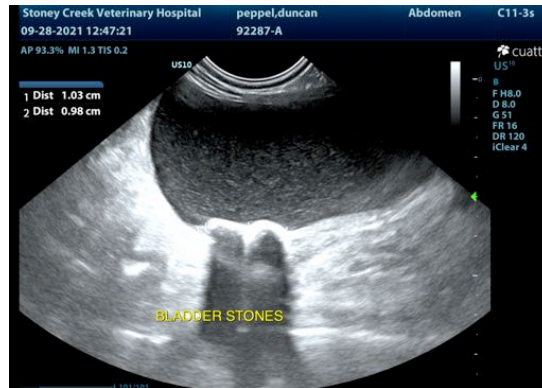Neutered male

AGE

14.8 years

WEIGHT

17.8 lbs



The information and recommendations provided are based on the images presented by the referring veterinarian. No evaluation can be communicated regarding pathology that was not visible in the image/video clips provided.

Thank you for this referral. If the clinical or image interpretation does not parallel your findings or if I can be of any further assistance please contact me.

Kathleen Sennello DVM,MS, Diplomate ACVIM (Small animal Internal Medicine)
kathleen.sennello@sonopath.com

INTERPRETED BY

Kathleen Sennello
DVM, MS, Diplomate
ACVIM (Small Animal
Internal Medicine)

IMAGING PERFORMED BY

Dr. Mengine

HOSPITAL NAME

Stoney Creek VH

REFERRING VET

Dr. Mengine

INVOICE

92029

DATE

9/28/21