



**PATIENT**

Barney Laurenz

**SPECIES**

Canine

**BREED**

Chihuahua X

**SEX**

Neutered Male

**AGE**

6 Years

**WEIGHT**

18.3 Pounds

**INTERPRETED BY**

Kathleen Sennello DVM,  
MS, Diplomate ACVIM  
(Small Animal Internal  
Medicine)

**IMAGING  
PERFORMED BY**

Dr. Sheldon

**HOSPITAL NAME**

Advanced PetCare  
of Oakland

**REFERRING VET**

Dr. Sheldon

**INVOICE**

41686

**DATE**

9/27/22

**PRESENTING CLINICAL SIGNS**

Pet had mildly elevated ALT noted on preanesthetic bloodwork done. Pet has grade 1 heart murmur and some mild left atrial enlargement but is otherwise healthy.

**ULTRASONOGRAPHIC EXAMINATION OF THE ABDOMEN**

**Urinary System**

The urinary bladder is moderately distended with anechoic urine. The Bladder wall, trigone, ureteral papillae and visible urethra (to a depth of 2cm) appear normal with no evidence of wall thickening, mucosal irregularities, masses or cystic calculi.

The visualized areas of prostate and surrounding tissue appear normal. Unfortunately, the prostate is not fully visualized likely due to its intrapelvic location. Correlate with rectal exam findings.

The left kidney has a normal shape and size (5. Overall echogenicity is normal with adequate corticomedullary distinction and a typical 1:3 cortex:medulla ratio. There is no evidence of focal perinephric inflammation or effusion. There is no evidence of pyelectasia, nephroliths, infarcts or hydroureter. Renal vasculature is normal.

The right kidney has a normal shape and size (5.19 cm). Overall echogenicity is normal with adequate corticomedullary distinction and a typical 1:3 cortex:medulla ratio. There is no evidence of focal perinephric inflammation or effusion. There is no evidence of pyelectasia, nephroliths, infarcts or hydroureter. Renal vasculature is normal.

**Adrenal Glands**

The left adrenal gland is normal in size measuring 0.35 cm at the caudal pole. It is observed in its normal position cranial to the left renal artery. It is normal in appearance (uniformly hypoechoic) and shape with no evidence of a mass effect.

The right adrenal gland is normal in size measuring 0.44 cm at the caudal pole. It is observed in its normal position between the cranial aspect of the right kidney and the caudal vena cava. It is normal in appearance (uniformly hypoechoic) and shape with no evidence of a mass effect.

**Spleen**

The spleen is subjectively normal in size, echotexture is homogenous, and the splenic capsule is smooth with no irregularities. The blood flow through the hilus and splenic parenchyma appears normal. No focal parenchymal abnormalities are visualized.

**Liver**

The liver is large in size, and normal in echogenicity with smooth peripheral margins. The parenchyma is heterogenous in echotexture with subtle, indistinct focal mottling. The visible portions of the vasculature and biliary tract appear normal. No focal nodules or cystic lesions are observed.

The gall bladder lumen is significantly distended. Some areas of the wall appear mildly thickened with adherent debris. There is a large amount of primarily non-organized echogenic debris. There is no evidence of bile duct dilation.



**PATIENT**

**Gastrointestinal**

Barney Laurenz

The stomach contains minimal luminal contents. It measures at a normal thickness of <0.7cm with some variability due to the presence of rugal folds. The distinction of the gastric wall layers is adequate and there is no impression of reduced peristaltic activity. No masses or focal lesions were observed.

**SPECIES**

Canine

The visualized areas of duodenum, jejunum and ileum have a relatively uniform diameter with minimal fluid distension. Wall thickness is normal. Bowel loops follow a curvilinear path with distinct wall layering maintaining the typical 1:3 muscularis:mucosa layer ratio. The duodenum measured as normal (between 0.3-0.5cm in wall thickness) and the jejunum measured as normal (between 0.2-0.47cm.)

**BREED**

Chihuahua X

Visualized peristalsis appears appropriate. There were no focal lesions consistent with obstruction or a mass effect observed.

**SEX**

Neutered Male

The ileocecal junction was visualized and exhibited normal intact wall layering and is subjectively of normal thickness. Sections of colon are visualized with formed fecal material and gas shadowing distally. There is no observed focal or generalized colon wall thickening or loss of layering.

**Pancreas**

**AGE**

6 Years

The pancreas is normal and isoechoic to surrounding mesentery. There is no evidence of nodules or cystic lesions. There is no evidence of regional mesenteric inflammation or fluid.

**Free Abdomen**

**WEIGHT**

18.3 Pounds

Evaluation of the peritoneal cavity did not reveal any evidence of effusion, or subjective lymphadenomegaly. The Medial iliac nodes appear normal and there was no evidence of a caudal aortic thrombus at the bifurcation. The omentum is of normal uniform echogenicity.

**ULTRASONOGRAPHIC FINDINGS**

**INTERPRETED BY**

Kathleen Sennello DVM,  
MS, Diplomate ACVIM  
(Small Animal Internal  
Medicine)

- Large, heterogeneous liver – A large amount of debris is evident in the gall bladder with no evidence of a mucocele or associated inflammation at this time. This could represent an early mucocele or cholestasis, with minimal evidence of associated inflammation at this time. Continued monitoring of labwork and ultrasound are warranted for progression of this lesion. Ursodiol therapy could be considered.

**IMAGING PERFORMED BY**

Dr. Sheldon

**INTERPRETATION OF THE FINDINGS & FURTHER RECOMMENDATIONS**

No focal lesions are visualized associated with the liver. The gallbladder has a large amount of debris, and some of this is starting to adhere to the gallbladder wall, but there is no significant mucocele development at this time. Findings are most suggestive of a primary hepatopathy, although treatment with Ursodiol and continued monitoring of the gallbladder is warranted. Consider the following:

**HOSPITAL NAME**

Advanced PetCare  
of Oakland

- Consider close evaluation of history for possible toxic changes examine medications, diet, dietary indiscretion etc...

**REFERRING VET**

Dr. Sheldon

- Consider PCR on urine/serum for leptospirosis (if not on antibiotics)/serology if recent antibiotic history

- If not already done, consider pre and post prandial bile acids to evaluate liver function

**INVOICE**

41686

- Consider Fine needle aspirate if round cell neoplasia is on your differentia list (25 g needle, normal coags)

**DATE**

9/27/22

- If no response to supportive care (Denamarin, fluids, antibiotics, +/- ursodiol etc.) Consider liver biopsy with samples obtained for histopathology, culture, and copper levels.



**PATIENT**

Barney Laurenz

**SPECIES**

Canine

**BREED**

Chihuahua X

**SEX**

Neutered Male

**AGE**

6 Years

**WEIGHT**

18.3 Pounds

**INTERPRETED BY**

Kathleen Sennello DVM,  
MS, Diplomate ACVIM  
(Small Animal Internal  
Medicine)

**IMAGING  
PERFORMED BY**

Dr. Sheldon

**HOSPITAL NAME**

Advanced PetCare  
of Oakland

**REFERRING VET**

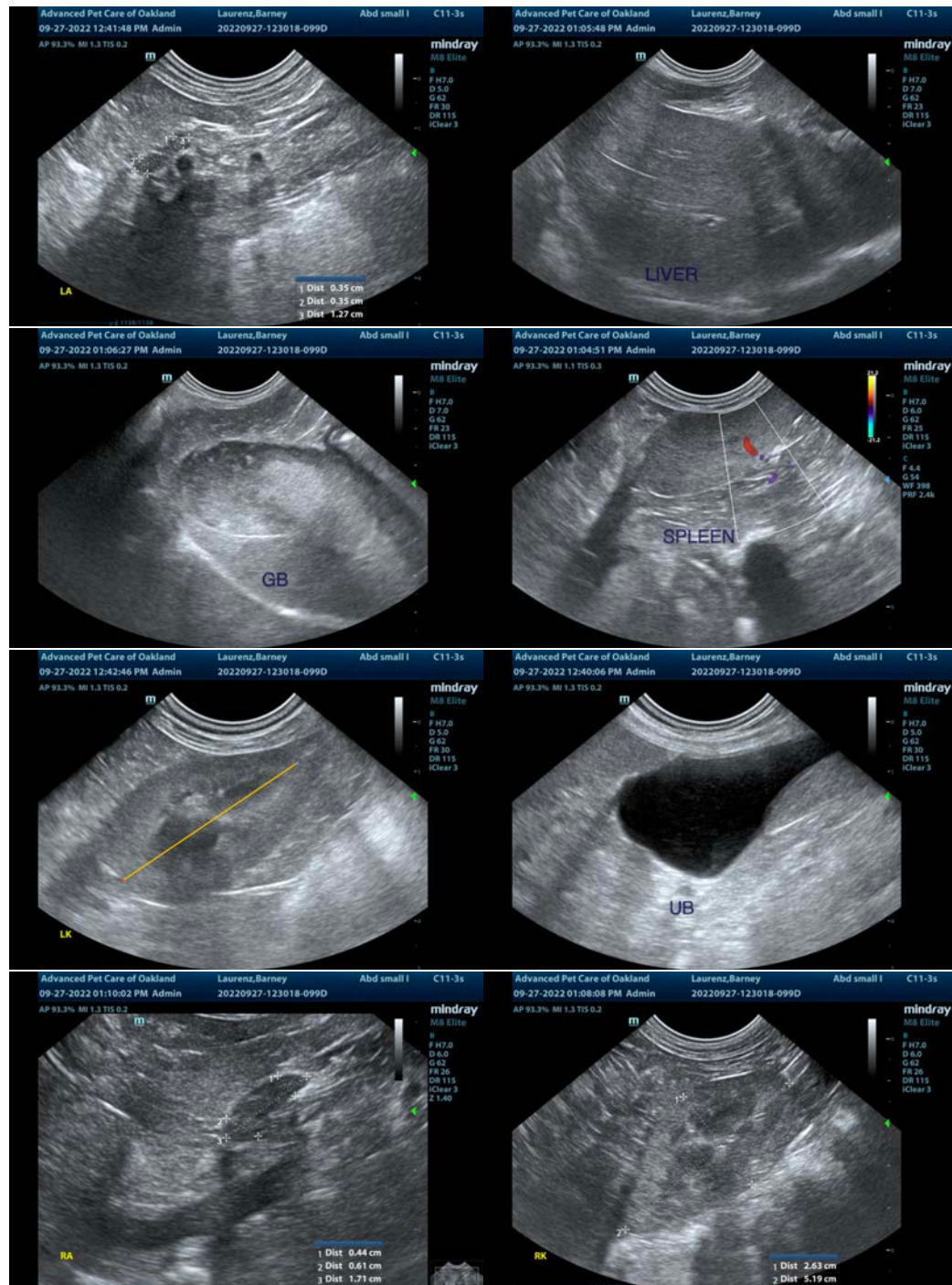
Dr. Sheldon

**INVOICE**

41686

**DATE**

9/27/22



The information and recommendations provided are based on the images presented by the referring veterinarian/sonographer. No evaluation can be communicated regarding pathology that was not visible in the image/video clips provided.

Thank you for this referral. If the clinical or image interpretation does not parallel your findings or if I can be of any further assistance please contact me.

Kathleen Sennello DVM,MS, Diplomate ACVIM (Small animal Internal Medicine)

kathleen.sennello@sonopath.com