

PATIENT

Addison Spoor

PRESENTING CLINICAL SIGNS

SPECIES

Canine

BREED

Cavachon

Chemistry screen: Increased BUN and creatinine. Increase ALT and alk phos, cholesterol and PSL. CBC: Slight increased eosinophils Heartworm test antigen: Negative Fecal: No eggs or parasites seen Urinalysis: Urinalysis low normal specific gravity. Total T4: Within normal limits Free T4 pending A: Hepatic versus hepatobiliary disease DDX: Idiopathic, infectious, inflammation, neoplasia, other. Suspect renal insufficiency. Rule out other pre-renal versus postrenal azotemia. Plan: Very concerned about multiorgan disease.

Abnormal PE/Chem/CBC/UA Results: ALT (SGPT) 160 H Alk Phosphatase 137 H BUN 37 H Crea 1.7 TRIGLYCERIDE 503 H PrecisionPSL 187 H

SEX

Spayed Female

AGE

14 Years

WEIGHT

14.12 Pounds

ULTRASONOGRAPHIC EXAMINATION OF THE ABDOMEN

Urinary System

The urinary bladder is moderately distended with anechoic urine. The Bladder wall, trigone, ureteral papillae and visible urethra (to a depth of 2cm) appear normal with no evidence of wall thickening, mucosal irregularities, masses or cystic calculi.

The left kidney has a normal shape and size (3.31 cm) with numerous small cortical cysts, the largest of which measures 0.30 cm and pyelectasia at 0.53 cm. Overall echogenicity is slightly hyperechoic with poor corticomedullary distinction and a typical 1:3 cortex:medulla ratio. There is no evidence of focal perinephric inflammation or effusion. There is no evidence of nephroliths, infarcts or hydroureter. Renal vasculature is normal.

The right kidney has a normal shape and size (3.81 cm) with pyelectasia at 0.33 cm. Overall echogenicity is slightly hyperechoic with poor corticomedullary distinction and a typical 1:3 cortex:medulla ratio. There is no evidence of focal perinephric inflammation or effusion. There is no evidence of nephroliths, infarcts or hydroureter. Renal vasculature is normal.

Adrenal Glands

The left adrenal gland is normal in size measuring 0.45 cm at the caudal pole. It is observed in its normal position cranial to the left renal artery. It is normal in appearance (uniformly hypoechoic) and shape with no evidence of a mass effect.

The right adrenal gland is normal in size measuring 0.42 cm at the caudal pole. It is observed in its normal position between the cranial aspect of the right kidney and the caudal vena cava. It is normal in appearance (uniformly hypoechoic) and shape with no evidence of a mass effect.

Spleen

The spleen is subjectively normal in size, echotexture is homogenous, and the splenic capsule is smooth with no irregularities. The blood flow through the hilus and splenic parenchyma appears normal. No focal parenchymal abnormalities are visualized.

Liver

The liver is subjectively normal in size, and echogenicity with smooth peripheral margins. The parenchyma is homogenous echotexture. The visible portions of the vasculature and biliary tract appear normal. No focal nodules or cystic lesions are observed.

INTERPRETED BY

Kathleen Sennello DVM,
MS, Diplomate ACVIM
(Small Animal Internal
Medicine)

IMAGING BY

Loetitia Saint-Jacques,
LVT

HOSPITAL NAME

South Reno VH

REFERRING VET

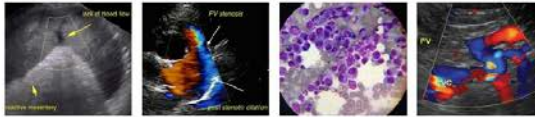
Dr. Schmitt

INVOICE

41704

DATE

9/27/22



PATIENT

Addison Spoor The gallbladder lumen is moderately distended. The wall of the gall bladder is not thickened and has a smooth mucosal surface. Luminal contents are mild and primarily anechoic. The cystic and common bile ducts are normal/not visible.

SPECIES

Canine

Gastrointestinal

The stomach contains minimal luminal contents. It measures at a normal thickness of <0.7cm with some variability due to the presence of rugal folds. The distinction of the gastric wall layers is adequate and there is no impression of reduced peristaltic activity. No masses or focal lesions were observed.

BREED

Cavachon

The visualized areas of duodenum, jejunum and ileum have a uniform diameter with minimal fluid distension. Wall thickness is moderately increased. Bowel loops follow a typical curvilinear path. Some areas have reduced detail of wall layering. Duodenum wall measures 0.40 cm. Jejunum wall measures 0.32 cm. There are some areas of mucosal speckling visualized. Visualized peristalsis appears appropriate. There were no focal lesions consistent with obstruction or a mass effect observed.

SEX

Spayed Female

AGE

14 Years

The ileocecal junction was visualized and exhibited normal intact wall layering and is subjectively of normal thickness. Sections of colon are visualized with formed fecal material and gas shadowing distally. There is no observed focal or generalized colon wall thickening or loss of layering.

WEIGHT

14.12 Pounds

Pancreas

The pancreas is prominent and hypoechoic as compared to the surrounding isoechoic mesentery. There is no evidence of nodules or cystic lesions. There is no evidence of regional mesenteric inflammation or fluid.

Free Abdomen

Evaluation of the peritoneal cavity did not reveal any evidence of effusion, or subjective lymphadenomegaly. The Medial iliac nodes appear normal and there was no evidence of a caudal aortic thrombus at the bifurcation. The omentum is of normal uniform echogenicity.

INTERPRETED BY

Kathleen Sennello DVM,
MS, Diplomate ACVIM
(Small Animal Internal
Medicine)

ULTRASONOGRAPHIC FINDINGS

IMAGING BY

Loetitia Saint-Jacques,
LVT

- Decreased corticomedullary distinction in both kidneys with bilateral pyelectasia – The bilateral renal findings are consistent with age-related change. Pyelectasia of the kidney(s) could be consistent with pyelonephritis, chronic renal disease, secondary to PU/PD or fluid therapy (if applicable), other.

HOSPITAL NAME

South Reno VH

- Hypoechoic, prominent pancreas – The pancreatic changes are most consistent with age-related parenchymal remodeling, potentially secondary to a prior inflammatory episode, early fibrosis or chronic pancreatitis.

REFERRING VET

Dr. Schmitt

- Subjectively thickened small intestine with mild mucosal speckling – Bright mucosal speckling has been postulated to represent dilated lacteals or focal accumulations of mucus, cellular debris, etc.. in the mucosal crypts.

INTERPRETATION OF THE FINDINGS & FURTHER RECOMMENDATIONS

INVOICE

41704

There are no focal lesions visualized associated with the liver or gallbladder. Consider a liver

DATE

9/27/22



PATIENT

Addison Spoor function test. If that is normal, then recommend continued monitoring of the ALT. If it continues to rise, you could consider a fine needle aspirate (as long as clotting parameters are normal).

SPECIES

Canine The changes visualized with the kidneys are likely associated with age related change. There is bilateral pyelectasia present with no evidence of obstruction. Recommend a urinalysis, culture, and blood pressure evaluation, and continued monitoring of the kidneys.

BREED

Cavachon The changes observed in the pancreas are likely consistent with previous episodes of pancreatic inflammation and age related remodeling.

SEX

Spayed Female There is mild mucosal speckling visualized associated with the gastrointestinal tract. If there is no history of GI upset, then the significance of this is unclear. If this patient has a history of a sensitive stomach, etc., there could be evidence of underlying GI disease.

AGE

14 Years

WEIGHT

14.12 Pounds

INTERPRETED BY

Kathleen Sennello DVM,
MS, Diplomate ACVIM
(Small Animal Internal
Medicine)

IMAGING BY

Loetitia Saint-Jacques,
LVT

HOSPITAL NAME

South Reno VH

REFERRING VET

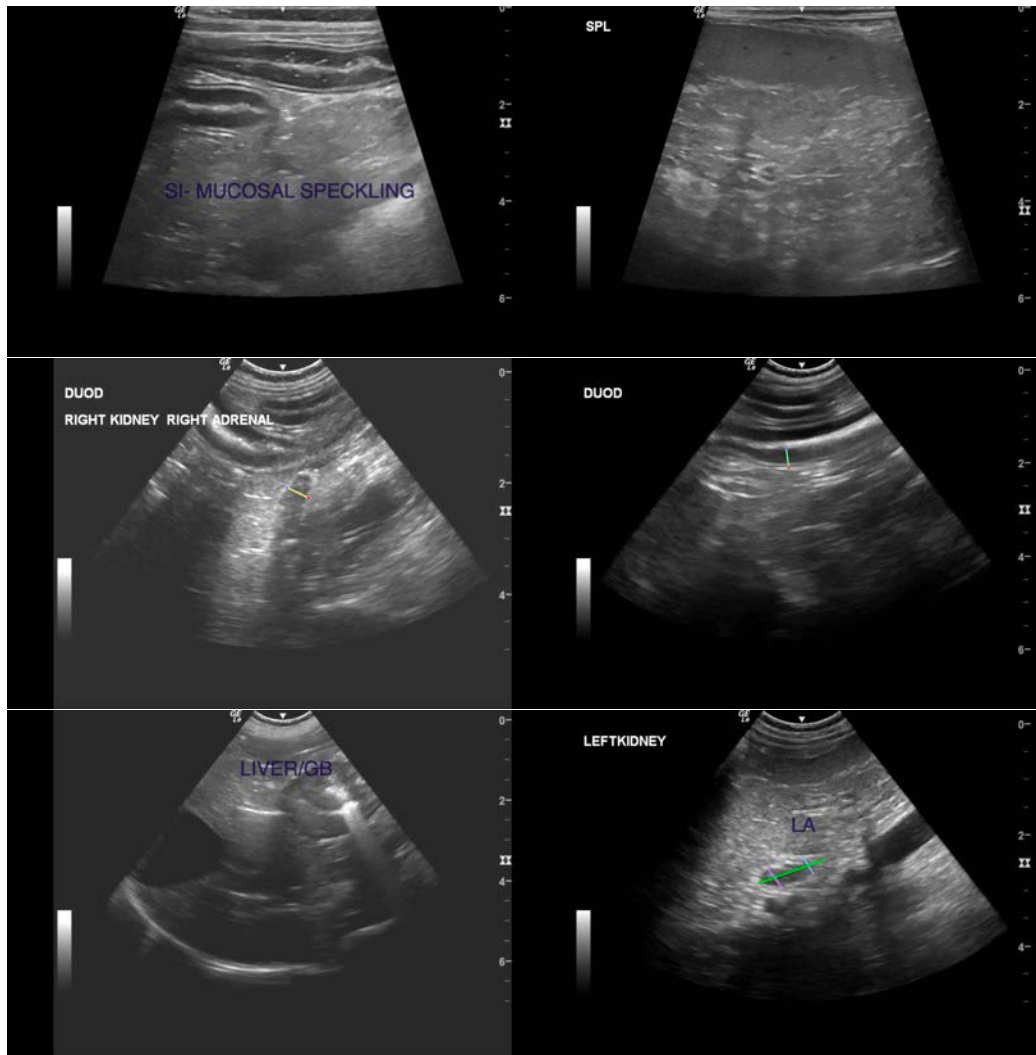
Dr. Schmitt

INVOICE

41704

DATE

9/27/22





PATIENT

Addison Spoor

SPECIES

Canine

BREED

Cavachon

SEX

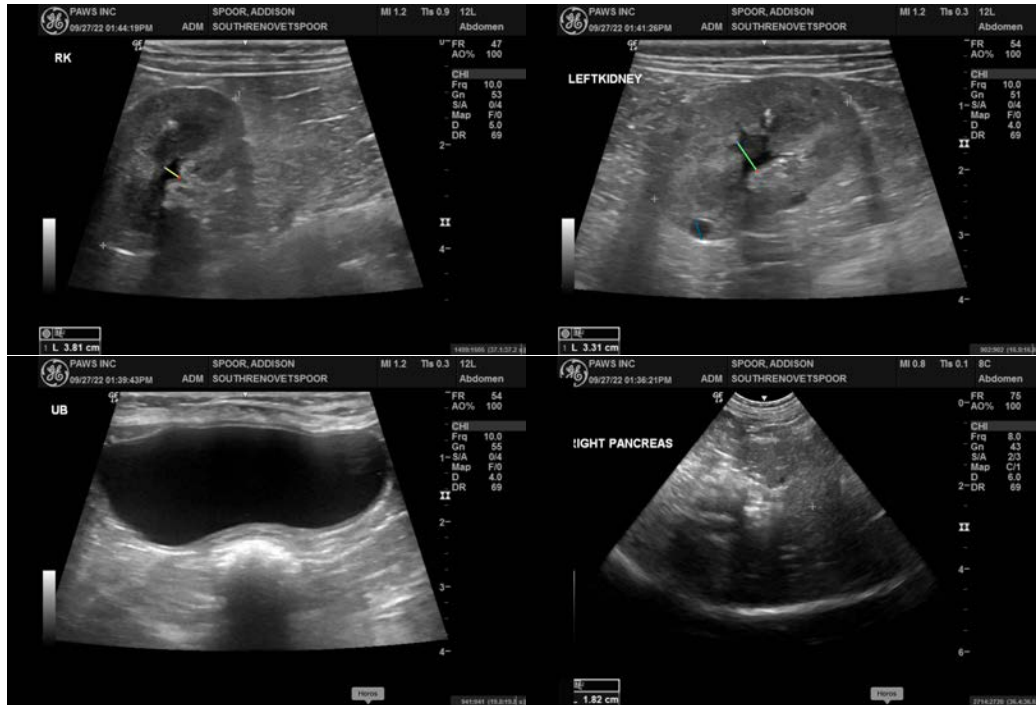
Spayed Female

AGE

14 Years

WEIGHT

14.12 Pounds



The information and recommendations provided are based on the images presented by the referring veterinarian/sonographer. No evaluation can be communicated regarding pathology that was not visible in the image/video clips provided.

INTERPRETED BY

Kathleen Sennello DVM,
MS, Diplomate ACVIM
(Small Animal Internal
Medicine)

Thank you for this referral. If the clinical or image interpretation does not parallel your findings or if I can be of any further assistance please contact me.

Kathleen Sennello DVM,MS, Diplomate ACVIM (Small animal Internal Medicine)
kathleen.sennello@sonopath.com

IMAGING BY

Loetitia Saint-Jacques,
LVT

HOSPITAL NAME

South Reno VH

REFERRING VET

Dr. Schmitt

INVOICE

41704

DATE

9/27/22