

IMAGING PERFORMED BY

IntraPet.com



SonoPath

Clinical Sonography & Telecytology

EDUCATIONAL TELECONSULTATION SERVICES™

1-800-838-4268 info@sonopath.com SonoPath.com

DATE PRESENTING CLINICAL SIGNS

9/23/22 Liver values- little to no improvement after liver supplement.

PATIENT Current Medications: Denamarin.

Hailey White

Lab Results: ALKP 9/12/22 842, 8/4/22 886, 1/24/22 446, 12/8/20 632. ALT WNL.

Date of Previous IntraPet Ultrasound: No previous.

Sedation: Not required to complete full diagnostic ultrasound.

Stat Report: Not requested.

SPECIES

Canine

ULTRASONOGRAPHIC EXAMINATION OF THE ABDOMEN

BREED *Urinary System*

Retriever X

The urinary bladder is moderately distended with anechoic urine. The Bladder wall, trigone, ureteral papillae and visible urethra (to a depth of 2cm) appear normal with no evidence of wall thickening, mucosal irregularities, masses or cystic calculi.

SEX

Spayed Female

The left kidney has a normal shape and size (6.75 cm). Overall echogenicity is slightly hyperechoic with poor corticomedullary distinction and a typical 1:3 cortex:medulla ratio. There is no evidence of focal perinephric inflammation or effusion. There is no evidence of pyelectasia, nephroliths, infarcts or hydroureter. Renal vasculature is normal.

AGE

11/15/09

The right kidney has a normal shape and size (7.04 cm). Overall echogenicity is slightly hyperechoic with poor corticomedullary distinction and a typical 1:3 cortex:medulla ratio. There is no evidence of focal perinephric inflammation or effusion. There is no evidence of pyelectasia, nephroliths, infarcts or hydroureter. Renal vasculature is normal.

WEIGHT

81 Pounds

INTERPRETED BY

Kathleen Sennello DVM,
MS, Diplomate ACVIM
(Small Animal Internal
Medicine)

Adrenal Glands

The left adrenal gland is large measuring 2.1 cm at the cranial pole, 1.53 cm at the caudal pole, and 4.48 cm in length. It is observed in its normal position cranial to the left renal artery. It is somewhat atypical in appearance in that there is a subtle hyperechoic in the cranial pole measuring 1.6 cm, and a subtle hyperechoic nodule in the caudal pole measuring 1.17 cm.

IMAGING PERFORMED BY

Stephanie Warga
RDMS, RVT

The right adrenal gland is large, measuring 1.14 cm at the cranial pole, 0.98 cm at the caudal pole, and 3.14 cm in length. It is observed in its normal position between the cranial aspect of the right kidney and the caudal vena cava. It is normal in appearance (uniformly hypoechoic) and shape with no evidence of a mass effect.

HOSPITAL NAME

Banfield Abingdon

Spleen

The spleen is subjectively normal in size, echotexture is homogenous, and the splenic capsule is smooth with no irregularities. The blood flow through the hilus and splenic parenchyma appears normal. No focal parenchymal abnormalities are visualized.

REFERRING VET

Dr. Simpson

Liver

The liver is large in size, and normal in echogenicity with smooth peripheral margins. The parenchyma is heterogenous in echotexture with subtle, indistinct focal mottling. The visible portions of the vasculature and biliary tract appear normal. No focal nodules or cystic lesions are observed.

INVOICE

41597

The gallbladder lumen is moderately distended. The wall of the gall bladder is not thickened and has a smooth mucosal surface. Luminal contents are mild and primarily anechoic. The cystic and common bile ducts are normal/not visible.

Gastrointestinal

The stomach is moderately dilated with fluid and irregular shadowing material most consistent with normal ingesta and gas. It measures at a normal thickness of <0.7cm with some variability due to the presence of rugal folds. The distinction of the gastric wall layering is adequate and there is no impression of reduced peristaltic activity. No masses or focal lesions were observed.

The visualized areas of duodenum, jejunum and ileum have a relatively uniform diameter with minimal fluid distension. Wall thickness is normal. Bowel loops follow a curvilinear path with distinct wall layering maintaining the typical 1:3 muscularis:mucosa layer ratio. Duodenum wall measures 0.37 cm. Jejunum wall measures 0.32 cm. Visualized peristalsis appears appropriate. There were no focal lesions consistent with obstruction or a mass effect observed.

The ileocecal junction was visualized and exhibited normal intact wall layering and is subjectively of normal thickness. Sections of colon are visualized with formed fecal material and gas shadowing distally. There is no observed focal or generalized colon wall thickening or loss of layering.

Pancreas

The pancreas is normal and isoechoic to surrounding mesentery. There is no evidence of nodules or cystic lesions. There is no evidence of regional mesenteric inflammation or fluid.

Free Abdomen

Evaluation of the peritoneal cavity did not reveal any evidence of effusion, or subjective lymphadenomegaly. The Medial iliac nodes appear normal and there was no evidence of a caudal aortic thrombus at the bifurcation. The omentum is of normal uniform echogenicity.

Other

There is an isoechoic mass effect visualized in the left caudal abdomen, caudal to the left kidney. This mass lesion measures approximately 6.59 cm x 14.7 cm. Tissue may be consistent with fat opacity.

ULTRASONOGRAPHIC FINDINGS

- Large nodular left adrenal gland and large right adrenal gland – The bilateral adrenomegaly could be consistent with bilateral hyperplasia (e.g., secondary to pituitary-dependent hyperadrenocorticism), bilateral infiltrative neoplasia, inflammatory adrenal disease, other. Correlation with clinical findings is recommended. The significance of the nodules in the left adrenal gland is uncertain. This could represent hyperplasia or early neoplastic lesions.
- Decreased corticomedullary distinction in both kidneys – The bilateral renal findings are consistent with age-related change.
- Large, heterogeneous liver – The diffuse hepatic changes are non-specific and could be consistent with vacuolar hepatopathy, nodular hyperplasia, inflammatory/immune-mediated disease, fibrosis, extramedullary hematopoiesis, toxic hepatopathy (e.g., copper), infiltrative neoplasia (less likely) or other hepatopathy.
- Large, isoechoic, solid left-sided caudal abdominal mass – An association with other structures is not visualized. Consider the possibility of an intraabdominal lipoma. Recommend a fine needle aspirate.

INTERPRETATION OF THE FINDINGS & FURTHER RECOMMENDATIONS

Both adrenal glands are large. The left adrenal gland is somewhat nodular. These changes could be consistent with pituitary dependent hyperadrenocorticism with an atypical left adrenal, or there could be concurrent pituitary dependent hyperadrenocorticism with left adrenal nodules, which could be benign or neoplasia.

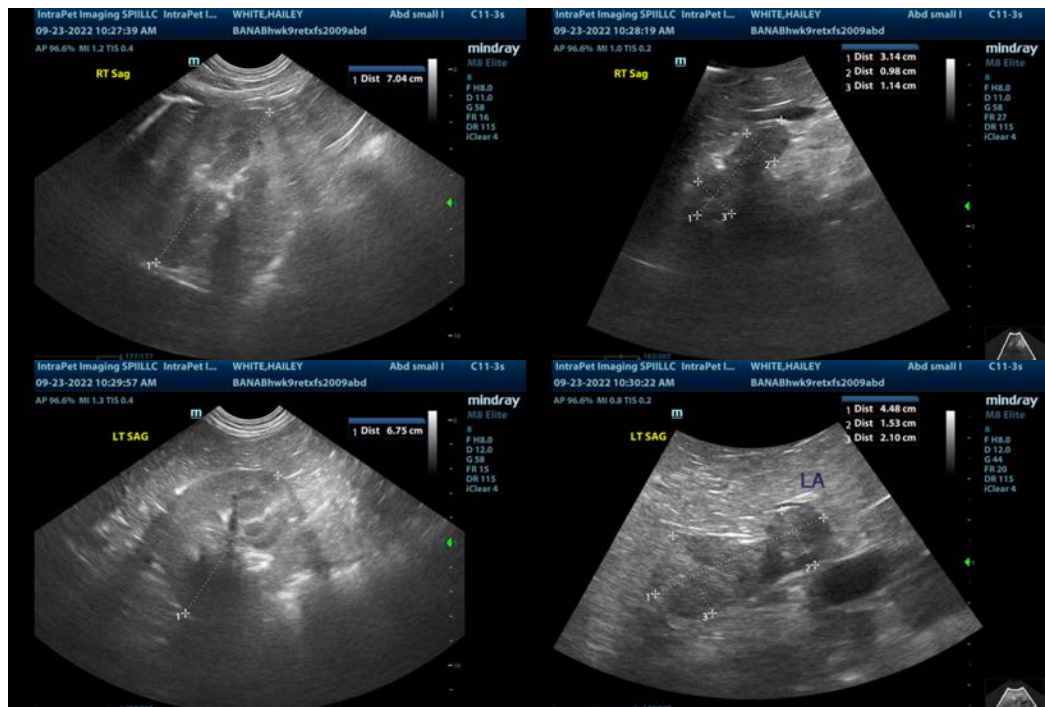
Differentiation of these processes is very difficult without histopathology of the adrenal glands. Recommend a blood pressure evaluation. If there is significant hypertension, I would consider measuring catecholamine levels, looking for a pheochromocytoma. Otherwise, if there are signs of Cushing's present, I would consider adrenal function testing and possible treatment for pituitary dependent hyperadrenocorticism if clinically appropriate. Recommend continued monitoring of the left adrenal gland.

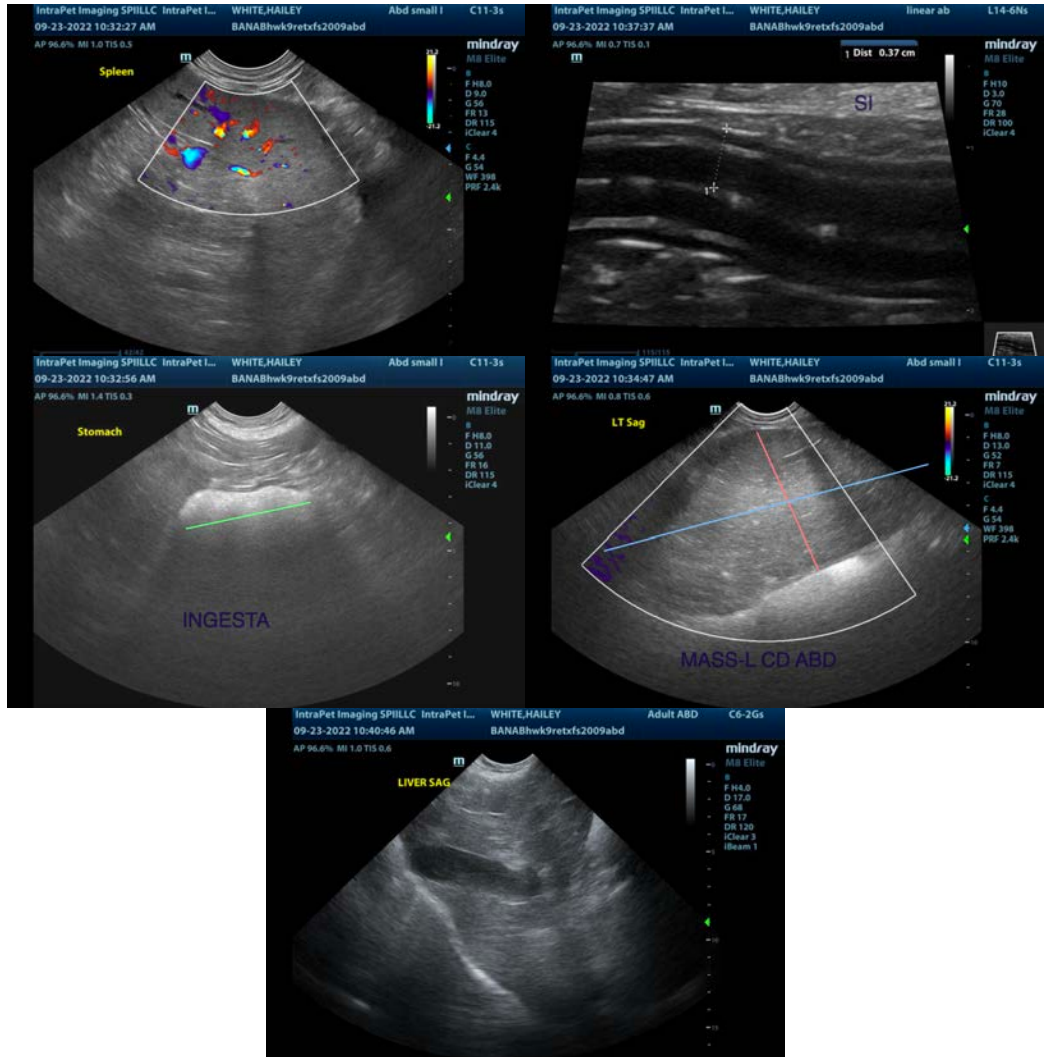
The liver is large and heterogeneous. These changes are most consistent with a vacuolar hepatopathy or steroid hepatopathy.

There is a large, solid, isoechoic mass lesion visualized caudal to the left kidney. Correlate these findings with abdominal radiographs, as this could be consistent with an intraabdominal lipoma. Recommend a fine needle aspirate of this lesion to further evaluate.

If this is thought to be causing clinical signs, I would consider a contrast CT scan of the abdomen to evaluate for possible surgical removal. If cytology is indicative of a different type of mass lesion, I would similarly recommend a contrast CT scan prior to considering surgical removal.

Recommend three view thoracic radiographs to evaluate for possible concurrent thoracic disease/involvement.





The information and recommendations provided are based on the images presented by the referring veterinarian/sonographer. No evaluation can be communicated regarding pathology that was not visible in the image/video clips provided.

Thank you for this referral. If the clinical or image interpretation does not parallel your findings or if I can be of any further assistance please contact me.

Kathleen Sennello DVM,MS, Diplomate ACVIM (Small animal Internal Medicine)
 kathleen.sennello@sonopath.com