



PATIENT

Stella Jeane Seagraves

SPECIES

Canine

BREED

Yorkshire Terrier

SEX

Spayed Female

AGE

6.5 Years

WEIGHT

9.6 Pounds

INTERPRETED BY

Kathleen Sennello DVM,
MS, Diplomate ACVIM
(Small Animal Internal
Medicine)

**IMAGING
PERFORMED BY**

Dr. Tam Mengine

HOSPITAL NAME

Stoney Creek VH

REFERRING VET

Dr. Tam Mengine

INVOICE

25770

DATE

9/23/21

PRESENTING CLINICAL SIGNS

Patient had vaccines with technician on 9/21, with benadryl pre-med. Patient was seen 9/22 for pain and inappetence - pain localized to cranial abdomen - client declined diagnostics until today, when pet still seemed painful and lethargic, though now eating. Labwork pending

ULTRASONOGRAPHIC EXAMINATION OF THE ABDOMEN

Urinary System

The urinary bladder is moderately distended with anechoic urine. The Bladder wall, trigone, ureteral papillae and visible urethra (to a depth of 2cm) appear normal with no evidence of wall thickening, mucosal irregularities, masses or cystic calculi.

The left kidney has a normal shape and size (4.11 cm). Overall echogenicity is normal with adequate corticomedullary distinction and a typical 1:3 cortex:medulla ratio. There is no evidence of perinephric inflammation or effusion. There is no evidence of pyelectasia, nephroliths, infarcts or hydroureter. Renal vasculature is normal.

The right kidney has a normal shape and size (3.6 cm). Overall echogenicity is normal with adequate corticomedullary distinction and a typical 1:3 cortex:medulla ratio. There is no evidence of perinephric inflammation or effusion. There is no evidence of pyelectasia, nephroliths, infarcts or hydroureter. Renal vasculature is normal.

Adrenal Glands

The left adrenal gland is normal in size measuring 0.37 cm at the caudal pole. It is observed in its normal position cranial to the left renal artery. It is normal in appearance (uniformly hypoechoic) and shape with no evidence of a mass effect.

The right adrenal gland is normal in size measuring 0.34 cm at the caudal pole. It is observed in its normal position between the cranial aspect of the right kidney and the caudal vena cava. It is normal in appearance (uniformly hypoechoic) and shape with no evidence of a mass effect.

Spleen

The spleen is subjectively normal in size, echotexture is homogenous, and the splenic capsule is smooth with no irregularities. The blood flow through the hilus and splenic parenchyma appears normal. No focal parenchymal abnormalities are visualized.

Liver

The liver is subjectively normal in size, and echogenicity with smooth peripheral margins. The parenchyma is homogenous echotexture. The visible portions of the vasculature and biliary tract appear normal. No focal nodules or cystic lesions are observed.

The gall bladder lumen is moderately distended. The wall of the gall bladder is not thickened and has a smooth mucosal surface. There is a moderate amount of non-organized echogenic debris. The cystic and common bile ducts are normal/not visible.

Gastrointestinal

The stomach is moderately dilated with fluid and irregular shadowing material most consistent with normal ingesta and gas. It measures at a normal thickness of 0.42 cm, but considering the patient size, this appears subjectively thick with some variability due to the presence of rugal folds. The distinction of



PATIENT

Stella Jeane Seagraves

the gastric wall layering in some areas is mildly decreased, and there is no impression of reduced peristaltic activity. No masses or focal lesions were observed.

SPECIES

Canine

The visualized areas of duodenum, jejunum and ileum have a relatively uniform diameter with minimal fluid distension. Wall thickness is normal. Bowel loops follow a curvilinear path with distinct wall layering maintaining the typical 1:3 muscularis:mucosa layer ratio. Duodenum wall measured 0.36 cm. Jejunum wall measured 0.36 cm. Visualized peristalsis appears appropriate. There were no focal lesions consistent with obstruction or a mass effect observed.

BREED

Yorkshire Terrier

The ileocecal junction was visualized and exhibited normal intact wall layering and is subjectively of normal thickness (0.19 cm) Sections of colon are visualized with formed fecal material and gas shadowing distally. There is no observed focal or generalized colon wall thickening or loss of layering.

SEX

Spayed Female

Pancreas

The pancreas is normal and isoechoic to surrounding mesentery. There is no evidence of nodules or cystic lesions. There is no evidence of regional mesenteric inflammation or fluid.

AGE

6.5 Years

Free Abdomen

Evaluation of the peritoneal cavity did not reveal any evidence of effusion, or subjective lymphadenomegaly. The Medial iliac nodes appear normal and there was no evidence of a caudal aortic thrombus at the bifurcation. The omentum is of normal uniform echogenicity.

WEIGHT

9.6 Pounds

ULTRASONOGRAPHIC FINDINGS

- Moderate ingesta in the stomach with subjectively prominent gastric wall – The stomach wall thickening could be consistent with inflammation, edema, infiltrative neoplasia, imaging artifact due to rugal folds, other. Correlate findings with feeding history. If adequately fasted, consider such differentials as delayed gastric emptying time or partial obstruction (none observed).

INTERPRETED BY

Kathleen Sennello DVM,
MS, Diplomate ACVIM
(Small Animal Internal
Medicine)

INTERPRETATION OF THE FINDINGS & FURTHER RECOMMENDATIONS

No significant ultrasonographic lesions were observed to explain the cranial abdominal pain noted. Correlate with blood work findings and consider a quantitative PLI measurement, as sometimes pancreatitis is not immediately evident on ultrasound. Additionally, consider referred pain such as back or neck pain, as this can sometimes mimic abdominal pain.

HOSPITAL NAME

Stoney Creek VH

The stomach wall is questionably thickened. If GI signs persist despite symptomatic therapy for acute gastroenteritis, and labs are normal, you could consider upper GI endoscopy to further evaluate.

REFERRING VET

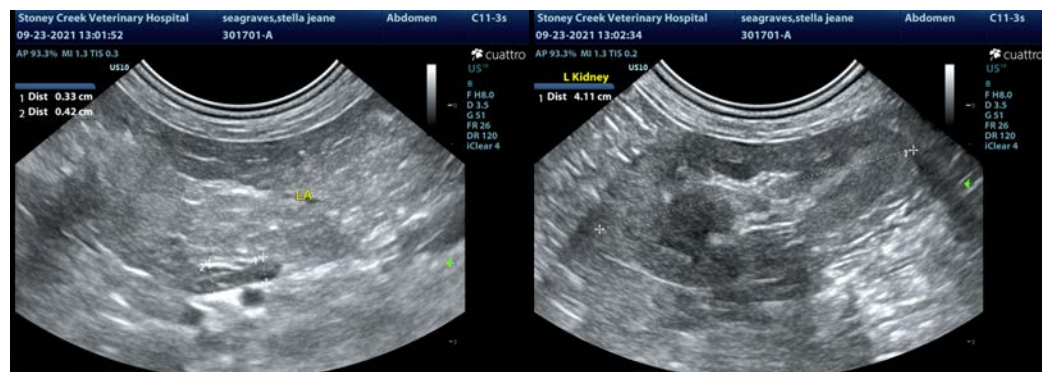
Dr. Tam Mengine

INVOICE

25770

DATE

9/23/21





PATIENT

Stella Jeane Seagraves

SPECIES

Canine

BREED

Yorkshire Terrier

SEX

Spayed Female

AGE

6.5 Years

WEIGHT

9.6 Pounds

INTERPRETED BY

Kathleen Sennello DVM,
MS, Diplomate ACVIM
(Small Animal Internal
Medicine)

**IMAGING
PERFORMED BY**

Dr. Tam Mengine

HOSPITAL NAME

Stoney Creek VH

REFERRING VET

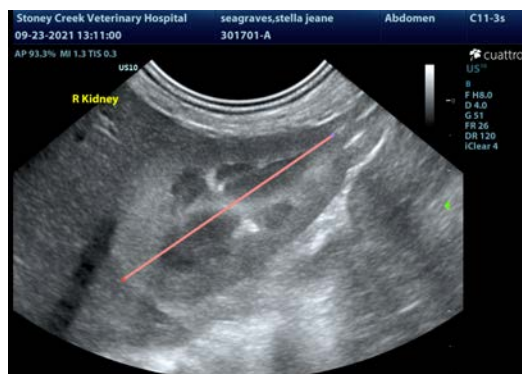
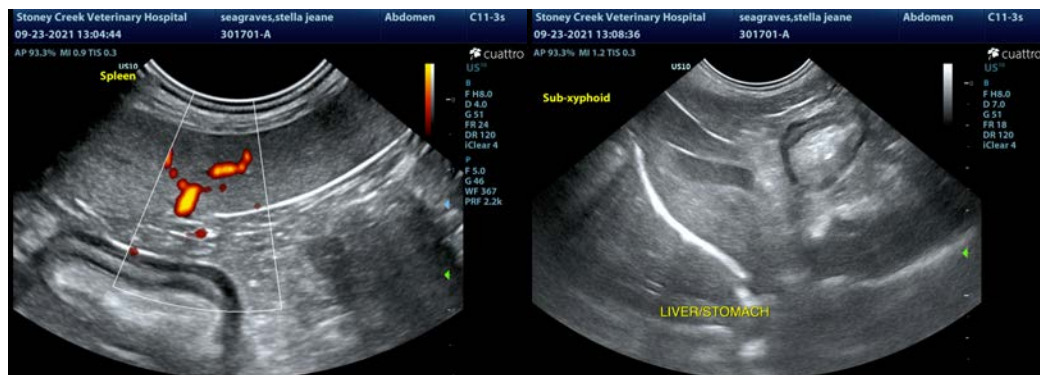
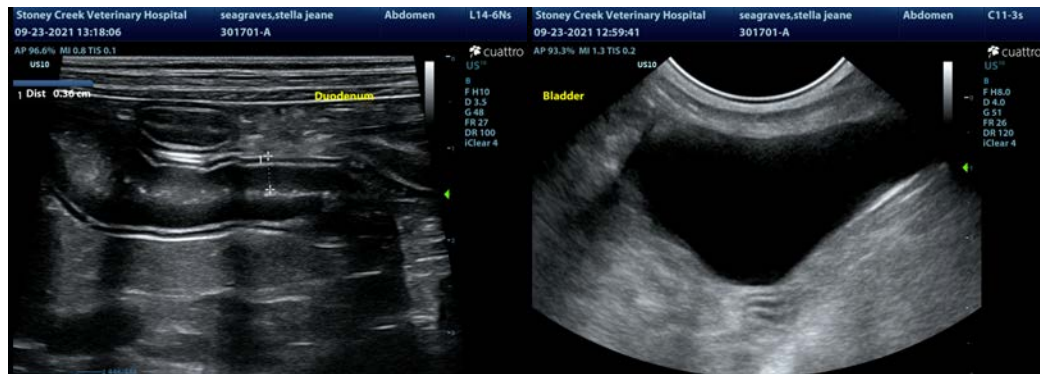
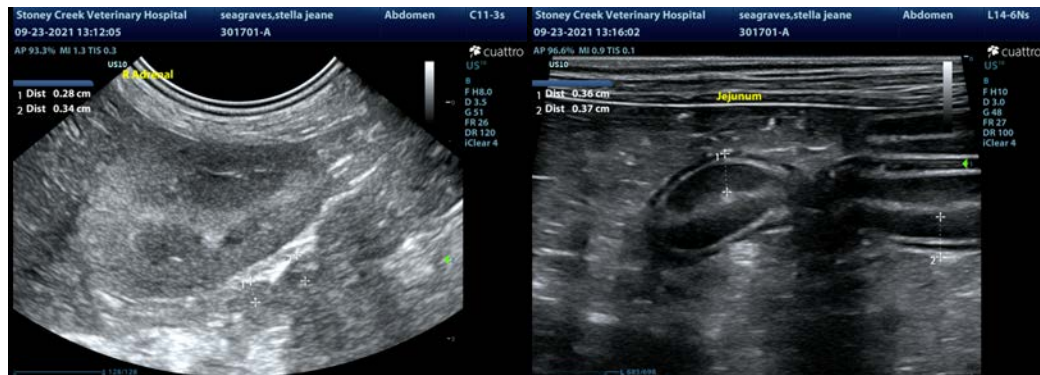
Dr. Tam Mengine

INVOICE

25770

DATE

9/23/21





PATIENT

Stella Jeane Seagraves

The information and recommendations provided are based on the images presented by the referring veterinarian. No evaluation can be communicated regarding pathology that was not visible in the image/video clips provided.

SPECIES

Canine

Thank you for this referral. If the clinical or image interpretation does not parallel your findings or if I can be of any further assistance please contact me.

BREED

Yorkshire Terrier

Kathleen Sennello DVM,MS, Diplomate ACVIM (Small animal Internal Medicine)
kathleen.sennello@sonopath.com

SEX

Spayed Female

AGE

6.5 Years

WEIGHT

9.6 Pounds

INTERPRETED BY

Kathleen Sennello DVM,
MS, Diplomate ACVIM
(Small Animal Internal
Medicine)

**IMAGING
PERFORMED BY**

Dr. Tam Mengine

HOSPITAL NAME

Stoney Creek VH

REFERRING VET

Dr. Tam Mengine

INVOICE

25770

DATE

9/23/21