

**PATIENT**

Mumble Chilcote

SPECIES

Feline

BREED

DSH

SEX

Neutered Male

AGE

2 Years

WEIGHT

7.38 Pounds

INTERPRETED BYKathleen Sennello DVM,
MS, Diplomate ACVIM
(Small Animal Internal
Medicine)**IMAGING PERFORMED BY**

Amy Mayhew, LVT

HOSPITAL NAME

SVS Imaging MI

REFERRING VETCat Care of
Rochester Hills**INVOICE**

41537

DATE

9/22/22

PRESENTING CLINICAL SIGNS

Presented for yearly PE; Mild weight loss/underweight Had SDMA >100 in June; rechecked in Sept- still >100 Unable to get UA at time of appt

Abnormal PE/Chem/CBC/UA Results: The ketones and urobili were neg when we rechecked them manually (really hate the Sedivue chem strip reader). Nothing noted on manual review of slide. USG >1.050 BP was 128 mmHg.

ULTRASONOGRAPHIC EXAMINATION OF THE ABDOMEN**Urinary System**

The urinary bladder is moderately distended with anechoic urine. The Bladder wall, trigone, ureteral papillae and visible urethra (to a depth of 2cm) appear normal with no evidence of wall thickening, mucosal irregularities, masses or cystic calculi.

The left kidney has a normal shape and size (3.8 cm). Overall echogenicity is normal with adequate corticomedullary distinction and a typical 1:3 cortex:medulla ratio. There is no evidence of focal perinephric inflammation or effusion. There is no evidence of pyelectasia, nephroliths, infarcts or hydroureter. Renal vasculature is normal.

The right kidney has a normal shape and size (4.0 cm). Overall echogenicity is normal with adequate corticomedullary distinction and a typical 1:3 cortex:medulla ratio. There is no evidence of focal perinephric inflammation or effusion. There is no evidence of pyelectasia, nephroliths, infarcts or hydroureter. Renal vasculature is normal.

Adrenal Glands

The left adrenal gland is normal in size measuring 0.30 cm at the caudal pole. It is observed in its normal position cranial to the left renal artery. It is normal in appearance (uniformly hypoechoic) and shape with no evidence of a mass effect.

The right adrenal gland is normal in size measuring 0.34 cm at the caudal pole. It is observed in its normal position between the cranial aspect of the right kidney and the caudal vena cava. It is normal in appearance (uniformly hypoechoic) and shape with no evidence of a mass effect.

Spleen

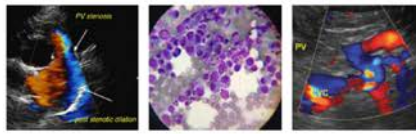
The spleen is subjectively normal in size (0.66 cm in width at the level of the hilus), echotexture is homogenous, and the splenic capsule is smooth with no irregularities. The blood flow through the hilus and splenic parenchyma appears normal. No focal parenchymal abnormalities are visualized.

Liver

The liver is subjectively normal in size, and echogenicity with smooth peripheral margins. The parenchyma is homogenous echotexture. The visible portions of the vasculature and biliary tract appear normal. No focal nodules or cystic lesions are observed.

The gallbladder lumen is moderately distended. The wall of the gall bladder is not thickened and has a smooth mucosal surface. Luminal contents are mild and primarily anechoic. The cystic and common bile duct appear slightly tortuous and dilated, measuring 0.28 cm.

Gastrointestinal

IMAGING PERFORMED BYSVS Mobile Imaging MI 734-637-7711
svsimagingmi@gmail.comEDUCATIONAL TELECONSULTATION SERVICES™
1-800-838-4268 info@sonopath.com SonoPath.com**PATIENT**

Mumble Chilcote

The stomach contains minimal luminal contents. It measures at a normal thickness of 0.30 cm with some variability due to the presence of rugal folds. The distinction of the gastric wall layers is adequate and there is no impression of reduced peristaltic activity. No masses or focal lesions were observed.

SPECIES

Feline

The visualized areas of duodenum, jejunum and ileum have a relatively uniform diameter with minimal fluid distension. Wall thickness is normal. Bowel loops follow a curvilinear path with distinct wall layering maintaining the typical 1:3 muscularis:mucosa layer ratio. Duodenum wall measures 0.29 cm. Jejunum wall measures 0.21 cm. Visualized peristalsis appears appropriate. There were no focal lesions consistent with obstruction or a mass effect observed.

BREED

DSH

The ileocecal junction was visualized and exhibited normal intact wall layering and is subjectively of normal thickness. Sections of colon are visualized with formed fecal material and gas shadowing distally. There is no observed focal or generalized colon wall thickening or loss of layering.

SEX

Neutered Male

Pancreas

The pancreas is normal and isoechoic to surrounding mesentery. There is no evidence of nodules or cystic lesions. There is no evidence of regional mesenteric inflammation or fluid.

AGE

2 Years

Free Abdomen

Evaluation of the peritoneal cavity did not reveal any evidence of effusion, or subjective lymphadenomegaly. The Medial iliac nodes appear normal and there was no evidence of a caudal aortic thrombus at the bifurcation. The omentum is of normal uniform echogenicity.

WEIGHT

7.38 Pounds

ULTRASONOGRAPHIC FINDINGS

- Mildly prominent/tortuous bile duct – Dilation of the common bile duct could be consistent with a functional obstruction (i.e. primary hepatic disease resulting in hepatocellular swelling) or with an extrahepatic bile duct obstruction (ie. choledocholith, bile duct tumor, pancreatic disease, other).

INTERPRETED BYKathleen Sennello DVM,
MS, Diplomate ACVIM
(Small Animal Internal
Medicine)**INTERPRETATION OF THE FINDINGS & FURTHER RECOMMENDATIONS**

Today's scan appears relatively normal. There is a mildly prominent bile duct but no obvious obstructive pattern, so the significance of this is unclear. There are no obvious lesions associated with the kidneys to explain the elevation in SDMA. Given how high the level is, I would be concerned for some degree of renal dysfunction but would also be concerned that there is some interference or error in the test. Some reports have seen falsely elevated values with neoplasia such as lymphoma and infections. Consider a urinalysis and culture and continued monitoring.

IMAGING PERFORMED BY

Amy Mayhew, LVT

HOSPITAL NAME

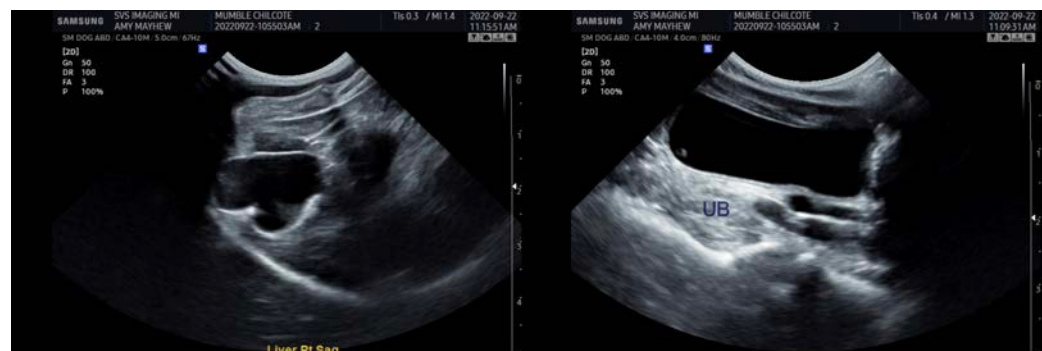
SVS Imaging MI

REFERRING VETCat Care of
Rochester Hills**INVOICE**

41537

DATE

9/22/22



IMAGING PERFORMED BY

SVS Mobile Imaging MI 734-637-7711
svsimagingmi@gmail.com



PATIENT

Mumble Chilcote

SPECIES

Feline

BREED

DSH

SEX

Neutered Male

AGE

2 Years

WEIGHT

7.38 Pounds

INTERPRETED BY

Kathleen Sennello DVM,
MS, Diplomate ACVIM
(Small Animal Internal
Medicine)

IMAGING PERFORMED BY

Amy Mayhew, LVT

HOSPITAL NAME

SVS Imaging MI

REFERRING VET

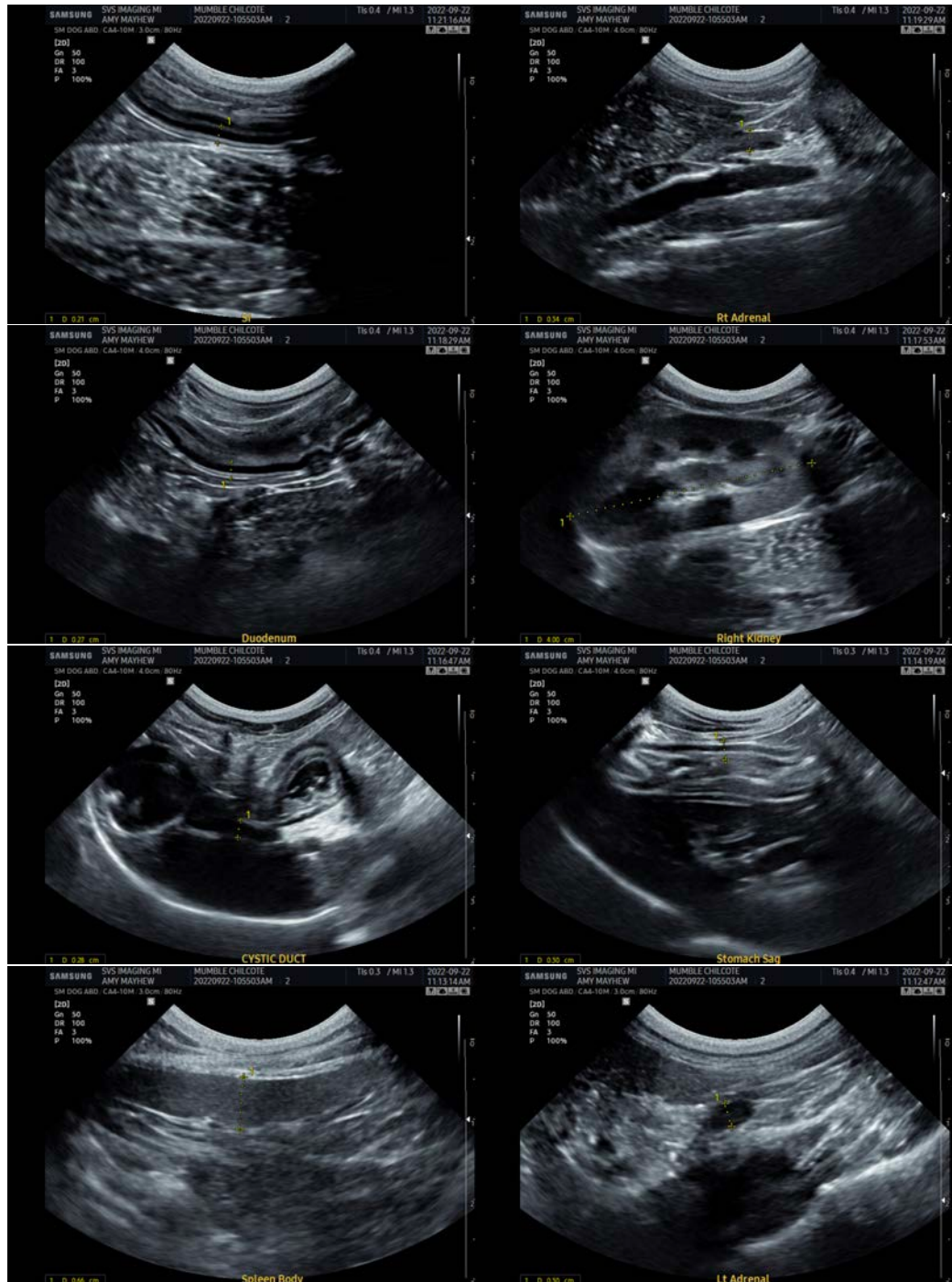
Cat Care of
Rochester Hills

INVOICE

41537

DATE

9/22/22



IMAGING PERFORMED BY

SVS Mobile Imaging MI 734-637-7711
svsimagingmi@gmail.com



EDUCATIONAL TELECONSULTATION SERVICES™
1-800-838-4268 info@sonopath.com SonoPath.com

PATIENT

Mumble Chilcote

SPECIES

Feline

BREED

DSH

SEX

Neutered Male

AGE

2 Years

WEIGHT

7.38 Pounds

INTERPRETED BY

Kathleen Sennello DVM,
MS, Diplomate ACVIM
(Small Animal Internal
Medicine)

IMAGING PERFORMED BY

Amy Mayhew, LVT

HOSPITAL NAME

SVS Imaging MI

REFERRING VET

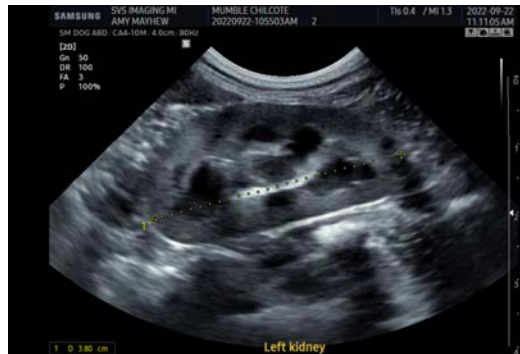Cat Care of
Rochester Hills

INVOICE

41537

DATE

9/22/22



The information and recommendations provided are based on the images presented by the referring veterinarian/sonographer. No evaluation can be communicated regarding pathology that was not visible in the image/video clips provided.

Thank you for this referral. If the clinical or image interpretation does not parallel your findings or if I can be of any further assistance please contact me.

Kathleen Sennello DVM,MS, Diplomate ACVIM (Small animal Internal Medicine)

kathleen.sennello@sonopath.com