

**DATE**

9/22/21

PRESENTING CLINICAL SIGNS

History of emesis, previously suspected as hairballs. P seems to vomit with certain foods and not others. History also of urolithiasis and previous cystotomy. Recent lab work revealed azotemia and low urine SG and mild eosinophilia. Intestinal parasite screening and serum food allergy testing – pending.

PATIENT

Milo Rowe

Current Medications: Only RC ultimino diet since 10th Sept.

Lab Results: BUN 39 (<36), Eosin 1120 (<1000), Creat 2.1,

Urine SG 1.018

Date of Previous IntraPet Ultrasound: No previous.

Sedation: Not needed.

SPECIES

Feline

Stat Report: Not requested.

BREED

Domestic Longhair

ULTRASONOGRAPHIC EXAMINATION OF THE ABDOMEN**Urinary System**

The urinary bladder is moderately distended with anechoic urine. The Bladder wall, trigone, ureteral papillae and visible urethra (to a depth of 2cm) appear normal with no evidence of wall thickening, mucosal irregularities, masses or cystic calculi.

SEX

Neutered male

The left kidney has a normal shape and size (4.35 cm). Overall echogenicity is normal with adequate corticomedullary distinction and a typical 1:3 cortex:medulla ratio. There is no evidence of perinephric inflammation or effusion. There is no evidence of pyelectasia, nephroliths, infarcts or hydroureter. Renal vasculature is normal.

AGE

2013

The right kidney has a normal shape and size (4.31 cm). Overall echogenicity is normal with adequate corticomedullary distinction and a typical 1:3 cortex:medulla ratio. There is no evidence of perinephric inflammation or effusion. A cortical cyst was noted and measured 0.57 x 0.82 cm. There is no evidence of pyelectasia, nephroliths, infarcts or hydroureter. Renal vasculature is normal.

WEIGHT

11.2 lbs

INTERPRETED BY

Kathleen Sennello
DVM, MS, Diplomate
ACVIM (Small Animal
Internal Medicine)

Adrenal Glands

The left adrenal gland is normal in size measuring 0.45 cm at the caudal pole. It is observed in its normal position cranial to the left renal artery. It is normal in appearance (uniformly hypoechoic) and shape with no evidence of a mass effect.

The right adrenal gland is normal in size measuring 0.42 cm at the caudal pole. It is observed in its normal position between the cranial aspect of the right kidney and the caudal vena cava. It is normal in appearance (uniformly hypoechoic) and shape with no evidence of a mass effect.

HOSPITAL NAME

Belvedere VC

Spleen

The spleen is subjectively normal in size, echotexture is homogenous, and the splenic capsule is smooth with no irregularities. The blood flow through the hilus and splenic parenchyma appears normal. No focal parenchymal abnormalities are visualized.

REFERRING VET

Dr. Eden

INVOICE

91928

Liver

The liver is subjectively normal in size, and echogenicity with smooth peripheral margins. The parenchyma is homogenous echotexture. The visible portions of the vasculature and biliary tract appear normal. No focal nodules or cystic lesions are observed. The gallbladder lumen is moderately distended. The wall of the gall bladder is not thickened and has a smooth mucosal surface. Luminal contents are primarily anechoic. The cystic and common bile ducts are normal/not visible.

Gastrointestinal

The stomach contains minimal luminal contents. It measures at a normal thickness of <0.36cm with some variability due to the presence of rugal folds. The distinction of the gastric wall layers is adequate and there is no impression of reduced peristaltic activity. No masses or focal lesions were observed.

The visualized areas of duodenum, jejunum and ileum have a relatively uniform diameter with minimal fluid distension. Wall thickness is normal. Bowel loops follow a curvilinear path with distinct wall layering maintaining the typical 1:3 muscularis:mucosa layer ratio. The duodenum measured as normal (0.25 cm) and the jejunum measured as normal (0.27 cm). Visualized peristalsis appears appropriate. There were no focal lesions consistent with obstruction or a mass effect observed.

The ileocecal junction was visualized and exhibited normal intact wall layering and is subjectively of normal thickness. Sections of colon are visualized with formed fecal material and gas shadowing distally. There is no observed focal or generalized colon wall thickening or loss of layering.

Pancreas

The pancreas is large and hypoechoic to surrounding mesentery. There is no evidence of nodules or cystic lesions. There is evidence of regional mesenteric inflammation. Consistent with mild pancreatitis. The pancreatic duct is prominent and measured 0.22 cm.

Free Abdomen

Evaluation of the peritoneal cavity did not reveal any evidence of effusion. There is a mild lymphadenomegaly present. The mesenteric lymph nodes particularly around the mesentery are prominent and measured 0.35 cm and 0.31 cm in diameter. There was no evidence of a caudal aortic thrombus at the bifurcation. The omentum is of normal uniform echogenicity.

ULTRASONOGRAPHIC FINDINGS

PRIMARY FINDINGS:

- Prominent hypoechoic pancreas with dilated pancreatic duct. The pancreatic changes are most consistent with mild pancreatitis/pancreatic infiltration. I recommend fPLI testing and continued monitoring for improvement or possible development of a pancreatic abscess. Consider FNA if not improving.
- Echogenic debris in the urinary bladder. The echogenic debris in the bladder lumen could be consistent with cells, crystals, and/or mucus. Recommend urinalysis and culture.
- Mildly enlarged/prominent mesenteric lymph nodes. The prominent abdominal lymph nodes are most consistent with reactive lymphadenitis or lymphoid hyperplasia. Neoplastic infiltration is considered less likely.

SECONDARY FINDINGS:

- Small cortical cyst in the right kidney. This is likely an incidental finding.

INTERPRETATION OF THE FINDINGS & FURTHER RECOMMENDATIONS

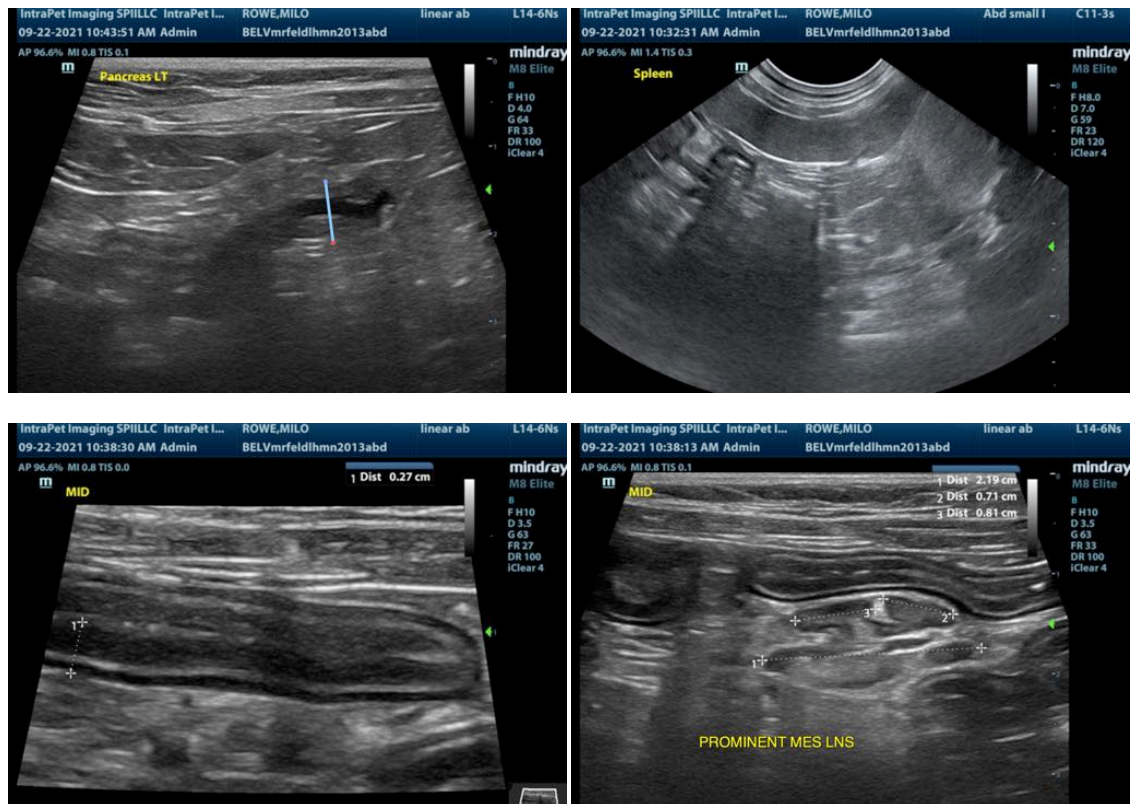
The kidneys appear relatively normal on today's scan. Unfortunately the clinical presentation of renal disease does not always correlate with the ultrasonographic findings. I recommend urinalysis and culture to look for any evidence of pyelonephritis or infection. I recommend blood pressure evaluation. Also consider an ACTH

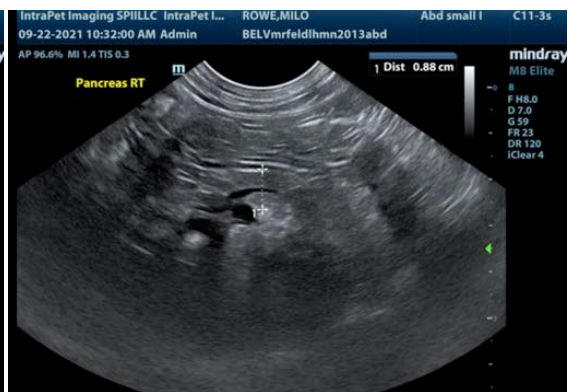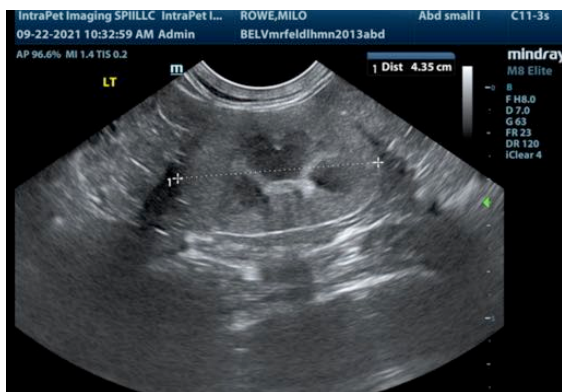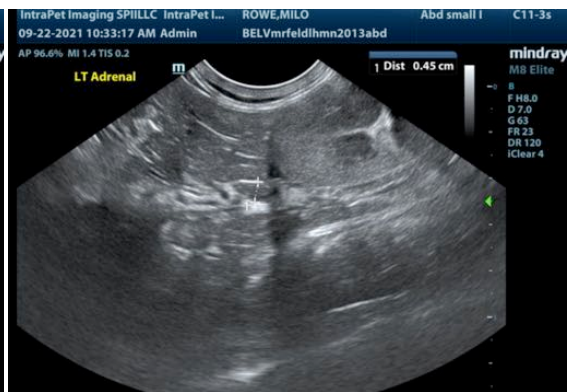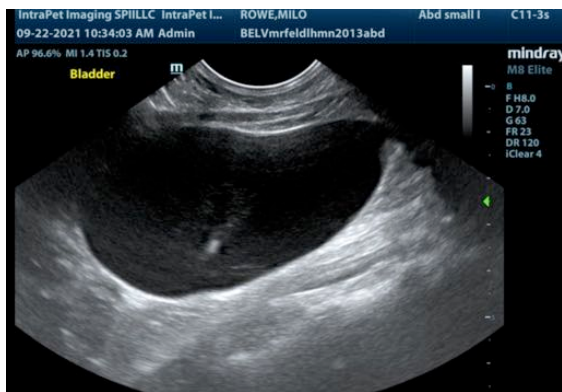
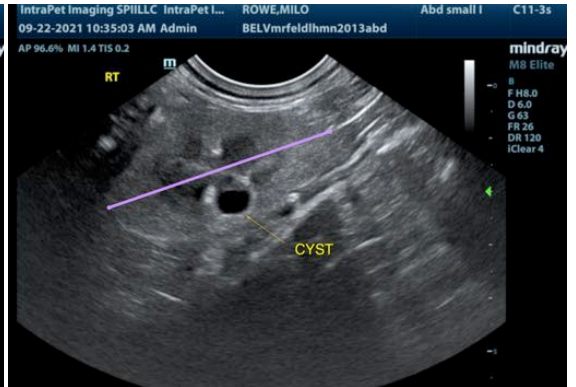
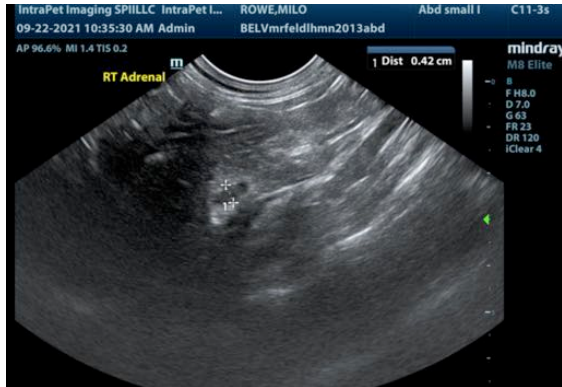stimulation test due to the azotemia and elevated eosinophil counts reported.

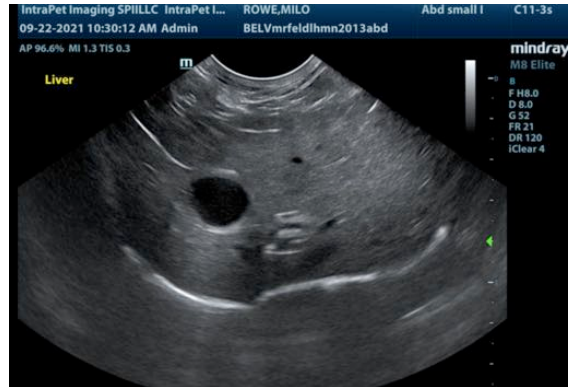
The pancreas is prominent. This may be consistent with current, mild pancreatitis or with previous episode that is resolving. Consider a GI panel with a quantitative fPLI, B12 and folate level to evaluate the pancreas further and look for evidence of small intestinal disease. If metabolic causes of vomiting are ruled out (including hyperthyroidism) then consider primary GI causes such as GI parasitism, dietary indiscretion, mild pancreatitis, bacterial dysbiosis, food allergy and less likely intestinal neoplasia.

In older patients with more chronic symptoms, I would most strongly consider food allergy, IBD, and intestinal neoplasia.

- Recommend diet trial with a novel protein/hydrolyzed prescription diet
- Recommend GI panel for evaluation of B12 levels etc.. (start empirical B12 while waiting for results)
- If symptoms are progressing consider obtaining GI biopsies







The information and recommendations provided are based on the images presented by the referring veterinarian. No evaluation can be communicated regarding pathology that was not visible in the image/video clips provided.

Thank you for this referral. If the clinical or image interpretation does not parallel your findings or if I can be of any further assistance please contact me.

Kathleen Sennello DVM,MS, Diplomate ACVIM (Small animal Internal Medicine)
kathleen.sennello@sonopath.com