



PATIENT

Luna Brahm

SPECIES

Canine

BREED

Australian Shep X

SEX

Spayed Female

AGE

11 Years

WEIGHT

61.4

INTERPRETED BY

Kathleen Sennello DVM,
MS, Diplomate ACVIM
(Small Animal Internal
Medicine)

**IMAGING
PERFORMED BY**

A. Murphy, CVT

HOSPITAL NAME

Wauwatosa VC

REFERRING VET

Dr. Elaine Binor

INVOICE

25730

DATE

9/22/21

PRESENTING CLINICAL SIGNS

History of a hemangioma that was removed on R axilla 7/2021. Abdominal imaging performed today to check for metastasis. Also has a history of elevated Alk phos. A heterogenous nodule was found on her L liver lobe in 6/2021. Plan to recheck liver and determine if there are any other masses present that would be concerning for liver neoplasia. CBC/Chem on 7/2021 was unremarkable.

ULTRASONOGRAPHIC EXAMINATION OF THE ABDOMEN

Urinary System

The urinary bladder is moderately distended with anechoic urine. The Bladder wall, trigone, ureteral papillae and visible urethra (to a depth of 2cm) appear normal with no evidence of wall thickening, mucosal irregularities, masses or cystic calculi.

The left kidney has a slightly irregular shape and normal size (6.32 cm). Overall echogenicity is slightly hyperechoic with poor corticomedullary distinction and a typical 1:3 cortex:medulla ratio. There is no evidence of perinephric inflammation or effusion. Multiple small cortical cysts and mild pyelectasia present at 0.3 cm. Multiple pinpoint non-obstructive nephroliths are present. There is no evidence of infarcts or hydroureter. Renal vasculature is normal.

The right kidney has a slightly irregular shape and normal size (5.2 cm). Overall echogenicity is slightly hyperechoic with poor corticomedullary distinction and a typical 1:3 cortex:medulla ratio. There is no evidence of perinephric inflammation or effusion. Multiple small cortical cysts noted. Multiple pinpoint non-obstructive nephroliths are present. There is no evidence of pyelectasia, infarcts or hydroureter. Renal vasculature is normal.

Adrenal Glands

The left adrenal gland is normal in size measuring 0.7 cm at the caudal pole. It is observed in its normal position cranial to the left renal artery. It is normal in appearance (uniformly hypoechoic) and shape with no evidence of a mass effect.

The region of the right adrenal (between right cranial kidney and vena cava) is unremarkable, but the adrenal is not distinctly visualized. No evidence of a mass effect.

Spleen

The spleen is subjectively normal in size, echotexture is homogenous, and the splenic capsule is smooth with no irregularities. The blood flow through the hilus and splenic parenchyma appears normal. No focal parenchymal abnormalities are visualized.

Liver

The liver is subjectively normal in size, and echogenicity with smooth peripheral margins. The parenchyma is heterogenous in echotexture with subtle, indistinct focal mottling. The visible portions of the vasculature and biliary tract appear normal. There is a 1.05 cm hyperechoic nodule visualized in the parenchyma.

The gallbladder lumen is moderately distended. The wall of the gall bladder is not thickened and has a smooth mucosal surface. Luminal contents are primarily anechoic. The cystic and common bile ducts are normal/not visible.



PATIENT

Gastrointestinal

Luna Brahm

The stomach contains minimal luminal contents. It measures at a normal thickness of <0.7cm with some variability due to the presence of rugal folds. The distinction of the gastric wall layers is adequate and there is no impression of reduced peristaltic activity. No masses or focal lesions were observed.

SPECIES

Canine

The visualized areas of duodenum, jejunum and ileum have a relatively uniform diameter with minimal fluid distension. Wall thickness is normal. Bowel loops follow a curvilinear path with distinct wall layering maintaining the typical 1:3 muscularis:mucosa layer ratio. Jejunum wall measured 0.38 cm.

BREED

Australian Shep X

Visualized peristalsis appears appropriate. There were no focal lesions consistent with obstruction or a mass effect observed.

SEX

Spayed Female

The ileocecal junction was visualized and exhibited normal intact wall layering and is subjectively of normal thickness. Sections of colon are visualized with formed fecal material and gas shadowing distally. There is no observed focal or generalized colon wall thickening or loss of layering.

AGE

11 Years

Pancreas

The area of the pancreas is normal and isoechoic to surrounding mesentery. There is no evidence of nodules or cystic lesions. There is no evidence of regional mesenteric inflammation or fluid.

WEIGHT

61.4

Free Abdomen

Evaluation of the peritoneal cavity did not reveal any evidence of effusion, or subjective lymphadenomegaly. The Medial iliac nodes appear normal and there was no evidence of a caudal aortic thrombus at the bifurcation. The omentum is of normal uniform echogenicity.

ULTRASONOGRAPHIC FINDINGS

- Bilaterally decreased corticomedullary distinction in the kidneys with non-obstructive nephroliths and small cortical cysts – Mild loss of corticomedullary distinction in both kidneys could be consistent with chronic degenerative disease or interstitial nephrosis.
- Heterogeneous liver with a hyperechoic nodule – The diffuse hepatic changes are non-specific and could be consistent with vacuolar hepatopathy, nodular hyperplasia, inflammatory/immune-mediated disease, fibrosis, extramedullary hematopoiesis, toxic hepatopathy (e.g., copper), infiltrative neoplasia (less likely) or other hepatopathy.

INTERPRETED BY

Kathleen Sennello DVM,
MS, Diplomate ACVIM
(Small Animal Internal
Medicine)

IMAGING PERFORMED BY

A. Murphy, CVT

HOSPITAL NAME

Wauwatosa VC

REFERRING VET

Dr. Elaine Binor

INTERPRETATION OF THE FINDINGS & FURTHER RECOMMENDATIONS

No obvious evidence of metastasis was visualized on today's scan. The liver is heterogeneous and has ill-defined nodules, so any of these could represent a metastatic lesion, but a definitive concerning lesion was not observed. You could consider a fine needle aspirate of the liver, particularly in the area where the nodule was previously observed (left side). Recommend 3-view thoracic radiographs if not already done.

INVOICE

25730

DATE

9/22/21

Both kidneys have significant change consistent with chronic progressive disease. This may or may not be clinically relevant. Correlate with blood work and urine specific gravity. Consider a blood pressure evaluation.

The left adrenal appears relatively normal in size and the right was not clearly seen, making pituitary dependent Cushing's possibly less likely, although if significant clinical signs are present that are consistent with Cushing's, you could consider adrenal function testing as a possible differential for the elevation in ALP. Otherwise, consider liver function test, fine needle aspirate and continued monitoring +/- Denamarin.



PATIENT

Luna Brahm

SPECIES

Canine

BREED

Australian Shep X

SEX

Spayed Female

AGE

11 Years

WEIGHT

61.4

INTERPRETED BY

Kathleen Sennello DVM,
MS, Diplomate ACVIM
(Small Animal Internal
Medicine)

**IMAGING
PERFORMED BY**

A. Murphy, CVT

HOSPITAL NAME

Wauwatosa VC

REFERRING VET

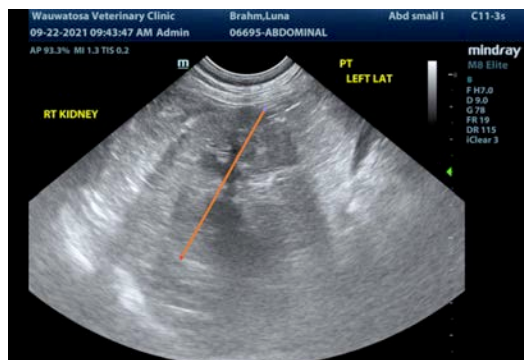
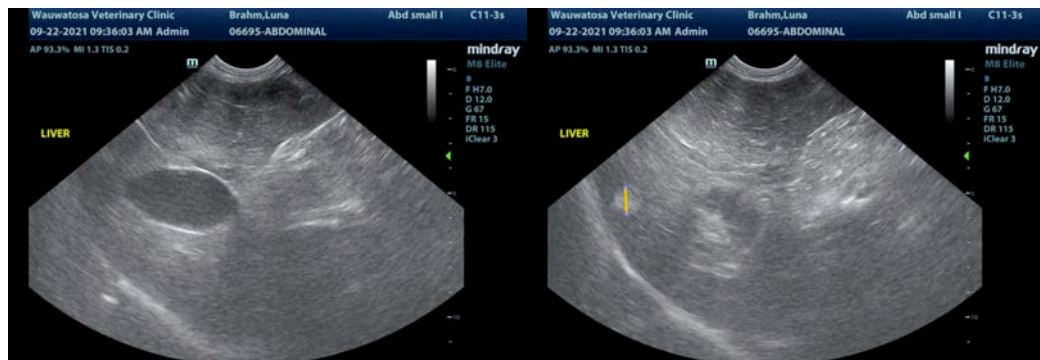
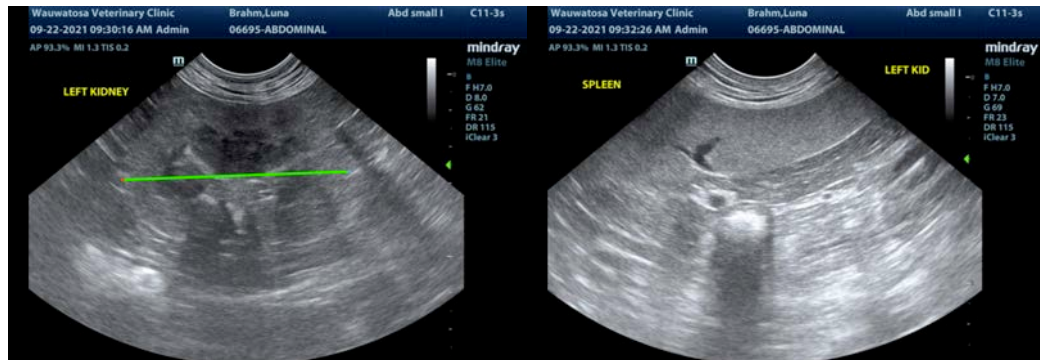
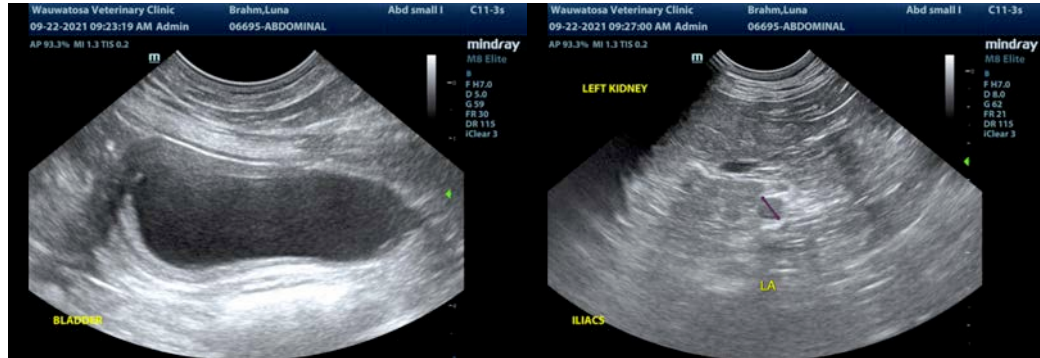
Dr. Elaine Binor

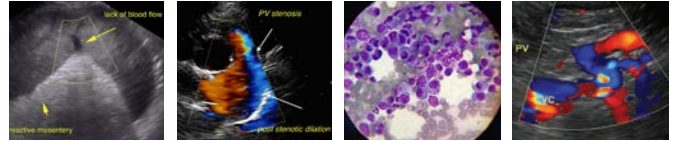
INVOICE

25730

DATE

9/22/21





PATIENT

Luna Brahm

The information and recommendations provided are based on the images presented by the referring veterinarian. No evaluation can be communicated regarding pathology that was not visible in the image/video clips provided.

SPECIES

Canine

Thank you for this referral. If the clinical or image interpretation does not parallel your findings or if I can be of any further assistance please contact me.

BREED

Australian Shep X

Kathleen Sennello DVM,MS, Diplomate ACVIM (Small animal Internal Medicine)
kathleen.sennello@sonopath.com

SEX

Spayed Female

AGE

11 Years

WEIGHT

61.4

INTERPRETED BY

Kathleen Sennello DVM,
MS, Diplomate ACVIM
(Small Animal Internal
Medicine)

**IMAGING
PERFORMED BY**

A. Murphy, CVT

HOSPITAL NAME

Wauwatosa VC

REFERRING VET

Dr. Elaine Binor

INVOICE

25730

DATE

9/22/21