

**DATE PRESENTING CLINICAL SIGNS**

9/21/22 Dribbling urine in the house for the past few weeks.

PATIENT Current Medications: None.

Oskey Acuna Lab Results: Chem/CBC wnl. UA (via urinary cath) in transitional cells. Dec USG repeat morning free catch USG still low.

Date of Previous IntraPet Ultrasound: No previous.

SPECIES Sedation: Not required to complete full diagnostic ultrasound.

Stat Report: Not requested.

Canine

ULTRASONOGRAPHIC EXAMINATION OF THE ABDOMEN**BREED**

Australian Shepherd

Urinary System

The urinary bladder is significantly distended with anechoic urine. The Bladder wall, trigone, ureteral papillae and visible urethra (to a depth of 2cm) appear normal with no evidence of wall thickening, mucosal irregularities, masses or cystic calculi.

SEX

Neutered Male

The prostate is normal in size (0.74 cm) and shape for this neutered male dog. The parenchyma is homogenous and the external margins are smooth. The prostatic urethra appears normal with no evidence of irregularity, invasion, mass effect or calculi.

AGE

4/18/14

The left kidney has a normal shape and size (5.78 cm). Overall echogenicity is normal with adequate corticomedullary distinction and a typical 1:3 cortex:medulla ratio. There is no evidence of focal perinephric inflammation or effusion. There is no evidence of pyelectasia, nephroliths, infarcts or hydroureter. Renal vasculature is normal.

WEIGHT

45.8 Pounds

The right kidney has a normal shape and size (6.35 cm). Overall echogenicity is normal with adequate corticomedullary distinction and a typical 1:3 cortex:medulla ratio. There is no evidence of focal perinephric inflammation or effusion. There is no evidence of pyelectasia, nephroliths, infarcts or hydroureter. Renal vasculature is normal.

INTERPRETED BY

Kathleen Sennello DVM,
MS, Diplomate ACVIM
(Small Animal Internal
Medicine)

Adrenal Glands

The left adrenal gland is normal in size measuring 0.52 cm at the caudal pole. It is observed in its normal position cranial to the left renal artery. It is normal in appearance (uniformly hypoechoic) and shape with no evidence of a mass effect.

IMAGING PERFORMED BY

Stephanie Warga
RDCS, RVT

The right adrenal gland is normal in size measuring 0.55 cm at the caudal pole. It is observed in its normal position between the cranial aspect of the right kidney and the caudal vena cava. It is normal in appearance (uniformly hypoechoic) and shape with no evidence of a mass effect.

HOSPITAL NAME

Belvedere Vet Center

Spleen

The spleen is subjectively normal in size, echotexture is homogenous, and the splenic capsule is smooth with no irregularities. The blood flow through the hilus and splenic parenchyma appears normal. No focal parenchymal abnormalities are visualized.

REFERRING VET

Dr. Amstalden

Liver

The liver is subjectively normal in size, and echogenicity with smooth peripheral margins. The parenchyma is homogenous echotexture. The visible portions of the vasculature and biliary tract appear normal. No focal nodules or cystic lesions are observed.

INVOICE

41479

The gall bladder lumen is moderately distended. The wall of the gall bladder is not thickened and has a smooth mucosal surface. There is a moderate amount of non-organized echogenic debris. The cystic and common bile ducts are normal/not visible.

Gastrointestinal

The stomach contains minimal luminal contents. It measures at a normal thickness of <0.7cm with some variability due to the presence of rugal folds. The distinction of the gastric wall layers is adequate and there is no impression of reduced peristaltic activity. No masses or focal lesions were observed.

The visualized areas of duodenum, jejunum and ileum have a relatively uniform diameter with minimal fluid distension. Wall thickness is normal. Bowel loops follow a curvilinear path with distinct wall layering maintaining the typical 1:3 muscularis:mucosa layer ratio. The duodenum measured as normal (between 0.3-0.5cm in wall thickness) and the jejunum measured as normal (between 0.2-0.47cm.) Visualized peristalsis appears appropriate. There were no focal lesions consistent with obstruction or a mass effect observed.

The ileocecal junction was visualized and exhibited normal intact wall layering and is subjectively of normal thickness. Sections of colon are visualized with formed fecal material and gas shadowing distally. There is no observed focal or generalized colon wall thickening or loss of layering.

Pancreas

The pancreas is normal and isoechoic to surrounding mesentery. There is no evidence of nodules or cystic lesions. There is no evidence of regional mesenteric inflammation or fluid.

Free Abdomen

Evaluation of the peritoneal cavity did not reveal any evidence of effusion, or subjective lymphadenomegaly. The Medial iliac nodes appear normal and there was no evidence of a caudal aortic thrombus at the bifurcation. The omentum is of normal uniform echogenicity.

ULTRASONOGRAPHIC FINDINGS

- Moderate gallbladder debris – The significance of the aggregated gallbladder debris is unclear. This could represent an early mucocele, cholestasis, or may be secondary to fasting but seems unlikely to be causing a current issue. Recommend continued monitoring.

INTERPRETATION OF THE FINDINGS & FURTHER RECOMMENDATIONS

Today's scan is relatively normal. No focal lesions are visualized to explain the urine dribbling and dilute urine reported. The first step may be to try to quantitate water intake and try to determine if this patient is truly polydipsic, a digital rectal exam to palpate for any abnormalities in the distal urethra, etc.

If this patient is truly PU/PD, some issues such as early renal disease, Cushing's disease, behavioral abnormalities, neurologic disease, dietary/electrolyte disturbances, etc. are not able to be diagnosed with ultrasound alone. These can be challenging cases. Top 10 differentials can be ruled/out with routine bloodwork, urinalysis and culture. Several more can be evaluated with a good history of imaging. Unfortunately, as you work your way down the list of differentials, it becomes harder to definitively diagnose. This is a differential list that I start with:

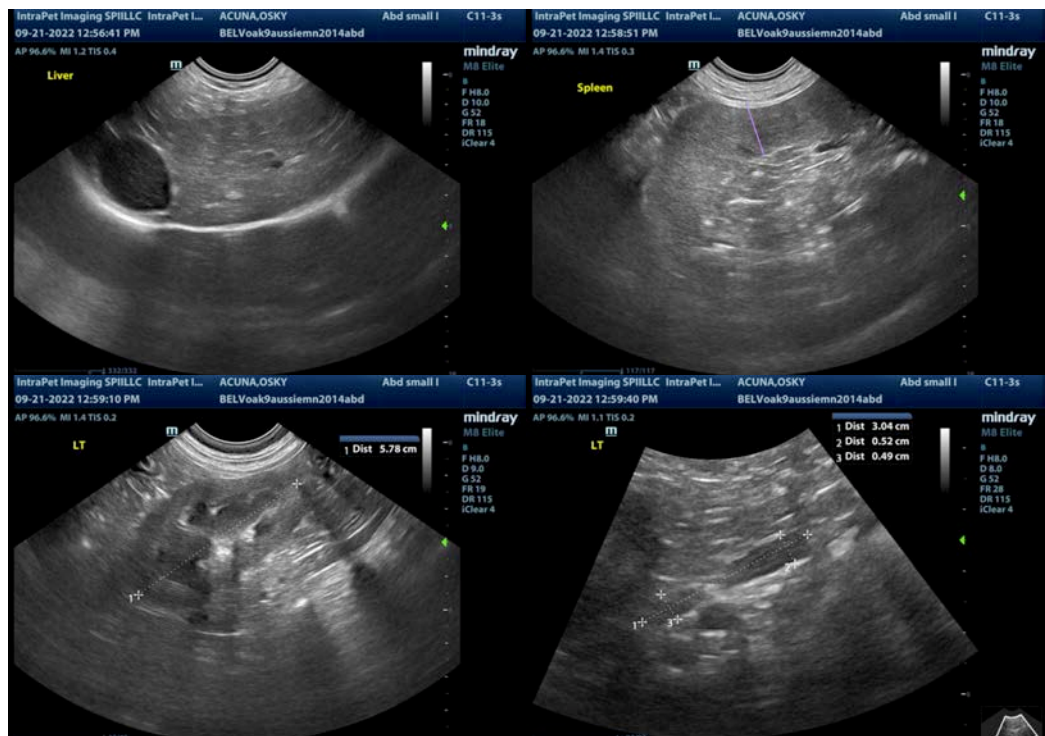
Diabetes Mellitus

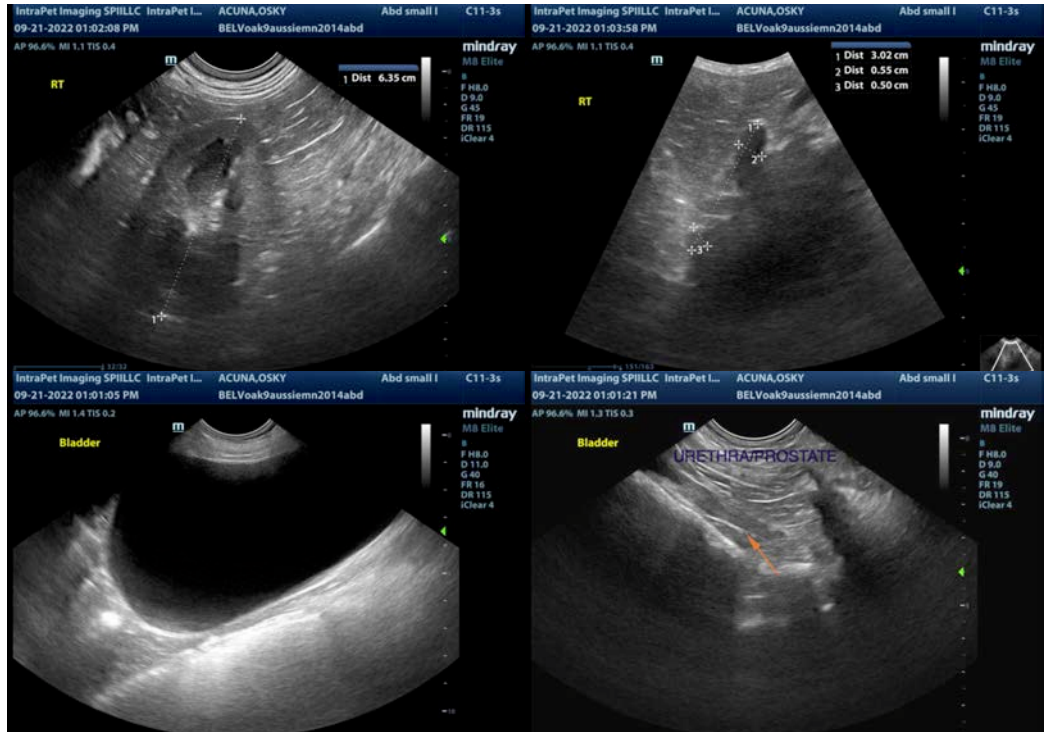
Chronic Renal Disease/Renal Failure (can present pre-azotemic, especially in dogs, but expect the BUN & creatinine not to be at the low end of the reference range)

Hypercalcemia

Urinary tract infection

Iatrogenic Disease due to medications (diuretics, phenobarbital, KBr; diets either high in salt [such as S/D] or very low in protein (such as U/D))
 Hyperthyroidism
 Hypokalemia
 Liver Disease (hepatic encephalopathy may be a mixed primary PU and PD)
 Pyelonephritis
 Polycythemia
 Renal Tubular Diseases (glycosuria or Fanconi & Fanconi-like syndromes or RTA)
 Hyperadrenocorticism (may be a mixed primary PU and PD)
 Hypoadrenocorticism (either Addison's or hypocortisolism)
 Paraneoplastic Syndromes (particularly splenic hemangiosarcoma?)
 Pericardial Effusion
 Pyometra (including stump pyometra in spayed dogs)
 Chronic Partial Urinary Obstruction or Post-Obstructive Diuresis
 Pheochromocytoma
 Psychogenic Polydipsia (as in a true behavior disorder with a compulsive element)
 Primary Non-Medical Polydipsia (aka "I drink a lot because I like it or I engage in activities that promote it, but that doesn't mean I'm sick")
 Primary Nephrogenic Diabetes Insipidus (Congenital Nephrogenic Diabetes Insipidus, other diseases that cause primary PU other than Congenital Diabetes Insipidus would be considered Acquired Nephrogenic Diabetes Insipidus)
 cion
 Atypical Cushing's and SARDS
 Central Diabetes Insipidus





The information and recommendations provided are based on the images presented by the referring veterinarian/sonographer. No evaluation can be communicated regarding pathology that was not visible in the image/video clips provided.

Thank you for this referral. If the clinical or image interpretation does not parallel your findings or if I can be of any further assistance please contact me.

Kathleen Sennello DVM,MS, Diplomate ACVIM (Small animal Internal Medicine)
kathleen.sennello@sonopath.com