IMAGING PERFORMED BY
SVS Mobile Imaging MI 734 - 637 - 7711
svsimagingmi@gmail.com

SVS IMAGING

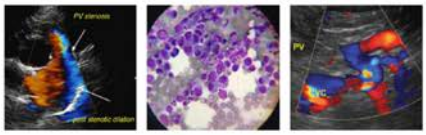

SonoPath
Clinical Sonography & Telecytology
EDUCATIONAL TELECONSULTATION SERVICES™
1-800-838-4268 info@sonopath.com SonoPath.com

PATIENT

Daisy Hood

SPECIES

Canine

BREED

English Springer Spaniel

SEX

Spayed Female

AGE

13 Years 9 Months

WEIGHT

48 Pounds

INTERPRETED BY

Kathleen Sennello DVM, MS, Diplomate ACVIM (Small Animal Internal Medicine)

IMAGING PERFORMED BY

Amy Mayhew, LVT

HOSPITAL NAME

SVS Imaging MI

REFERRING VET

Family Pet Practice

INVOICE

41501

DATE

9/21/22

PRESENTING CLINICAL SIGNS

Current Medications: Enrofloxacin 136mg 1 tab PO SID (started 9/20/22) Deracoxib 25mg 1 tab PO SID (started 9/20/22) **Recent enrofloxacin 68mg 1.5 tab PO SID x 7d (completed 9/17/22) **Recent gabapentin 200mg PO q12h x 3d (completed 9/11/22) O gives diphenhydramine and Vitamin E OTC Patient History: Presented for follow-up from ER clinic - initally seen for PU/PD, Pollakiuria noted after initial larger urination. Initial improvement after enrofloxacin 68mg 1.5 tab PO SID and gabapentin 200mg PO q12h x 3d. Since completion of medications clinical signs returned.

Abnormal PE/Chem/CBC/UA Results: . BAR, anxious 4. Ointment present in both canals- lower canals clean/normal- O has been medicating ears x 7days, plan recheck ears at next visit. 5. Heavy calculus with GR over 108,208- cannot rule-out root absecesses- recommend dental w/rads in near future. Generalized gingival hyperplasia 6. Normal heart sounds 7. Panting intially during exam, respirations normalized as anxiety improved through visit, normal lung sounds 8. Numerous SQ masses - large broad mass over left thorax- previously aspirated as lipoma per prev records. Per O previously discussed removal with prev DVM O expressed concern for mass over dorsal right expaxial- recommended FNA, suspect cystic, rule-out other neoplasia **Body map created to document numerous masses today 9/10. Soft abdomen, bladder small/medium. No discharge present from vulva. Mild salivary stainin around anus. Rectal exam- large anal sacs bilaterally- expressed normal material from both sacs. 12. Moderate reduction in hip extension bilaterally, recommend monitoring for improvement with Mobility with nsaid, may be continued long-term if doing well on nsaid, reviewed regular blood monitoring if on long-term nsaids

ULTRASONOGRAPHIC EXAMINATION OF THE ABDOMEN

Urinary System

The urinary bladder is mildly/moderately distended with anechoic urine. The Bladder wall appears diffusely thickened and irregular, measuring up to 0.90 cm in thickness. The area of the trigone, ureteral papillae and visible urethra (to a depth of 2cm) appear normal with minimal mucosal irregularity and wall thickening. Findings are most consistent with cystitis and lack of urine distention. Underlying neoplasia cannot be ruled out.

The left kidney has a normal shape and size (5.72 cm). Overall echogenicity is slightly hyperechoic with poor corticomedullary distinction and a typical 1:3 cortex:medulla ratio. There is no evidence of focal perinephric inflammation or effusion. There is no evidence of pyelectasia, nephroliths, infarcts or hydroureter. Renal vasculature is normal.

The right kidney has a normal shape and size (6.02 cm). Overall echogenicity is slightly hyperechoic with poor corticomedullary distinction and a typical 1:3 cortex:medulla ratio. There is no evidence of focal perinephric inflammation or effusion. There is no evidence of pyelectasia, nephroliths, infarcts or hydroureter. Renal vasculature is normal.

Adrenal Glands

The left adrenal gland is normal in size measuring 0.64 cm at the caudal pole. It is observed in its normal position cranial to the left renal artery. It is normal in appearance (uniformly hypoechoic) and shape with no evidence of a mass effect.

The right adrenal gland is normal in size measuring 0.58 cm at the caudal pole. It is observed in its normal position between the cranial aspect of the right kidney and the caudal vena cava. It is normal in appearance (uniformly hypoechoic) and shape with no evidence of a mass effect.

IMAGING PERFORMED BY
SVS Mobile Imaging MI 734 - 637 - 7711
svsimagingmi@gmail.com

SVS IMAGING

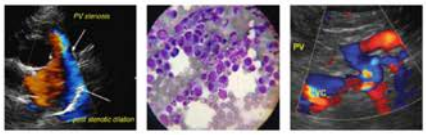

SonoPath
Clinical Sonography & Telecytology
EDUCATIONAL TELECONSULTATION SERVICES™
1-800-838-4268 info@sonopath.com SonoPath.com

PATIENT

Daisy Hood

SPECIES

Canine

BREED

English Springer Spaniel

SEX

Spayed Female

AGE

13 Years 9 Months

WEIGHT

48 Pounds

INTERPRETED BY

Kathleen Sennello DVM, MS, Diplomate ACVIM (Small Animal Internal Medicine)

IMAGING PERFORMED BY

Amy Mayhew, LVT

HOSPITAL NAME

SVS Imaging MI

REFERRING VET

Family Pet Practice

INVOICE

41501

DATE

9/21/22

Spleen

The spleen is subjectively normal in size, echotexture is homogenous, and the splenic capsule is smooth with no irregularities. The blood flow through the hilus and splenic parenchyma appears normal. There is a hyperechoic lesion towards the tail of the spleen with a surrounding hypoechoic rim measuring 1.3 cm x 1.8 cm. This lesion mildly deviates the splenic capsule.

Liver

The liver is large in size, and normal in echogenicity with smooth peripheral margins. The parenchyma is heterogenous in echotexture with subtle, indistinct focal mottling. The visible portions of the vasculature and biliary tract appear normal. No focal nodules or cystic lesions are observed.

The gall bladder lumen is moderately distended. The wall of the gall bladder is not thickened and has a smooth mucosal surface. There is a moderate amount of non-organized echogenic debris. The cystic and common bile ducts are normal/not visible.

Gastrointestinal

The stomach contains minimal luminal contents. It measures at a normal thickness of <0.7cm with some variability due to the presence of rugal folds. The distinction of the gastric wall layers is adequate and there is no impression of reduced peristaltic activity. No masses or focal lesions were observed.

The visualized areas of duodenum, jejunum and ileum have a relatively uniform diameter with minimal fluid distension. Wall thickness is normal. Bowel loops follow a curvilinear path with distinct wall layering maintaining the typical 1:3 muscularis:mucosa layer ratio. Duodenum wall measures 0.59 cm. Jejunum wall measures 0.46 cm. Visualized peristalsis appears appropriate. There were no focal lesions consistent with obstruction or a mass effect observed.

The ileocecal junction was visualized and exhibited normal intact wall layering and is subjectively of normal thickness. Sections of colon are visualized with formed fecal material and gas shadowing distally. There is no observed focal or generalized colon wall thickening or loss of layering.

Pancreas

The pancreas is normal and isoechoic to surrounding mesentery. There is no evidence of nodules or cystic lesions. There is no evidence of regional mesenteric inflammation or fluid.

Free Abdomen

Evaluation of the peritoneal cavity did not reveal any evidence of effusion, or subjective lymphadenomegaly. The Medial iliac nodes appear normal and there was no evidence of a caudal aortic thrombus at the bifurcation. The omentum is of normal uniform echogenicity.

ULTRASONOGRAPHIC FINDINGS

- Thickened, irregular urinary bladder wall – most consistent with cystitis and lack of urine distention. Underlying neoplasia cannot be excluded as a possibility.
- Decreased corticomedullary distinction in both kidneys – The bilateral renal findings are consistent with age-related change.
- Hyperechoic nodule with surrounding hypoechoic margins visualized in the spleen – There is a non-cavitated, mixed echogenic splenic nodule visualized. Differentials include lymphoid hyperplasia, extramedullary hematopoiesis, infiltrative neoplasia, inflammation, other. Cytology or histopathology would be necessary to get a definitive diagnosis.

IMAGING PERFORMED BY
SVS Mobile Imaging MI 734 - 637 - 7711
svsimagingmi@gmail.com

SVS IMAGING

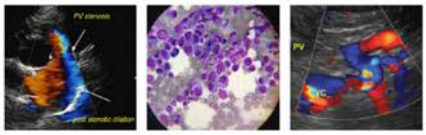

SonoPath
Clinical Sonography & Telecytology
EDUCATIONAL TELECONSULTATION SERVICES™
1-800-838-4268 info@sonopath.com SonoPath.com

PATIENT

Daisy Hood

SPECIES

Canine

BREED

English Springer Spaniel

SEX

Spayed Female

AGE

13 Years 9 Months

WEIGHT

48 Pounds

INTERPRETED BY

Kathleen Sennello DVM, MS, Diplomate ACVIM (Small Animal Internal Medicine)

IMAGING PERFORMED BY

Amy Mayhew, LVT

HOSPITAL NAME

SVS Imaging MI

REFERRING VET

Family Pet Practice

INVOICE

41501

DATE

9/21/22

- Large, heterogeneous liver – The diffuse hepatic changes are non-specific and could be consistent with vacuolar hepatopathy, nodular hyperplasia, inflammatory/immune-mediated disease, fibrosis, extramedullary hematopoiesis, toxic hepatopathy (e.g., copper), infiltrative neoplasia (less likely) or other hepatopathy. In the absence of liver enzyme elevations this could also represent age related remodeling.

- Moderate gallbladder debris – The significance of the aggregated gallbladder debris is unclear. This could represent an early mucocele, cholestasis, or may be secondary to fasting but seems unlikely to be causing a current issue. Recommend continued monitoring.

INTERPRETATION OF THE FINDINGS & FURTHER RECOMMENDATIONS

The most likely source for the PU/PD and pollakiuria is the urinary tract infection and cystitis reported. Bladder wall still appears somewhat thickened and irregular. Consider re-culturing the urine with at least a week off of antibiotics to see if an active infection can be identified. If there is an infection present, recommend treatment until the urinary bladder wall normalizes. Consider culturing on antibiotics in the middle of treatment, and again approximately one week after cessation of treatment. Consider chronic probiotic therapy while using antibiotics (and possibly forever). If a urinary tract infection cannot be identified, then you may want to consider evaluation of a more distended urinary bladder, and if it is persistently irregular, a traumatic catheterization. At this time, this lesion is most consistent with diffuse cystitis.

Additionally, you could consider other causes for PU/PD. There is a mixed echogenic lesion towards the tail of the spleen. Options moving forward would include a fine needle aspirate, continued monitoring with ultrasound, or splenectomy with histopathology. This lesion does deviate the splenic capsule somewhat, which can be an indicator of a more aggressive lesion.

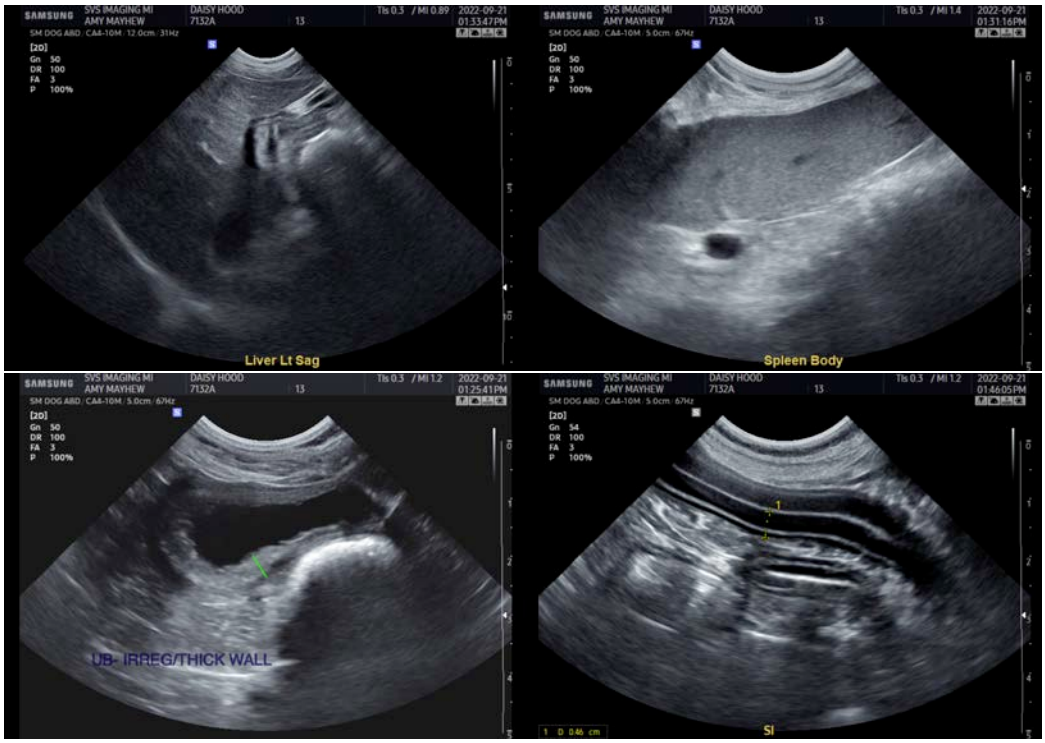

IMAGING PERFORMED BY
SVS Mobile Imaging MI 734 - 637 - 7711
svsimagingmi@gmail.com

SVS IMAGING

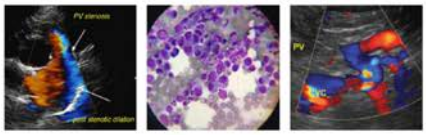

SonoPath
Clinical Sonography & Telecytology
EDUCATIONAL TELECONSULTATION SERVICES™
1-800-838-4268 info@sonopath.com SonoPath.com

PATIENT

Daisy Hood

SPECIES

Canine

BREED

English Springer Spaniel

SEX

Spayed Female

AGE

13 Years 9 Months

WEIGHT

48 Pounds

INTERPRETED BY

Kathleen Sennello DVM, MS, Diplomate ACVIM (Small Animal Internal Medicine)

IMAGING PERFORMED BY

Amy Mayhew, LVT

HOSPITAL NAME

SVS Imaging MI

REFERRING VET

Family Pet Practice

INVOICE

41501

DATE

9/21/22

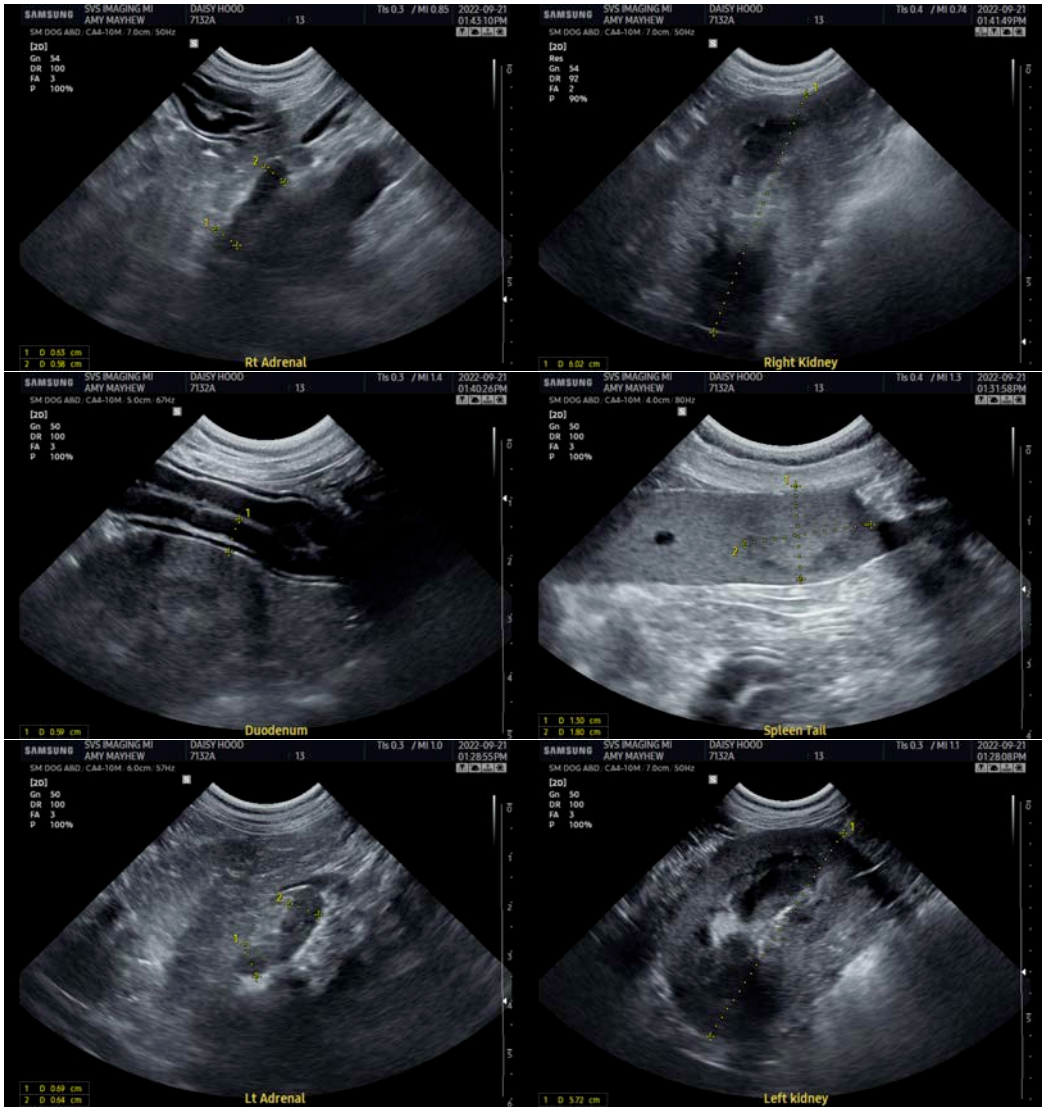

The information and recommendations provided are based on the images presented by the referring veterinarian/sonographer. No evaluation can be communicated regarding pathology that was not visible in the image/video clips provided.

Thank you for this referral. If the clinical or image interpretation does not parallel your findings or if I can be of any further assistance please contact me.

Kathleen Sennello DVM,MS, Diplomate ACVIM (Small animal Internal Medicine)

kathleen.sennello@sonopath.com