**PATIENT**

Bea Palmby 53551A

SPECIES

Canine

BREED

Yorkshire Terrier

SEX

Spayed Female

AGE

8 Years 10 Months

WEIGHT

2.24 kg

INTERPRETED BYKathleen Sennello DVM,
MS, Diplomate ACVIM
(Small Animal Internal
Medicine)**IMAGING
PERFORMED BY**

Tom McNeill

HOSPITAL NAME

SVS Imaging CT

REFERRING VET

Dr. Tom

INVOICE

41448

DATE

9/21/22

PRESENTING CLINICAL SIGNS

Bea presented for further evaluation of seizure/twitching like activity, severe lethargy, and vomiting/diarrhea on 9/20/22. Bea has a chronic history of vomiting/diarrhea occurring few times/month; however, generally improves on her own. She was previously diagnosed with inflammatory bowel disease based on abdominal ultrasound a few years ago that was controlled on prednisone; however, she has not been on prednisone for years. Bea was noted to have a few shaking episodes a couple weeks ago. She had hematochezia for a few days approximately 10 days ago, and over the last week has been unwilling to go on her normal walk length.

Abnormal PE/Chem/CBC/UA Results: -On presentation to rDVM, she was depressed, lethargic, twitchy; nauseated, hard swallowing; no fever, no abdominal pain -BG on intake was 22 mg/dl; no fever - An IVC was placed, and patient received several boluses of 25% dextrose, and was started on a D5W CRI at 8 mL/hour -Blood work showed BG of 24 (before dextrose bolus); K+ 3.0; otherwise CBC/Chem/Lytes was unremarkable -Not a diabetic, no ingestion of xylitol (very closely monitored) - First dextrose bolus was 2 mL of 25% dextrose IV; recheck BG was 100 mg/dl -Then dropped down to 22 mg/dl at 12:30pm -Bolused another 2 mL of 25% dextrose IV; BG 1 hour later was 77 mg/dl -rDVM just gave 3mL of 50% dextrose orally around 2:30pm Blood Glucose Monitoring Overnight: 7pm 104 9pm 93 9:30p 72 10pm 67 10:30p 53 11pm 59 11:30p 65 1am 50 5am 105

ULTRASONOGRAPHIC EXAMINATION OF THE ABDOMEN**Urinary System**

The urinary bladder is moderately distended with anechoic urine. The Bladder wall, trigone, ureteral papillae and visible urethra (to a depth of 2cm) appear normal with no evidence of wall thickening, mucosal irregularities, masses or cystic calculi.

The left kidney has a normal shape and size (3.04 cm) with occasional small mineralizations/nephroliths. Overall echogenicity is normal with adequate corticomedullary distinction and a typical 1:3 cortex:medulla ratio. There is no evidence of focal perinephric inflammation or effusion. There is no evidence of pyelectasia, infarcts or hydroureter. Renal vasculature is normal.

The right kidney has a normal shape and size (3.33 cm) with occasional small mineralizations/nephroliths. Overall echogenicity is normal with adequate corticomedullary distinction and a typical 1:3 cortex:medulla ratio. There is no evidence of focal perinephric inflammation or effusion. There is no evidence of pyelectasia, infarcts or hydroureter. Renal vasculature is normal.

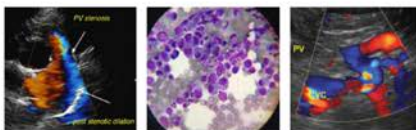
Adrenal Glands

The left adrenal gland is normal in size measuring 0.39 cm at the caudal pole. It is observed in its normal position cranial to the left renal artery. It is normal in appearance (uniformly hypoechoic) and shape with no evidence of a mass effect.

The right adrenal gland is normal in size measuring 0.30 cm at the caudal pole. It is observed in its normal position between the cranial aspect of the right kidney and the caudal vena cava. It is normal in appearance (uniformly hypoechoic) and shape with no evidence of a mass effect.

Spleen

The spleen is subjectively normal in size, echotexture is homogenous, and the splenic capsule is smooth with no irregularities. The blood flow through the hilus and splenic parenchyma appears normal. No focal parenchymal abnormalities are visualized.

**PATIENT**

Bea Palmby 53551A

SPECIES

Canine

BREED

Yorkshire Terrier

SEX

Spayed Female

AGE

8 Years 10 Months

WEIGHT

2.24 kg

INTERPRETED BYKathleen Sennello DVM,
MS, Diplomate ACVIM
(Small Animal Internal
Medicine)**IMAGING
PERFORMED BY**

Tom McNeill

HOSPITAL NAME

SVS Imaging CT

REFERRING VET

Dr. Tom

INVOICE

41448

DATE

9/21/22

Liver

The liver is subjectively normal in size, and echogenicity with smooth peripheral margins. The parenchyma is mildly heterogenous in echotexture with subtle, indistinct focal mottling. The visible portions of the vasculature and biliary tract appear normal. There is a somewhat irregular, ill-defined, hypoechoic lesion visualized on the right side of the liver near midline, measuring 0.66 cm x 1.54 cm.

The gallbladder lumen is moderately distended. The wall of the gall bladder is not thickened and has a smooth mucosal surface. Luminal contents are mild and primarily anechoic. The cystic and common bile ducts are normal/not visible.

Gastrointestinal

The stomach contains minimal luminal contents. It measures at a normal thickness of <0.7cm with some variability due to the presence of rugal folds. The distinction of the gastric wall layers is adequate and there is no impression of reduced peristaltic activity. No masses or focal lesions were observed.

The visualized areas of duodenum, jejunum and ileum have a relatively uniform diameter with minimal fluid distension. Wall thickness is normal. Bowel loops follow a curvilinear path with distinct wall layering maintaining the typical 1:3 muscularis:mucosa layer ratio. Duodenum wall measures 0.27 cm. Jejunum wall measures 0.23 cm. Visualized peristalsis appears appropriate. There were no focal lesions consistent with obstruction or a mass effect observed.

The ileocecal junction was visualized and exhibited normal intact wall layering and is subjectively of normal thickness (0.13 cm). Sections of colon are visualized with formed fecal material and gas shadowing distally. There is no observed focal or generalized colon wall thickening or loss of layering.

Pancreas

The pancreas is normal and isoechoic to surrounding mesentery. There is no evidence of nodules or cystic lesions. There is no evidence of regional mesenteric inflammation or fluid.

Free Abdomen

There is scant free abdominal fluid. There are visible but isoechoic lymph nodes. The sublumbar lymph node measures at 0.36 cm in diameter. The left and right medial iliac lymph nodes measure 0.38 cm and 0.38 cm. The omentum is generally of normal echogenicity.

ULTRASONOGRAPHIC FINDINGS

- Heterogeneous liver with ill-defined hypoechoic region – The diffuse hepatic changes are non-specific and could be consistent with vacuolar hepatopathy, nodular hyperplasia, inflammatory/immune-mediated disease, fibrosis, extramedullary hematopoiesis, toxic hepatopathy (e.g., copper), infiltrative neoplasia (less likely) or other hepatopathy. These changes could also be consistent with age related remodeling. The significance of the hypoechoic lesion is unclear, as it is somewhat poorly defined and does not appear to deviate the architecture. Recommend continued monitoring.
- Scant free abdominal fluid
- Visible caudal abdominal lymph nodes – The prominent abdominal lymph nodes are most consistent with reactive lymphadenitis or lymphoid hyperplasia. Neoplastic infiltration is considered less likely.



PATIENT

Bea Palmby 53551A

SPECIES

Canine

BREED

Yorkshire Terrier

SEX

Spayed Female

AGE

8 Years 10 Months

WEIGHT

2.24 kg

INTERPRETED BY

Kathleen Sennello DVM,
MS, Diplomate ACVIM
(Small Animal Internal
Medicine)

IMAGING PERFORMED BY

Tom McNeill

HOSPITAL NAME

SVS Imaging CT

REFERRING VET

Dr. Tom

INVOICE

41448

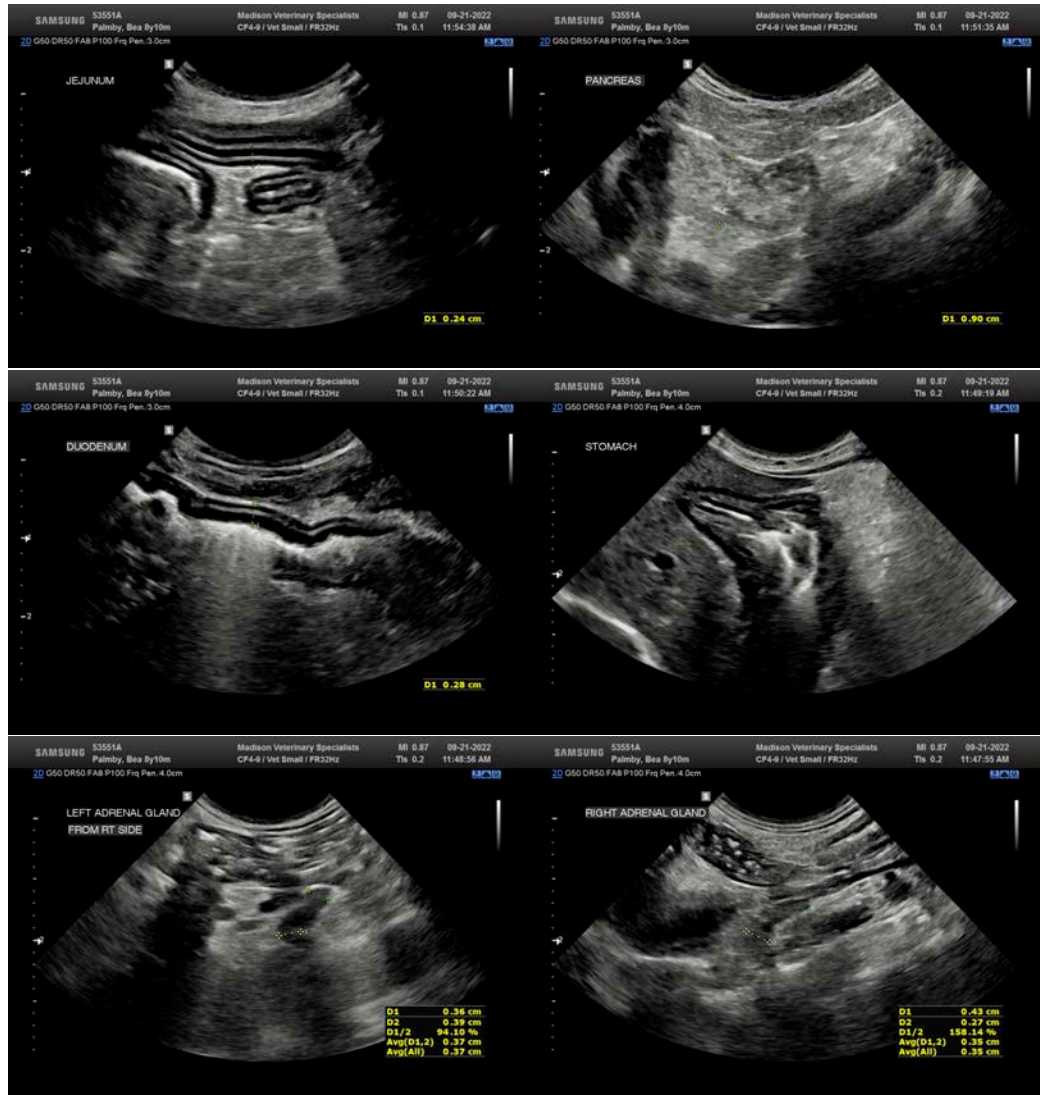
DATE

9/21/22

INTERPRETATION OF THE FINDINGS & FURTHER RECOMMENDATIONS

Today's scan is relatively normal. There are no large mass lesions and no nodules/mass lesions visualized associated with the pancreas. Your plan to evaluate cortisol levels and an insulin to glucose ratio is great. Additionally, I would consider a liver function test if lab work is not suggestive of an insulin secreting tumor or Addison's disease.

Recommend three view thoracic radiographs to evaluate for possible concurrent thoracic disease/involvement.



IMAGING PERFORMED BY

SVS Mobile Imaging CT 262-366-5970
fredgromalak@gmail.com



PATIENT

Bea Palmby 53551A

SPECIES

Canine

BREED

Yorkshire Terrier

SEX

Spayed Female

AGE

8 Years 10 Months

WEIGHT

2.24 kg

INTERPRETED BY

Kathleen Sennello DVM,
MS, Diplomate ACVIM
(Small Animal Internal
Medicine)

**IMAGING
PERFORMED BY**

Tom McNeill

HOSPITAL NAME

SVS Imaging CT

REFERRING VET

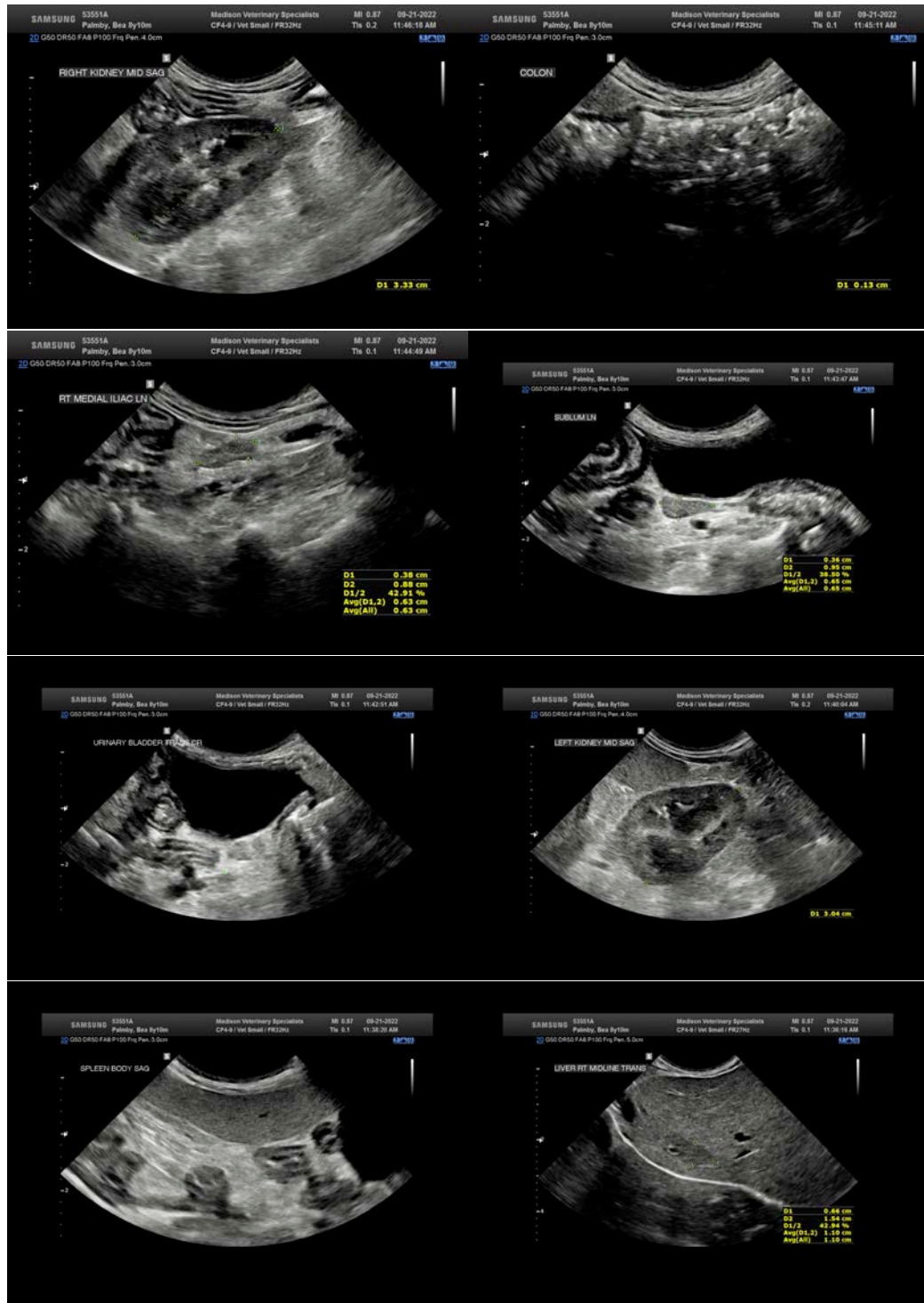
Dr. Tom

INVOICE

41448

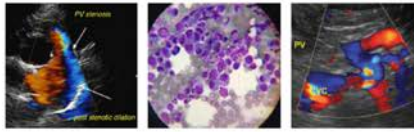
DATE

9/21/22



IMAGING PERFORMED BY

SVS Mobile Imaging CT 262 - 366 - 5970
fredgromalak@gmail.com



EDUCATIONAL TELECONSULTATION SERVICES™
1-800-838-4268 info@sonopath.com SonoPath.com

PATIENT

Bea Palmby 53551A

SPECIES

Canine

BREED

Yorkshire Terrier

SEX

Spayed Female

AGE

8 Years 10 Months

WEIGHT

2.24 kg

INTERPRETED BY

Kathleen Sennello DVM,
MS, Diplomate ACVIM
(Small Animal Internal
Medicine)

**IMAGING
PERFORMED BY**

Tom McNeill

HOSPITAL NAME

SVS Imaging CT

REFERRING VET

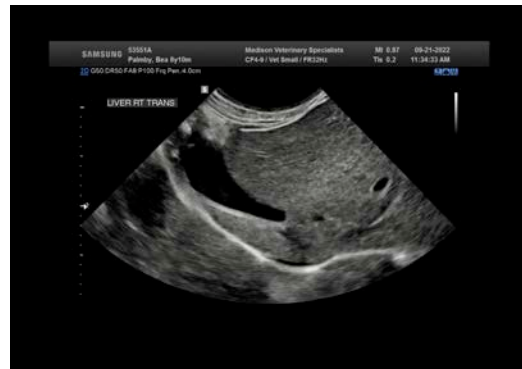Dr. Tom

INVOICE

41448

DATE

9/21/22



The information and recommendations provided are based on the images presented by the referring veterinarian/sonographer. No evaluation can be communicated regarding pathology that was not visible in the image/video clips provided.

Thank you for this referral. If the clinical or image interpretation does not parallel your findings or if I can be of any further assistance please contact me.

Kathleen Sennello DVM,MS, Diplomate ACVIM (Small animal Internal Medicine)

kathleen.sennello@sonopath.com