

PATIENT

Quil Johnson

SPECIES

Canine

BREED

Bichon Frise

SEX

Neutered Male

AGE

14 Years

WEIGHT

15 Pounds

INTERPRETED BY

Kathleen Sennello
DVM, MS,
Diplomate

IMAGING PERFORMED BY

Loetitia Saint-
HOSPITAL NAME

South Reno VH

REFERRING VET

Dr. Schmitt

INVOICE

25708

DATE

9/21/21

PRESENTING CLINICAL SIGNS

panting-vocalizing- mild butrophanol sedation but inadequate level of sedation- seen on emergency 3 days ago for Chief Complaint: Coughing History: Quil has been treated for high blood pressure. He is on amlodipine. Seen yesterday, blood pressure was 190 mmHg. He was not interested in breakfast. Normally sleeps a lot, seen breathing quickly. He has a chronic cough, had a small growth removed from neck many years ago. Owner concerned about tracheal breathing. Drinking a lot of water. Seemed dazed, weak while standing. 4/6 heart murmur (increased). Thoracic mass- check for mets in abdomen
Abnormal PE/Chem/CBC/UA Results: CBC: Neut 11.65; mono 2.01 PCV 44% TS 9.0g/dl Chemistry: BUN 68 TP 9.0 Alb 4.6 ALKP 951 ALT 223 UA: 1.018..... MASS Identified at the caudodorsal aspect of the thoracic cavity on lateral views. This mass is 3-4 ICS in length and approximately 50% of the thoracic height. This mass is to the right of midline on oblique VD view, occupying approximately 33% of the thoracic width. On VD the mass shows a midline caudal extension at the level of the interface with the oesophageal hiatus (red arrowhead). - Mild generalised unstructured interstitial pattern throughout the remainder of the lung. • The cardiac silhouette is normal in size and shape (green arrowheads). - Pulmonary vasculature is normal in size and shape (pink arrowheads). - A dorsal fusiform soft tissue opacity superimposes approximately 25% of the tracheal diameter (blue arrow). Abdomen: • The hepatic silhouette extends caudal to the costal arch with moderate rounding of the hepatic silhouette (orange arrows). - The small intestinal loops contain a mild amount of gas, all measuring within normal limits for size (red arrowheads). • The colon contains heterogeneous granular soft tissue and gas opaque material, and is normal in diameter (red arrows). - The bilateral renal silhouettes are normal in size and shape (green arrowheads). • The gastric lumen contains heterogeneous gas and soft tissue opaque material (blue arrow). Conclusions: Caudodorsal thoracic soft tissue mass: consider right caudal lung mass (such as primary lung tumour) DDx caudal mediastinal origin representing a hiatal hernia vs less likely an oesophageal mass (neoplastic) or obstruction. Hepatic enlargement: metabolic vs neoplastic (such as lymphoma vs histiocytic sarcoma) vs inflammatory, Redundant tracheal membrane vs collapsing trachea. Additional comments: The absence of a history of gastrointestinal signs makes an oesophageal obstruction of mass less likely. The absence of heterogeneous ingesta within this soft tissue mass makes a gastric origin such as hiatal hernia less likely. The obliquity of the VD view makes definitive lateralisation more difficult. Thoracic CT could be useful to better assess the mass,

ULTRASONOGRAPHIC EXAMINATION OF THE ABDOMEN

Urinary System

The urinary bladder is moderately distended with anechoic urine. The Bladder wall, trigone, ureteral papillae and visible urethra (to a depth of 2cm) appear normal with no evidence of wall thickening, mucosal irregularities, masses or cystic calculi.

The prostate is normal in size (0.63 cm) and shape for this neutered male dog. The parenchyma is homogenous and the external margins are smooth. The prostatic urethra appears normal with no evidence of irregularity, invasion, mass effect or calculi.

The left kidney has a normal shape and size (4.67 cm). Overall echogenicity is slightly hyperechoic with poor corticomedullary distinction and a typical 1:3 cortex:medulla ratio. There is no evidence of perinephric inflammation or effusion. There is no evidence of pyelectasia, nephroliths, infarcts or hydroureter. Renal vasculature is normal.

The right kidney has a normal shape and size (4.88 cm). Overall echogenicity is slightly hyperechoic with poor corticomedullary distinction and a typical 1:3 cortex:medulla ratio. There is no evidence of perinephric inflammation or effusion. There is no evidence of pyelectasia, nephroliths, infarcts or hydroureter. Renal vasculature is normal.



PATIENT

Quil Johnson

Adrenal Glands

The left adrenal gland is normal in size measuring 0.46 cm at the caudal pole. It is observed in its normal position cranial to the left renal artery. It is normal in appearance (uniformly hypoechoic) and shape with no evidence of a mass effect.

SPECIES

Canine

The right adrenal gland is normal in size measuring 0.50 cm at the caudal pole. It is observed in its normal position between the cranial aspect of the right kidney and the caudal vena cava. It is normal in appearance (uniformly hypoechoic) and shape with no evidence of a mass effect.

BREED

Bichon Frise

Spleen

The spleen is subjectively normal in size. The spleen echotexture is heterogenous and mottled, the splenic capsule is smooth with no irregularities. The blood flow through the hilus and splenic parenchyma appears normal. There is a 1.17 cm x 0.84 cm hypoechoic nodule within the body of the spleen. Additionally, there is a 2.3 cm mixed echogenic mass at the tail of the spleen, which appears to be deviating the capsule.

SEX

Neutered Male

AGE

14 Years

Liver

The liver is large in size, and normal in echogenicity with smooth peripheral margins. The parenchyma is heterogenous in echotexture with subtle, indistinct focal mottling. The visible portions of the vasculature and biliary tract appear normal. There is a 2.88 cm x 2.97 cm hypoechoic mass effect mid parenchyma in the liver.

WEIGHT

15 Pounds

The gall bladder lumen is moderately distended. The wall of the gall bladder is not thickened and has a smooth mucosal surface. There is a large amount of non-organized echogenic debris. The cystic and common bile ducts are normal/not visible.

INTERPRETED BY

Kathleen Sennello
DVM, MS,
Diplomate

Gastrointestinal

The stomach contains minimal luminal contents. It measures at a normal thickness of <0.7cm with some variability due to the presence of rugal folds. The distinction of the gastric wall layers is adequate and there is no impression of reduced peristaltic activity. No masses or focal lesions were observed.

IMAGING PERFORMED BY

Loetitia Saint-
HOSPITAL NAME

The visualized areas of duodenum, jejunum and ileum have a relatively uniform diameter with minimal fluid distension. Wall thickness is normal. Bowel loops follow a curvilinear path with distinct wall layering maintaining the typical 1:3 muscularis:mucosa layer ratio. Jejunum wall measures 0.32 cm. Visualized peristalsis appears appropriate. There were no focal lesions consistent with obstruction or a mass effect observed.

South Reno VH

The ileocecal junction was visualized and exhibited normal intact wall layering and is subjectively of normal thickness. Sections of colon are visualized with formed fecal material and gas shadowing distally. There is no observed focal or generalized colon wall thickening or loss of layering.

REFERRING VET

Dr. Schmitt

Pancreas

The pancreas is normal and isoechoic to surrounding mesentery. There is no evidence of nodules or cystic lesions. There is no evidence of regional mesenteric inflammation or fluid.

INVOICE

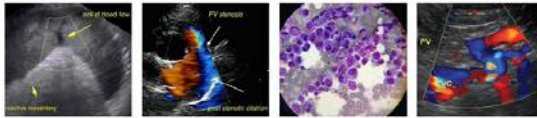
25708

Free Abdomen

Evaluation of the peritoneal cavity did not reveal any evidence of effusion, or subjective lymphadenomegaly. The Medial iliac nodes appear normal and there was no evidence of a caudal aortic thrombus at the bifurcation. The omentum is of normal uniform echogenicity.

DATE

9/21/21



PATIENT

Quil Johnson

Other

SPECIES

Canine

BREED

Bichon Frise

SEX

Neutered Male

AGE

14 Years

WEIGHT

15 Pounds

INTERPRETED BY

Kathleen Sennello
DVM, MS,
Diplomate

IMAGING PERFORMED BY

Loetitia Saint-
HOSPITAL NAME

South Reno VH

REFERRING VET

Dr. Schmitt

INVOICE

25708

DATE

9/21/21

There is a solid, hypochoic caudal thoracic mass present measuring 3.66 cm x 6.13 cm on the right side of the thorax.

PRIMARY FINDINGS

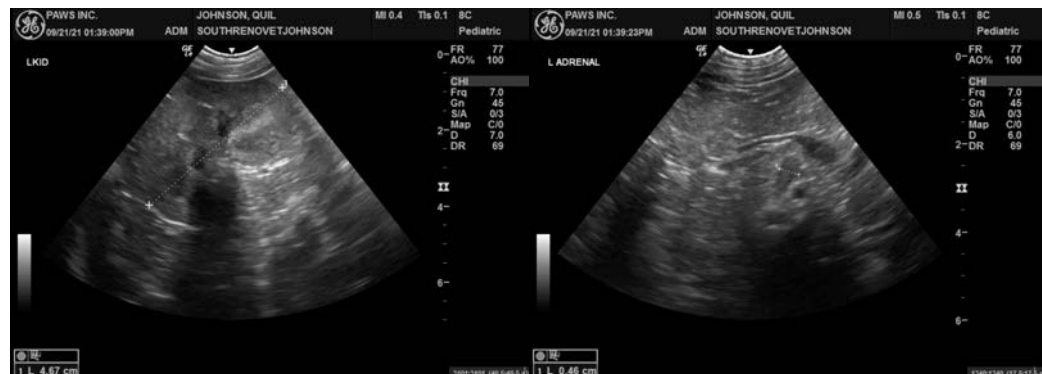
- Caudal right-sided solid thoracic mass – recommend fine needle aspirate.
- Mottled spleen with hypochoic nodule and larger mass effect towards the tail of the spleen – The diffuse splenic changes are non-specific and could be consistent with lymphoid hyperplasia, extramedullary hematopoiesis, infiltrative neoplasia, inflammation, other. Cytology or histopathology would be necessary to get a definitive diagnosis.
- Large, heterogeneous liver with ill-defined mass effect – The diffuse hepatic changes are non-specific and could be consistent with vacuolar hepatopathy, nodular hyperplasia, inflammatory/immune-mediated disease, fibrosis, extramedullary hematopoiesis, toxic hepatopathy (e.g., copper), infiltrative neoplasia (less likely) or other hepatopathy.
- Large gallbladder sludge – The significance of the aggregated gallbladder sludge is unclear. This could represent an early mucocele, cholestasis, or may be secondary to fasting. Recommend starting Ursodiol and monitoring of the gallbladder and liver values.

SECONDARY FINDINGS

- Decreased corticomedullary distinction both kidneys – The bilateral renal findings are consistent with age-related change.

INTERPRETATION OF THE FINDINGS & FURTHER RECOMMENDATIONS

The thoracic mass visualized on radiographs is evident on today's scan as well. I suspect a primary pulmonary mass, but advanced imaging (CT scan) would likely be necessary to definitively determine this. Ideally, consider fine needle aspirate at the time of CT (under anesthesia to prevent panting, etc.). Additionally, there is a mass effect associated with the spleen and the liver. These could be benign or malignant lesions and could be related to the thoracic mass or not. My suspicion is that they are unrelated, but cytology or histopathology of the lesions would be necessary to say for sure. If thoracic CT is considered, you could additionally consider scanning the abdomen to look for more subtle lesions than can easily be picked up by ultrasound, and you could consider a fine needle aspirate of the liver and spleen. Based on this information, surgical planning could be considered.





PATIENT

Quil Johnson

SPECIES

Canine

BREED

Bichon Frise

SEX

Neutered Male

AGE

14 Years

WEIGHT

15 Pounds

INTERPRETED BY

Kathleen Sennello
DVM, MS,
Diplomate

IMAGING PERFORMED BY

Loetitia Saint-
HOSPITAL NAME

South Reno VH

REFERRING VET

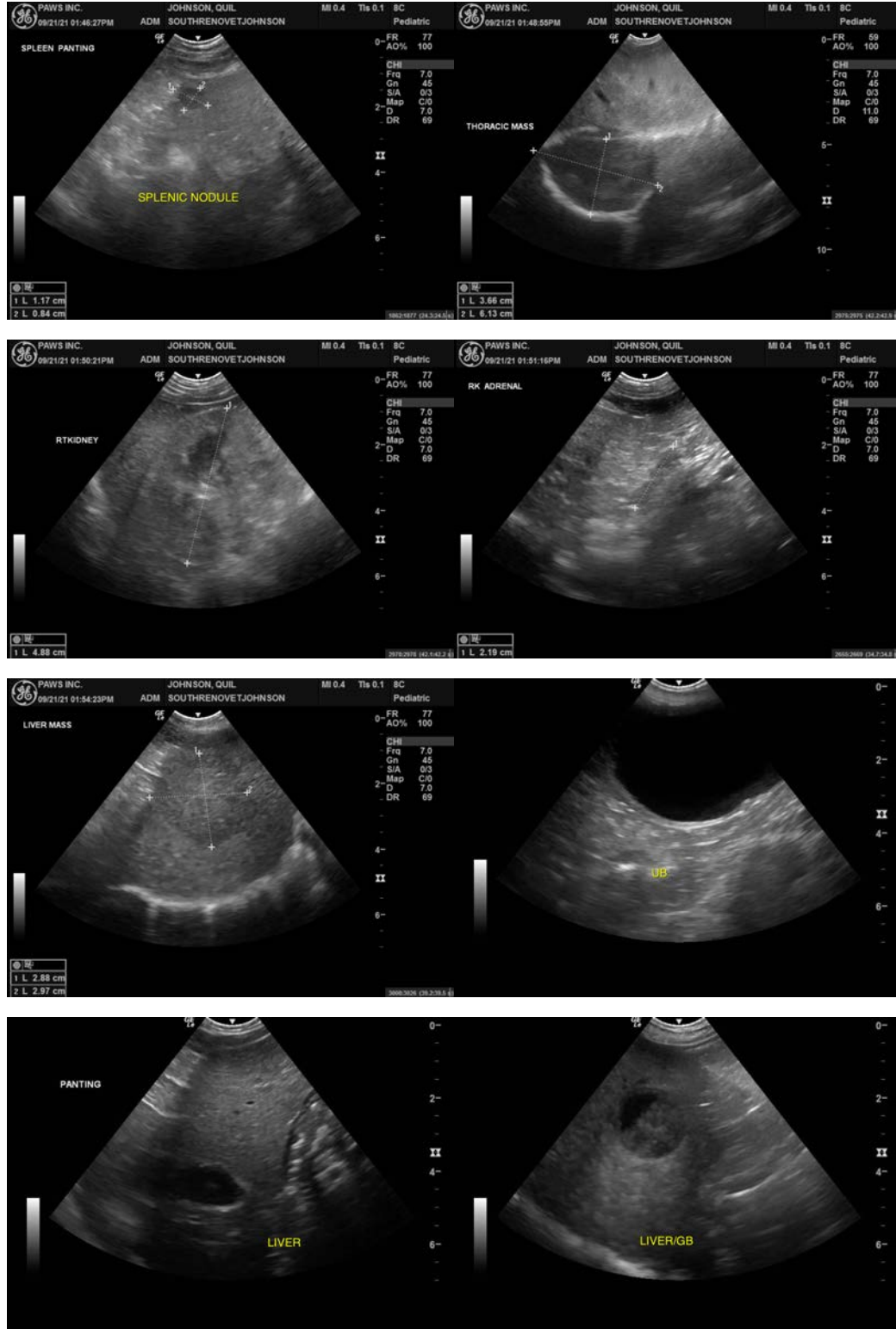
Dr. Schmitt

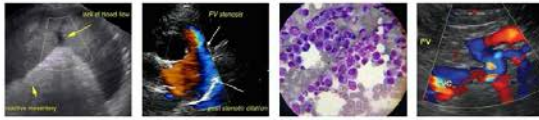
INVOICE

25708

DATE

9/21/21





PATIENT

Quil Johnson

SPECIES

Canine

BREED

Bichon Frise

SEX

Neutered Male

AGE

14 Years

WEIGHT

15 Pounds

**INTERPRETED
BY**

Kathleen Sennello
DVM, MS,
Diplomate

**IMAGING
PERFORMED
BY**

Loetitia Saint-
**HOSPITAL
NAME**

South Reno VH

**REFERRING
VET**

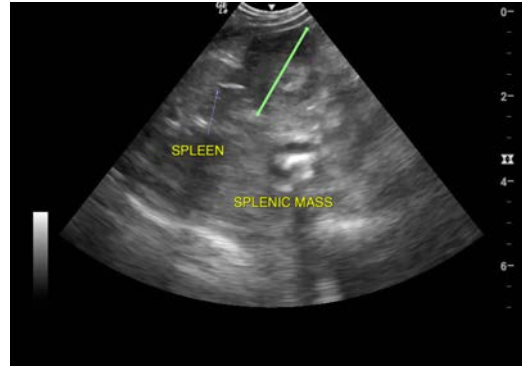
Dr. Schmitt

INVOICE

25708

DATE

9/21/21



The information and recommendations provided are based on the images presented by the referring veterinarian. No evaluation can be communicated regarding pathology that was not visible in the image/video clips provided.

Thank you for this referral. If the clinical or image interpretation does not parallel your findings or if I can be of any further assistance please contact me.

Kathleen Sennello DVM,MS, Diplomate ACVIM (Small animal Internal Medicine)

kathleen.sennello@sonopath.com