

**DATE**

9/21/21

PRESENTING CLINICAL SIGNS

History: panting; weight gain.

Current Medications: Rimadyl 1/2 100 bid, gabapentin 100 mg 1-3 BID.

Lab Results: alk 978, lymphopenia, UA 1.049, pH 6, proteinuria 3 plus, Glucose 117. Attached separately.

Radiographs Attached separately.

Date of Previous IntraPet Ultrasound: No previous IntraPet scans.

Sedation: Sedation not required for scan.

Stat Report: STAT report not requested by the veterinarian.

PATIENT

Daisy Kilburn

SPECIES

Canine

BREED

Beagle

SEX

Spayed Female

AGE

9/1/07

WEIGHT

56 lbs

INTERPRETED BY

Kathleen Sennello
DVM, MS, Diplomate
ACVIM (Small Animal
Internal Medicine)

HOSPITAL NAME

Greenbrier VC

REFERRING VET

Dr. Hubbard

INVOICE

91887

ULTRASONOGRAPHIC EXAMINATION OF THE ABDOMEN**Urinary System**

The urinary bladder is moderately distended with anechoic urine. The Bladder wall, trigone, ureteral papillae and visible urethra (to a depth of 2cm) appear normal with no evidence of wall thickening, mucosal irregularities, masses or cystic calculi.

The left kidney has a normal shape and size (6.1 cm). Overall echogenicity is slightly hyperechoic with poor corticomedullary distinction and a typical 1:3 cortex:medulla ratio. Small cortical cysts are visualized. There is no evidence of perinephric inflammation or effusion. There is no evidence of pyelectasia, nephroliths, infarcts or hydroureter. Renal vasculature is normal.

The right kidney has a normal shape and size (6.74 cm). Overall echogenicity is slightly hyperechoic with poor corticomedullary distinction and a typical 1:3 cortex:medulla ratio. There is no evidence of perinephric inflammation or effusion. There is no evidence of pyelectasia, nephroliths, infarcts or hydroureter. Renal vasculature is normal.

Adrenal Glands

The left adrenal gland is normal to borderline large in size measuring 0.67 cm at the caudal pole. It is observed in its normal position cranial to the left renal artery. It is normal in appearance (uniformly hypoechoic) and shape with no evidence of a mass effect.

The right adrenal gland is normal/borderline large in size measuring 0.79 cm at the caudal pole. It is observed in its normal position. It is somewhat irregular in appearance and shape. There is a hyperechoic, ill-defined nodule in the midbody measuring 1.07 x 0.83 cm. The remainder of the gland is normal in appearance.

Spleen

The spleen is subjectively normal in size, echotexture is homogenous, and the splenic capsule is smooth with no irregularities. The blood flow through the hilus and splenic parenchyma appears normal. There are multiple, small, hyperechoic foci visualized. The largest measured 0.42 cm. These are most consistent with benign myelolipomas.

Liver

The liver is subjectively normal in size, and echogenicity with smooth peripheral margins. The parenchyma is heterogenous in echotexture with subtle, indistinct focal mottling. The visible portions of the vasculature and biliary tract appear normal. No focal nodules or cystic lesions are observed. The gallbladder lumen is moderately distended. The wall of the gallbladder is not thickened and has a smooth mucosal surface. There is a moderate amount of non-organized echogenic debris. The cystic and common bile ducts are normal/not visible.

Gastrointestinal

The stomach contains minimal luminal contents. It measures at a normal thickness of <0.7cm with some variability due to the presence of rugal folds. The distinction of the gastric wall layers is adequate and there is no impression of reduced peristaltic activity. No masses or focal lesions were observed.

The visualized areas of duodenum, jejunum and ileum have a relatively uniform diameter with minimal fluid distension. Wall thickness is normal. Bowel loops follow a curvilinear path with distinct wall layering maintaining the typical 1:3 muscularis:mucosa layer ratio. The duodenum measured as normal and the jejunum measured as normal (0.32 cm). Visualized peristalsis appears appropriate. There were no focal lesions consistent with obstruction or a mass effect observed.

The ileocecal junction was visualized and exhibited normal intact wall layering and is subjectively of normal thickness. Sections of colon are visualized with formed fecal material and gas shadowing distally. There is no observed focal or generalized colon wall thickening or loss of layering.

Pancreas

The pancreas is normal and isoechoic to surrounding mesentery. There is no evidence of nodules or cystic lesions. There is no evidence of regional mesenteric inflammation or fluid.

Free Abdomen

Evaluation of the peritoneal cavity did not reveal any evidence of effusion, or subjective lymphadenomegaly. The Medial iliac nodes appear normal and there was no evidence of a caudal aortic thrombus at the bifurcation. The omentum is of normal uniform echogenicity, but there is a large amount of abdominal fat.

ULTRASONOGRAPHIC FINDINGS

PRIMARY FINDINGS:

- Borderline, bilateral adrenomegaly with a right-sided adrenal nodule. The bilateral adrenomegaly could be consistent with bilateral hyperplasia (e.g., secondary to pituitary-dependent hyperadrenocorticism), bilateral infiltrative neoplasia, inflammatory adrenal disease, other. Correlation with clinical findings is recommended. Additionally there is a focal nodule in the right adrenal gland. This could be consistent with a cancerous nodule (adenoma, carcinoma, pheochromocytoma), hyperplasia, inflammation, other.

SECONDARY FINDINGS:

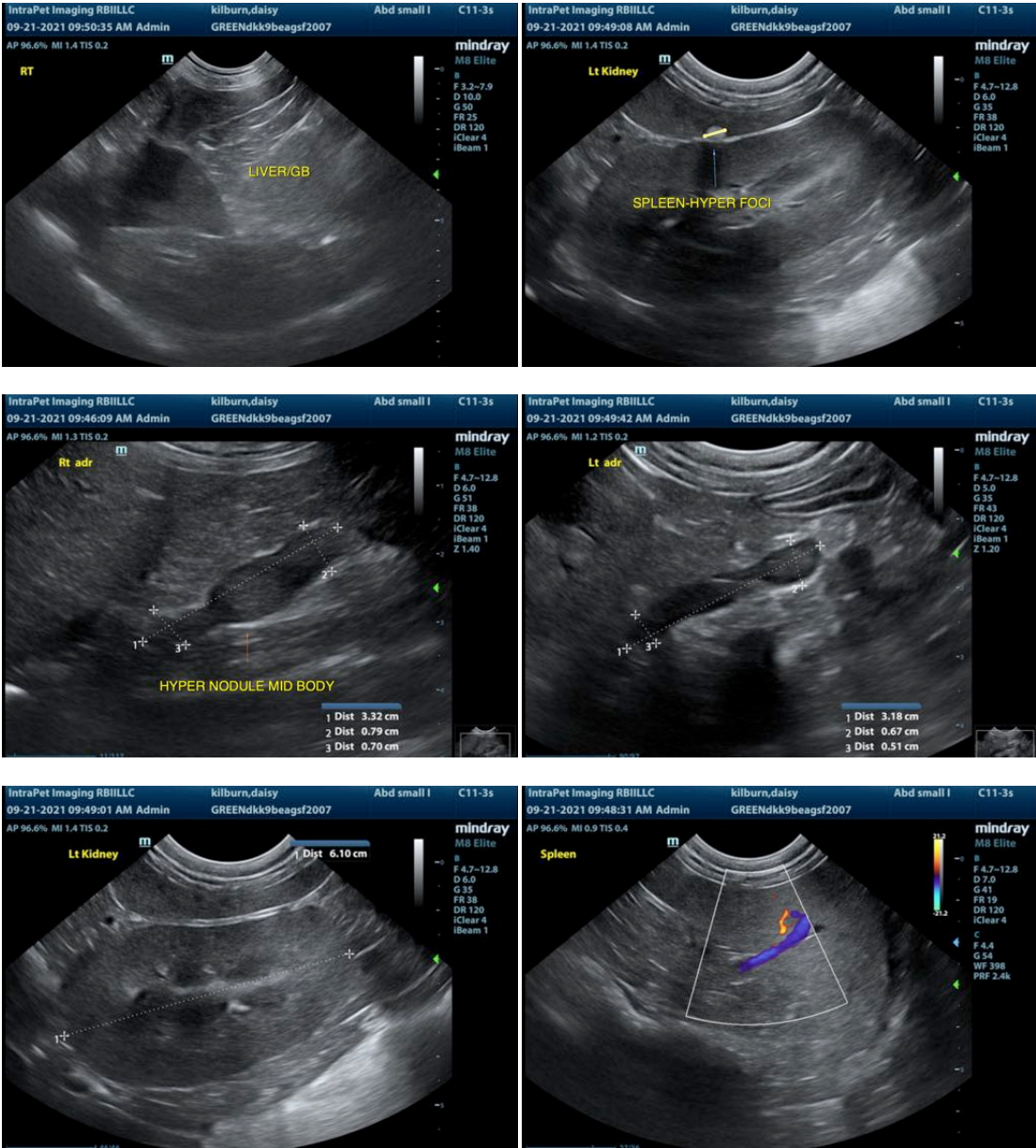
- Decreased corticomedullary distinction in both kidneys. Mild loss of corticomedullary distinction in both kidneys could be consistent with chronic degenerative disease or interstitial nephrosis.
- Mild gallbladder sludge. The significance of the aggregated gallbladder debris is unclear. This could represent an early mucocele, cholestasis, or may be secondary to fasting.

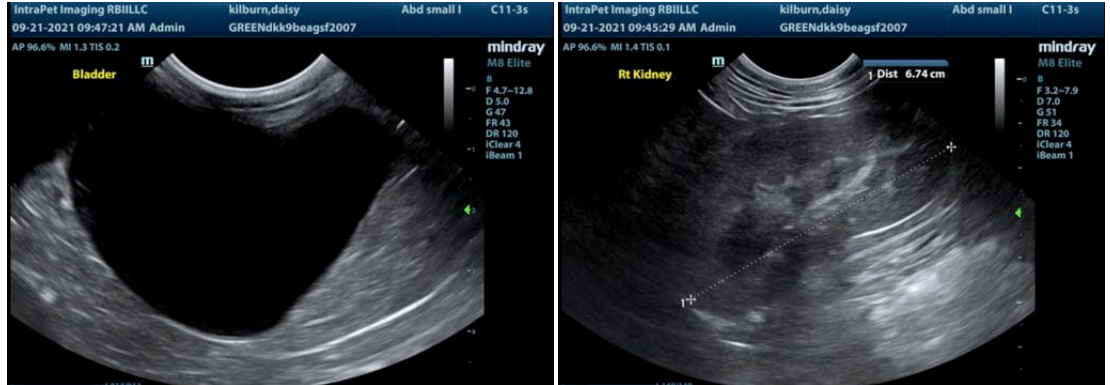
INTERPRETATION OF THE FINDINGS & FURTHER RECOMMENDATIONS

The adrenal glands are prominent and there is a nodule visualized in the right adrenal gland. This combined with the lab work and symptoms increases concern for possible endocrine disease. In these types of situations it can be very difficult to differentiate between pituitary dependent and adrenal dependent disease. The fact that the left adrenal gland is of normal size (it does not appear atrophied) makes a functional right-sided nodule slightly less likely. In this situation I would most likely consider:

- Blood pressure evaluation and if hypertension consider testing catecholamine levels for possible pheochromocytoma.

- If the clinical picture is consistent with Cushing's consider adrenal function testing. If testing is consistent with Cushing's I would consider proceeding with therapy while monitoring the right adrenal nodule with ultrasound (first recheck in 6-8 weeks then gradually extended intervals). If this appears to be growing I recommend surgical removal.
- I recommend three view thoracic radiographs.
- Consider urinalysis and culture and urine protein to creatinine level.





The information and recommendations provided are based on the images presented by the referring veterinarian. No evaluation can be communicated regarding pathology that was not visible in the image/video clips provided.

Thank you for this referral. If the clinical or image interpretation does not parallel your findings or if I can be of any further assistance please contact me.

Kathleen Sennello DVM,MS, Diplomate ACVIM (Small animal Internal Medicine)
kathleen.sennello@sonopath.com