**DATE PRESENTING CLINICAL SIGNS**

9/20/22 Poor appetite, weight loss, anemia (progressive, regenerative), thrombocytopenia, panhypoproteinemia, elevated ALP, hyperbilirubinemia, abnormal liver on rDVM US. Have not examined yet (10am consult 9/20).

PATIENT

Lacey Silbiger

Current Medications: Prednisone 20mg BID

SPECIES

Canine

Lab Results: Most recent labs 9/2: HCT 24% (macro, hypo, strongly regenerative w/411K retics and 12nRBC). PLT 135K (decreased on manual at 100K to adequate), neutrophils 23K, monocytes 2800. Albumin 2.5, globulin 2.2, ALP 414, t. bili 0.7. 8/30: UA--USG 1.048, pH 6.0, trace protein, 2+ bilirubin, 4+ bilirubin crystals. 8/29 (initial presentation): HCT 29% (no RBC indices or retics but 12nRBC/hpf), neutrophils 19K w/248 bands, PLT 88K (50-100K on smear w/macrophatelets present). Alb 1.7, glob 2.2, ALP 329, AST 67, bili 1.1. Lepto PCR negative.

BREED

Golden Retriever

Date of Previous IntraPet Ultrasound: No previous.

Sedation: Not required to complete full diagnostic ultrasound.

Stat Report: Not requested.

SEX

Spayed Female

ULTRASONOGRAPHIC EXAMINATION OF THE ABDOMEN**AGE**

1/30/11

Urinary System

The urinary bladder is moderately distended with anechoic urine. The Bladder wall, trigone, ureteral papillae and visible urethra (to a depth of 2cm) appear normal with no evidence of wall thickening, mucosal irregularities, masses or cystic calculi.

WEIGHT

31.8 kg

The left kidney has a normal shape and size (6.71 cm). Overall echogenicity is normal with adequate corticomedullary distinction and a typical 1:3 cortex:medulla ratio. There is no evidence of focal perinephric inflammation or effusion. There is no evidence of pyelectasia, nephroliths, infarcts or hydroureter. Renal vasculature is normal.

INTERPRETED BY

Kathleen Sennello DVM,
MS, Diplomate ACVIM
(Small Animal Internal
Medicine)

The right kidney has a normal shape and size (6.57 cm). Overall echogenicity is normal with adequate corticomedullary distinction and a typical 1:3 cortex:medulla ratio. There is no evidence of focal perinephric inflammation or effusion. There is no evidence of pyelectasia, nephroliths, infarcts or hydroureter. Renal vasculature is normal.

IMAGING PERFORMED BY

Andi Parkinson RDMS

Adrenal Glands

The left adrenal gland is normal in size measuring 0.61 cm at the caudal pole. It is observed in its normal position cranial to the left renal artery. It is normal in appearance (uniformly hypoechoic) and shape with no evidence of a mass effect.

HOSPITAL NAME

Nexus Vet Specialists

The right adrenal gland is normal in size measuring 0.61 cm at the caudal pole. It is observed in its normal position between the cranial aspect of the right kidney and the caudal vena cava. It is normal in appearance (uniformly hypoechoic) and shape with no evidence of a mass effect.

REFERRING VET

Dr. Steele

Spleen

The spleen is subjectively normal in size. The spleen echotexture is heterogenous and mildly mottled, the splenic capsule is smooth with no irregularities. The blood flow through the hilus and splenic parenchyma appears normal. There is an ill-defined hyperechoic nodule towards the tail of the spleen measuring 1.54 cm x 1.52 cm. Additionally, there is a hypoechoic ill-defined area in the caudal pole of the spleen, possibly consistent with a previous infarcts.

INVOICE

41424

Liver

The liver is subjectively normal in size with smooth peripheral margins. The parenchyma is hyperechoic and homogenous in echotexture. The visible portions of the vasculature and biliary tract appear normal. There

are too numerous to count, ill-defined hypoechoic nodules throughout the hepatic parenchyma, varying in size from 0.5-1.0 cm. One of the larger hypoechoic nodules is visualized at 1.5 cm x 1.01 cm.

The gallbladder lumen is moderately distended. The wall of the gall bladder is not thickened and has a smooth mucosal surface. Luminal contents are mild and primarily anechoic. The cystic and common bile ducts are normal/not visible.

Gastrointestinal

The stomach contains minimal luminal contents. It measures at a normal thickness of <0.7cm with some variability due to the presence of rugal folds. The distinction of the gastric wall layers is adequate and there is no impression of reduced peristaltic activity. No masses or focal lesions were observed.

The visualized areas of duodenum, jejunum and ileum have a relatively uniform diameter with minimal fluid distension. Wall thickness is normal. Bowel loops follow a curvilinear path with distinct wall layering maintaining the typical 1:3 muscularis:mucosa layer ratio. The duodenum measured as normal (between 0.3-0.5cm in wall thickness) and the jejunum measured as normal (between 0.2-0.47cm.) Visualized peristalsis appears appropriate. There were no focal lesions consistent with obstruction or a mass effect observed.

The ileocecal junction was visualized and exhibited normal intact wall layering and is subjectively of normal thickness. Sections of colon are visualized with formed fecal material and gas shadowing distally. There is no observed focal or generalized colon wall thickening or loss of layering.

Pancreas

The pancreas is prominent and mottled compared to the surrounding isoechoic mesentery. There is no evidence of nodules or cystic lesions. There is no evidence of regional mesenteric inflammation or fluid.

Free Abdomen

Evaluation of the peritoneal cavity did not reveal any evidence of effusion. There are significantly enlarged, hypoechoic mesenteric lymph nodes. One such lymph node measures at 1.94 cm x 6.38 cm. Another measures 1.8 cm x 4.5 cm. Additionally, the portal lymph node is visualized measuring 2.5 cm in diameter. The mesentery is hyperechoic around the enlarged lymph nodes.

PRIMARY FINDINGS

- Mildly mottled spleen with an ill-defined hyperechoic nodule and possible previous infarct – The diffuse splenic changes are non-specific and could be consistent with lymphoid hyperplasia, extramedullary hematopoiesis, infiltrative neoplasia, inflammation, other. Cytology or histopathology would be necessary to get a definitive diagnosis.
- Large, hyperechoic liver with numerous hypoechoic nodules – The diffuse hepatic changes are non-specific and can be seen with vacuolar hepatopathy, reactive change, nodular hyperplasia or, less likely, inflammatory/immune-mediated disease, infiltrative neoplasia, or other hepatopathy.
- Moderate to severe mesenteric lymphadenopathy – The severe mesenteric lymphadenopathy is most concerning for a neoplastic process, although you can see significant lymphadenopathy in some cases of autoimmune/inflammatory disease, infectious disease (tick born disease-such as bartonella, fungal infections, FIP (cats)) etc. A fine needle aspirate with cytology is recommended for further evaluation.

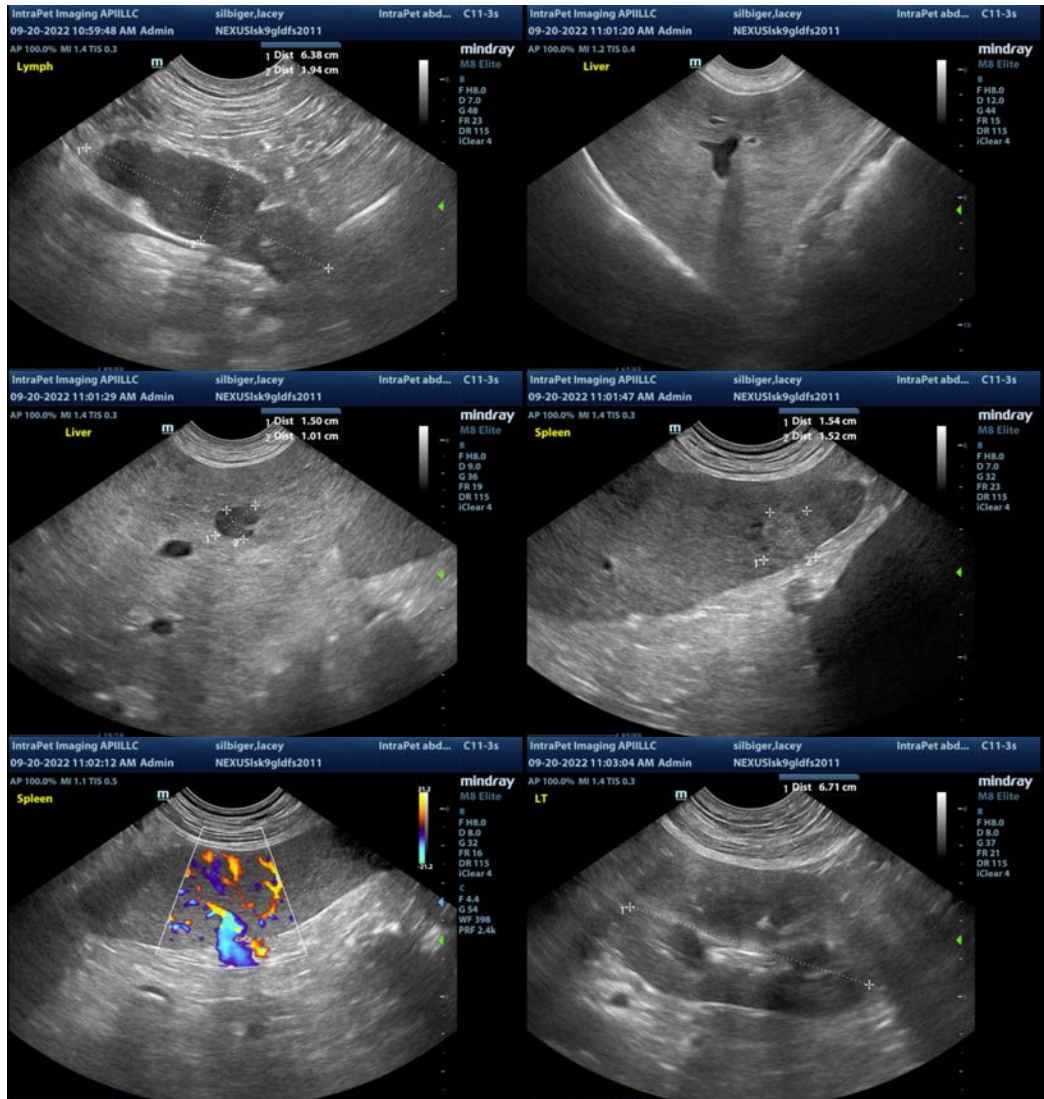
SECONDARY FINDINGS

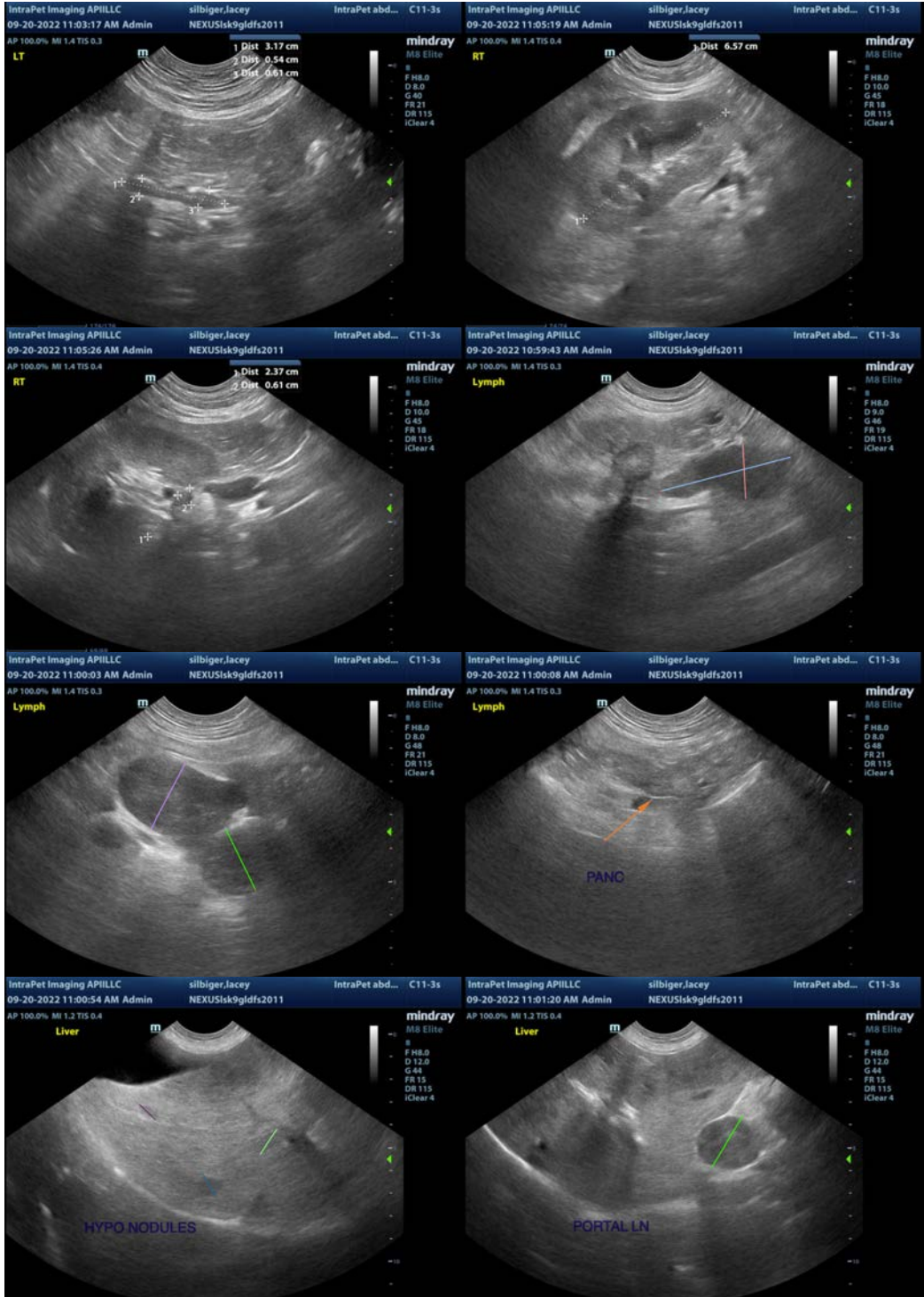
- Prominent, mottled pancreas – The pancreatic changes are most consistent with age-related parenchymal remodeling, potentially secondary to a prior inflammatory episode, early fibrosis or chronic pancreatitis.

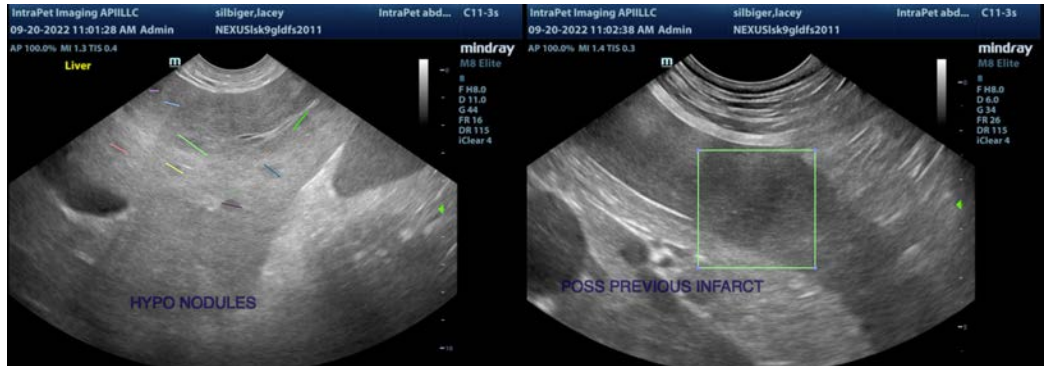
INTERPRETATION OF THE FINDINGS & FURTHER RECOMMENDATIONS

The significant lymphadenopathy and large, hyperechoic liver with hypoechoic nodules are the lesions of primary concern on today's scan.

Further diagnostic and therapeutic recommendations regarding this exam to be made by Dr. Cara Steele.







The information and recommendations provided are based on the images presented by the referring veterinarian/sonographer. No evaluation can be communicated regarding pathology that was not visible in the image/video clips provided.

Thank you for this referral. If the clinical or image interpretation does not parallel your findings or if I can be of any further assistance please contact me.

Kathleen Sennello DVM,MS, Diplomate ACVIM (Small animal Internal Medicine)
kathleen.sennello@sonopath.com