

**DATE PRESENTING CLINICAL SIGNS**

9/20/22

Long history of ravenous appetite, soft stool, wt. loss; has been under Tx elsewhere for hyperthyroid disease despite normal T4 (1.9). P presented on 9/12/22 for a second opinion and primary complaint of no improvement despite medication

PATIENT

Cricket Gould

Current Medications: discontinued felimazole (was getting 5mg PO BID) scheduled appt to teach Vit B12 injection.

SPECIES

Feline

Lab Results: T4 <0.4, BG 68 (72-175), WBC 24.1 (3.9-19), Hgb 8.7 (10.3-16.2), neut 20389 (2620-15170), monocyte 627 (40-530). GI panel: Spec fPL 3.4 (0.0 - 3.5 µg/L), Trypsin-like Immuno-reactivity (TLI) In Process, Cobalamin (B-12) <150 (276 - 1,425 ng/L), Folate 12.5 (8.9 - 19.9 ug/L)

Date of Previous IntraPet Ultrasound: No previous.

BREED

DSH

Sedation: Not required to complete full diagnostic ultrasound.

Stat Report: Not requested.

SEX

Neutered Male

ULTRASONOGRAPHIC EXAMINATION OF THE ABDOMEN**Urinary System**

The urinary bladder is moderately distended with mild primarily suspended echogenic debris present. The Bladder wall, trigone, ureteral papillae and visible urethra (to a depth of 2cm) appear normal with no evidence of wall thickening, mucosal irregularities, masses or calculi. Echogenic debris of this type can be associated with small crystals, cellular debris and proteinaceous debris.

AGE

5/5/10

The left kidney has a normal shape and size (3.99 cm). Overall echogenicity is slightly hyperechoic with mildly decreased corticomedullary distinction and a typical 1:3 cortex:medulla ratio. There is no evidence of focal perinephric inflammation or effusion. There is no evidence of pyelectasia, nephroliths, infarcts or hydroureter. Renal vasculature is normal.

WEIGHT

8 lb 3 oz

INTERPRETED BY

Kathleen Sennello DVM,
MS, Diplomate ACVIM
(Small Animal Internal
Medicine)

The right kidney has a normal shape and size (4.61 cm). Overall echogenicity is slightly hyperechoic with poor corticomedullary distinction and a typical 1:3 cortex:medulla ratio. There is no evidence of focal perinephric inflammation or effusion. There is no evidence of pyelectasia, nephroliths, infarcts or hydroureter. Renal vasculature is normal.

IMAGING PERFORMED BY

Andi Parkinson RDMS

Adrenal Glands

The left adrenal gland is normal in size measuring 0.30 cm at the caudal pole. It is observed in its normal position cranial to the left renal artery. It is normal in appearance (uniformly hypoechoic) and shape with no evidence of a mass effect.

HOSPITAL NAME

Timonium AH

The right adrenal gland is normal in size measuring 0.39 cm at the caudal pole. It is observed in its normal position between the cranial aspect of the right kidney and the caudal vena cava. It is normal in appearance (uniformly hypoechoic) and shape with no evidence of a mass effect.

REFERRING VET

Dr. Brand

Spleen

The spleen is subjectively normal in size (1.0 cm in width at the level of the hilus), echotexture is homogenous, and the splenic capsule is smooth with no irregularities. The blood flow through the hilus and splenic parenchyma appears normal. No focal parenchymal abnormalities are visualized.

INVOICE

41421

Liver

The liver is subjectively normal in size, and echogenicity with smooth peripheral margins. The parenchyma is homogenous echotexture. The visible portions of the vasculature and biliary tract appear normal. No focal nodules or cystic lesions are observed.

The gallbladder lumen is moderately distended. The wall of the gall bladder is not thickened and has a smooth mucosal surface. Luminal contents are mild and primarily anechoic. The cystic and common bile ducts are normal/not visible.

Gastrointestinal

The stomach contains minimal luminal contents. It measures at a normal thickness of <0.36cm with some variability due to the presence of rugal folds. The distinction of the gastric wall layers is adequate and there is no impression of reduced peristaltic activity. No masses or focal lesions were observed.

The visualized areas of duodenum, jejunum and ileum have a uniform diameter with minimal fluid distension. Wall thickness is normal to slightly increased. Bowel loops follow a typical curvilinear path with distinct wall layering, but some areas display a prominent muscularis layer which does not display the typical 1:3 muscularis:mucosa layer ratio. Jejunum wall measures 0.28 cm. Visualized peristalsis appears appropriate. There were no focal lesions consistent with obstruction or a mass effect observed.

The ileocecal junction was visualized and exhibited normal intact wall layering and is subjectively of normal thickness. Sections of colon are visualized with formed fecal material and gas shadowing distally. There is no observed focal or generalized colon wall thickening or loss of layering.

Pancreas

The pancreas is prominent and hypoechoic as compared to the surrounding isoechoic mesentery. There is no evidence of nodules or cystic lesions. There is no evidence of regional mesenteric inflammation or fluid.

Free Abdomen

There is scant free abdominal fluid. An occasional prominent mesenteric lymph node is visualized, one measures 0.51 cm in width, and the omentum is of normal echogenicity.

ULTRASONOGRAPHIC FINDINGS

- Echogenic debris visualized in the urinary bladder – The echogenic debris in the bladder lumen could be consistent with cells, crystals, and/or mucus.
- Decreased corticomedullary distinction in both kidneys – The bilateral renal findings are consistent with age-related change.
- Hypoechoic, prominent pancreas – The pancreatic changes are most consistent with age-related parenchymal remodeling, potentially secondary to a prior inflammatory episode, early fibrosis or chronic pancreatitis.
- Prominent muscularis layer to the small intestine – The small intestinal wall changes are most consistent with an inflammatory process (i.e., inflammatory bowel disease) with a low possibility of emerging lymphoma.
- Visible/mildly prominent mesenteric lymph nodes – The prominent abdominal lymph nodes are most consistent with reactive lymphadenitis or lymphoid hyperplasia. Neoplastic infiltration is considered less likely.

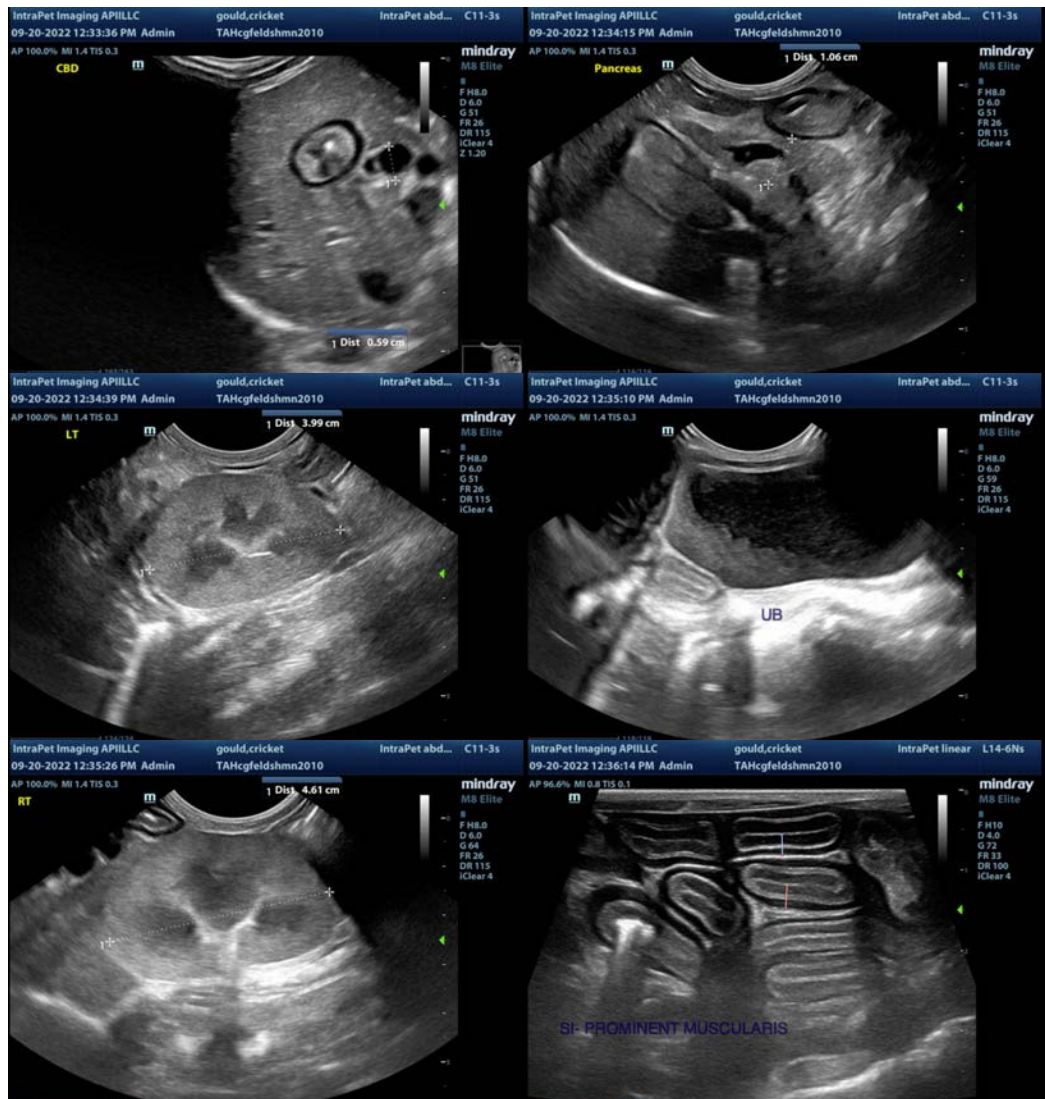
INTERPRETATION OF THE FINDINGS & FURTHER RECOMMENDATIONS

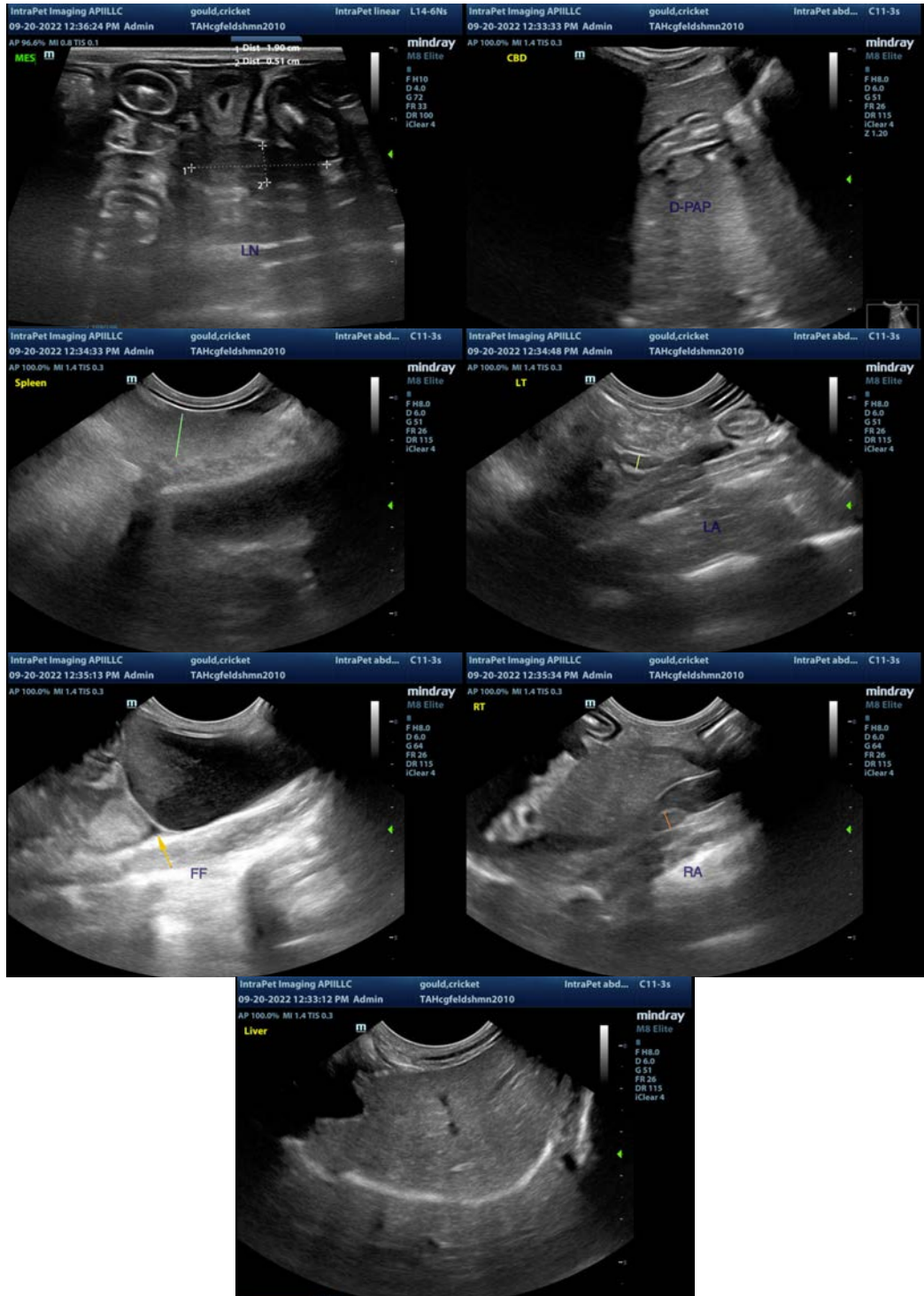
No focal lesions were visualized associated with the gastrointestinal tract, but the small bowel does appear somewhat “ropey” with prominent muscularis layer. This combined with the history of diarrhea and the low B12 levels is suggestive of small intestinal disease. Consider such differentials as exocrine pancreatic insufficiency (TLI pending), food allergy/dietary intolerance, dysbiosis, IBD, and less likely intestinal

neoplasia.

- Recommend a novel protein/hydrolyzed protein prescription diet.
- Recommend starting cobalamin therapy based on the low B12 levels.
- Recommend chronic probiotic therapy.
- If symptoms persist, consider obtaining GI biopsies.
- Recommend three view thoracic radiographs to evaluate for possible concurrent thoracic disease/involvement.

There is a moderate amount of echogenic debris visualized in the urinary bladder. Recommend urinalysis and culture.





The information and recommendations provided are based on the images presented by the referring veterinarian/sonographer. No evaluation can be communicated regarding pathology that was not visible in the image/video clips provided.

Thank you for this referral. If the clinical or image interpretation does not parallel your findings or if I can be of any further assistance please contact me.

Kathleen Sennello DVM,MS, Diplomate ACVIM (Small animal Internal Medicine)
kathleen.sennello@sonopath.com