

**DATE PRESENTING CLINICAL SIGNS**

9/2/21 Vomiting - 3 days - anorexia 3 days - history of eating things.

**PATIENT** Current Medications: Pantoprazole, Cerenia, Hydromorphone

Daisy Carty Lab Results: hypokalemia - corrected with fluids

Date of Previous IntraPet Ultrasound: No previous

Sedation: IV utilized for AUS

Stat Report: not requested

**SPECIES**

Canine

**ULTRASONOGRAPHIC EXAMINATION OF THE ABDOMEN****BREED** *Urinary System*

Labrador X

The urinary bladder is moderately distended with anechoic urine. The Bladder wall, trigone, ureteral papillae and visible urethra (to a depth of 2cm) appear normal with no evidence of wall thickening, mucosal irregularities, masses or cystic calculi.

**SEX**

Spayed Female

The left kidney has a normal shape and size (5.46 cm). Overall echogenicity is normal with adequate corticomedullary distinction and a typical 1:3 cortex:medulla ratio. There is no evidence of perinephric inflammation or effusion. There is no evidence of pyelectasia, nephroliths, infarcts or hydroureter. Renal vasculature is normal.

**AGE**

2015

The right kidney has a normal shape and size (6.11 cm). Overall echogenicity is normal with adequate corticomedullary distinction and a typical 1:3 cortex:medulla ratio. There is no evidence of perinephric inflammation or effusion. There is no evidence of pyelectasia, nephroliths, infarcts or hydroureter. Renal vasculature is normal.

**WEIGHT**

59.9 Pounds

*Adrenal Glands***INTERPRETED BY**

Kathleen Sennello DVM,  
MS, Diplomate ACVIM  
(Small Animal Internal  
Medicine)

The left adrenal gland is normal in size measuring 0.71 cm at the caudal pole. It is observed in its normal position cranial to the left renal artery. It is normal in appearance (uniformly hypoechoic) and shape with no evidence of a mass effect.

The right adrenal gland is normal in size measuring 0.69 cm at the caudal pole. It is observed in its normal position between the cranial aspect of the right kidney and the caudal vena cava. It is normal in appearance (uniformly hypoechoic) and shape with no evidence of a mass effect.

**HOSPITAL NAME**

Eastern AH

*Spleen*

The spleen is subjectively normal in size, echotexture is homogenous, and the splenic capsule is smooth with no irregularities. The blood flow through the hilus and splenic parenchyma appears normal. No focal parenchymal abnormalities are visualized.

**REFERRING VET**

Dr. Kaufman

*Liver*

The liver is subjectively normal in size and mildly hypoechoic. The parenchyma is mildly heterogenous in echotexture with subtle, indistinct focal mottling. The visible portions of the vasculature and biliary tract appear normal. No focal nodules or cystic lesions are observed.

**INVOICE**

25165

The gallbladder lumen is moderately distended. The wall of the gall bladder is not thickened and has a smooth mucosal surface. Luminal contents are primarily anechoic. The cystic and common bile ducts are normal/not visible.

*Gastrointestinal*

Visualization of the stomach is slightly impaired by intraluminal gas. Visualized portions of the stomach appear to have normal wall thickness at <0.7 cm with some variability due to the presence of rugal folds. The

distinction of gastric wall layering is adequate, and there is no impression of reduced peristaltic activity. No masses or focal lesions visualized.

The visualized areas of duodenum, jejunum and ileum have a relatively uniform diameter with minimal fluid distension. Wall thickness is normal. Bowel loops follow a curvilinear path with distinct wall layering maintaining the typical 1:3 muscularis:mucosa layer ratio. Duodenum wall measures 0.4 cm. Jejunum wall measured 0.32 cm. Visualized peristalsis appears appropriate. There were no focal lesions consistent with obstruction or a mass effect observed.

The ileocecal junction was visualized and exhibited normal intact wall layering and a prominent wall measured 0.25 cm. Sections of colon are visualized with minimal luminal contents and gas shadowing distally. There is no observed focal colon wall thickening or loss of layering.

### **Pancreas**

The pancreas is normal and isoechoic to surrounding mesentery. There is no evidence of nodules or cystic lesions. There is no evidence of regional mesenteric inflammation or fluid.

### **Free Abdomen**

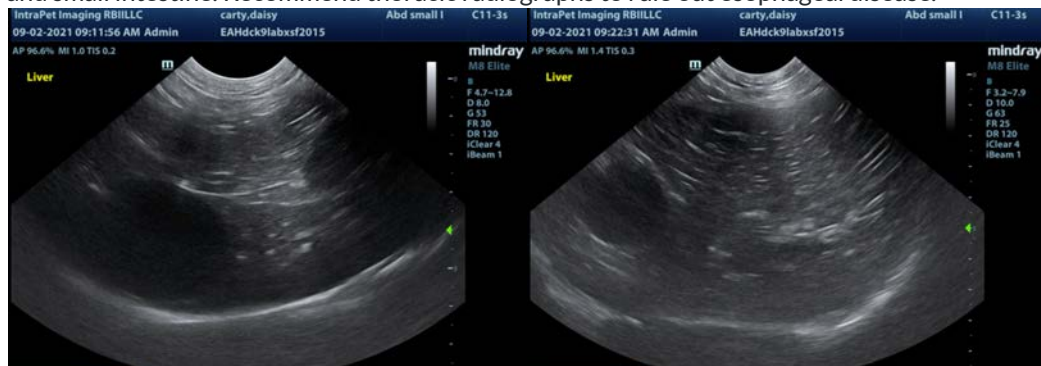Evaluation of the peritoneal cavity revealed scant effusion. No lymphadenomegaly. The Medial iliac nodes appear normal and there was no evidence of a caudal aortic thrombus at the bifurcation. The omentum is of normal uniform echogenicity.

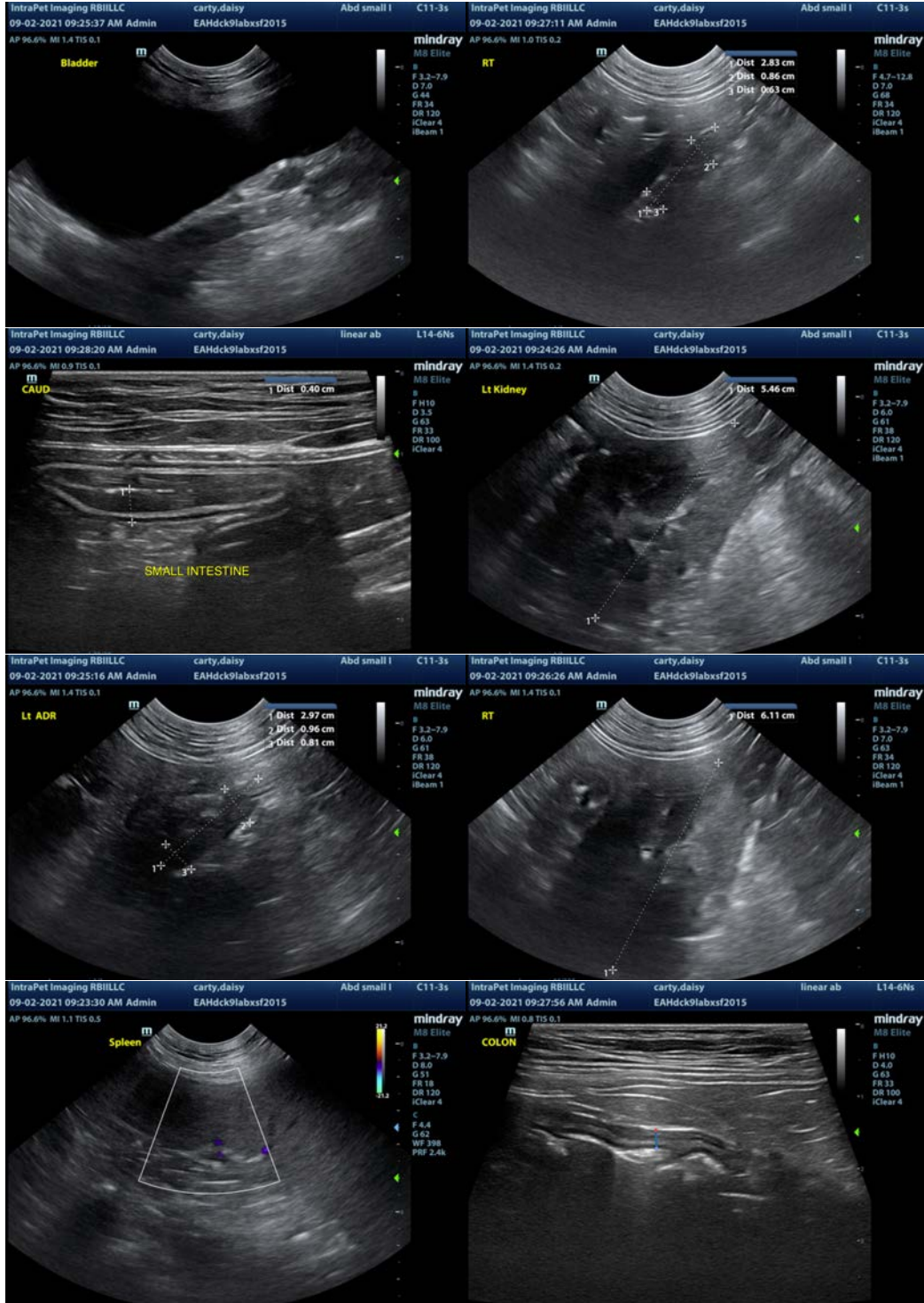
## **ULTRASONOGRAPHIC FINDINGS**

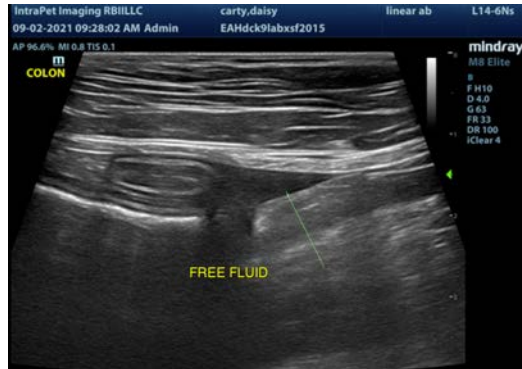- Mildly heterogeneous, hypoechoic liver – The diffuse hepatic changes are non-specific and could be consistent with vacuolar hepatopathy, nodular hyperplasia, inflammatory/immune-mediated disease, fibrosis, extramedullary hematopoiesis, toxic hepatopathy (e.g., copper), infiltrative neoplasia (less likely) or other hepatopathy. These findings are mild and subjective, and could be normal for this individual. Correlate with blood work.
- Scant free abdominal fluid – suspect this is secondary to localized inflammation in the GI tract. Continue monitoring and obtain sample for cytology and fluid analysis if the amount of fluid increases.

## **INTERPRETATION OF THE FINDINGS & FURTHER RECOMMENDATIONS**

The images visualized on today's scan appear relatively normal. An obvious obstruction or foreign material is not seen. Additionally, the changes reported are very mild. Recommend continued monitoring with serial radiographs. You could consider liver function test due to the low BUN and low-ish Albumin. If vomiting persists, exploratory may need to be considered. If this done, recommend obtaining biopsies of the stomach and small intestine. Recommend thoracic radiographs to rule out esophageal disease.







**The information and recommendations provided are based on the images presented by the referring veterinarian. No evaluation can be communicated regarding pathology that was not visible in the image/video clips provided.**

Thank you for this referral. If the clinical or image interpretation does not parallel your findings or if I can be of any further assistance please contact me.

Kathleen Sennello DVM,MS, Diplomate ACVIM (Small animal Internal Medicine)  
kathleen.sennello@sonopath.com