

IMAGING PERFORMED BY

IntraPet.com



SonoPath

Clinical Sonography & Telecytology

EDUCATIONAL TELECONSULTATION SERVICES™

1-800-838-4268 info@sonopath.com SonoPath.com

DATE PRESENTING CLINICAL SIGNS

9/15/22 Recurrent UTIs, palpable prostate on PE.

PATIENT Current Medications: None.

Luigi Feen

Lab Results: Rods on US 7/25/22.

Date of Previous IntraPet Ultrasound: No previous.

Sedation: Not required to complete full diagnostic ultrasound.

Stat Report: Not requested.

SPECIES

Canine

ULTRASONOGRAPHIC EXAMINATION OF THE ABDOMEN

BREED

JRT

SEX

Neutered Male

AGE

8/2/09

WEIGHT

24.8 Pounds

INTERPRETED BY

Kathleen Sennello DVM,
MS, Diplomate ACVIM
(Small Animal Internal
Medicine)

IMAGING PERFORMED BY

Stephanie Warga
RDMS, RVT

HOSPITAL NAME

Bay Country VH

REFERRING VET

Dr. McLean

INVOICE

41371

Urinary System

The urinary bladder is mildly distended with anechoic urine. The Bladder wall largely appears severely thickened and irregular with a maximal thickness of 1.4 cm. There is a small area apically that appears more normal in thickness with a smooth mucosal surface. This irregularity extends into the proximal urethra, which has a wall thickness of 0.42 cm and extends to the prostate (see prostate). This thickening involves the trigone region and the proximal urethra as well as the body of the urinary bladder.

The prostate is slightly prominent, measuring 1.6 cm in height in the sagittal view. Its margins are slightly irregular and the parenchyma is heterogeneous. Additionally, there are hyperechoic foci in the region of the prostatic urethra that could represent sandy debris/small stones within the urethra or mineralization of the prostatic tissue.

The left kidney has a normal shape and size (4.73 cm). Overall echogenicity is normal with adequate corticomedullary distinction and a typical 1:3 cortex:medulla ratio. There is no evidence of focal perinephric inflammation or effusion. There is no evidence of pyelectasia, nephroliths, infarcts or hydroureter. Renal vasculature is normal.

The right kidney has a normal shape and size (4.29 cm). Overall echogenicity is normal with adequate corticomedullary distinction and a typical 1:3 cortex:medulla ratio. There is no evidence of focal perinephric inflammation or effusion. There is no evidence of pyelectasia, nephroliths, infarcts or hydroureter. Renal vasculature is normal.

Adrenal Glands

The left adrenal gland is normal in size measuring 0.62 cm at the caudal pole. It is observed in its normal position cranial to the left renal artery. It is normal in appearance (uniformly hypoechoic) and shape with no evidence of a mass effect.

The right adrenal gland is normal in size measuring 0.81 cm at the caudal pole. It is observed in its normal position between the cranial aspect of the right kidney and the caudal vena cava. It is normal in appearance (uniformly hypoechoic) and shape with no evidence of a mass effect.

Spleen

The spleen is subjectively normal in size, echotexture is homogenous, and the splenic capsule is smooth with no irregularities. The blood flow through the hilus and splenic parenchyma appears normal. There are occasional ill-defined hyperechoic foci visualized within the parenchyma.

Liver

The liver is subjectively normal in size, and echogenicity with smooth peripheral margins. The parenchyma is homogenous echotexture. The visible portions of the vasculature and biliary tract appear normal. No focal nodules or cystic lesions are observed.

The gallbladder lumen is moderately distended. The wall of the gall bladder is not thickened and has a smooth mucosal surface. Luminal contents are mild and primarily anechoic. The cystic and common bile ducts are normal/not visible.

Gastrointestinal

The stomach contains minimal luminal contents. It measures at a normal thickness of <0.7cm with some variability due to the presence of rugal folds. The distinction of the gastric wall layers is adequate and there is no impression of reduced peristaltic activity. No masses or focal lesions were observed.

The visualized areas of duodenum, jejunum and ileum have a relatively uniform diameter with minimal fluid distension. Wall thickness is normal. Bowel loops follow a curvilinear path with distinct wall layering maintaining the typical 1:3 muscularis:mucosa layer ratio. Jejunum wall measures 0.31 cm. Visualized peristalsis appears appropriate. There were no focal lesions consistent with obstruction or a mass effect observed.

The ileocecal junction was visualized and exhibited normal intact wall layering and is subjectively of normal thickness. Sections of colon are visualized with formed fecal material and gas shadowing distally. There is no observed focal or generalized colon wall thickening or loss of layering.

Pancreas

The right limb of the pancreas is prominent and mottled compared to the surrounding isoechoic mesentery. There is no evidence of nodules or cystic lesions. There is no evidence of regional mesenteric inflammation or fluid.

Free Abdomen

Evaluation of the peritoneal cavity did not reveal any evidence of effusion, or subjective lymphadenomegaly. The Medial iliac nodes appear normal and there was no evidence of a caudal aortic thrombus at the bifurcation. The omentum is of normal uniform echogenicity.

Other

A brief view of the heart was submitted. No significant pericardial effusion was seen.

ULTRASONOGRAPHIC FINDINGS

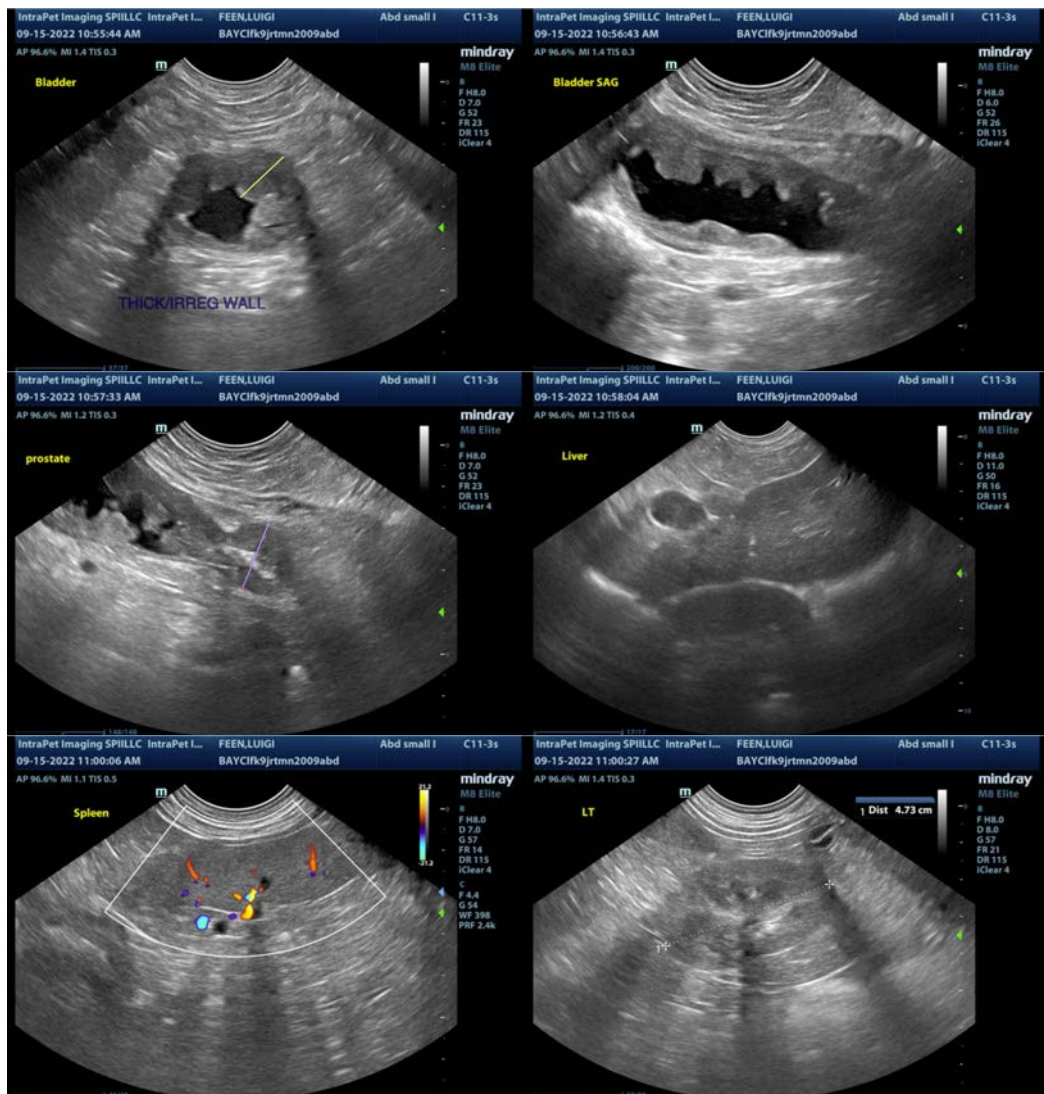
- Thickened, irregular bladder wall – There is a small area of more normal bladder visualized, which makes me concerned that this could be an extensive mass effect. The other differential would be diffuse severe cystitis.
- Prominent prostate with some mineralization – Correlate with the age of neutering. There is concern that the abnormal bladder tissue appears to coalesce into the urethra and connect to the prostate. There is concern for possible prostatic neoplasia.
- Ill-defined, hyperechoic foci in the spleen – The appearance of these lesions trends towards a benign etiology. Recommend continued monitoring.
- Prominent, mottled right limb of the pancreas – The pancreatic changes are most consistent with mild pancreatitis or a recent episode of pancreatic inflammation.

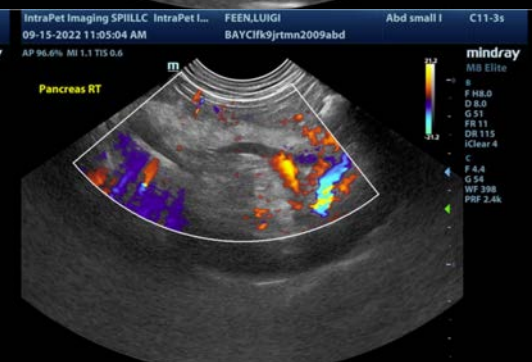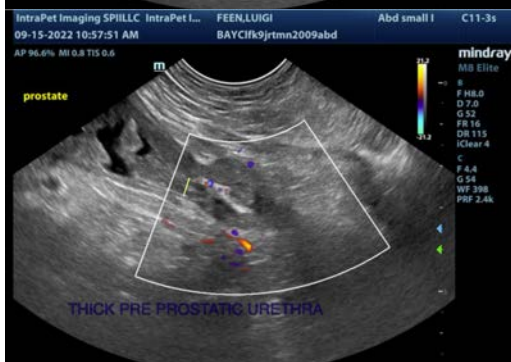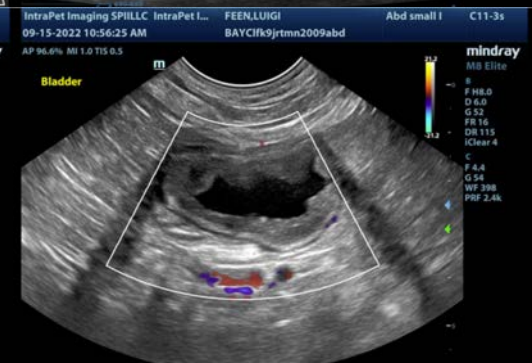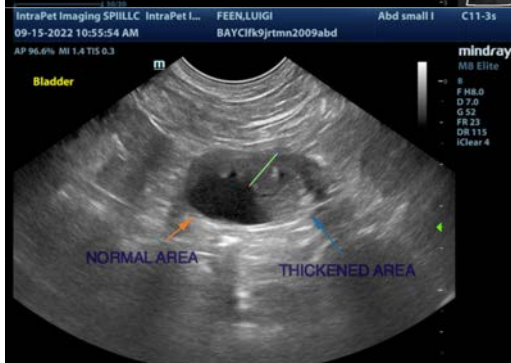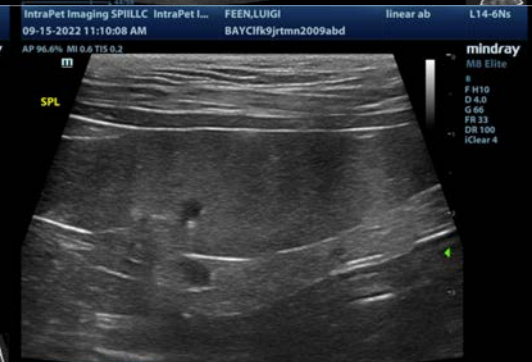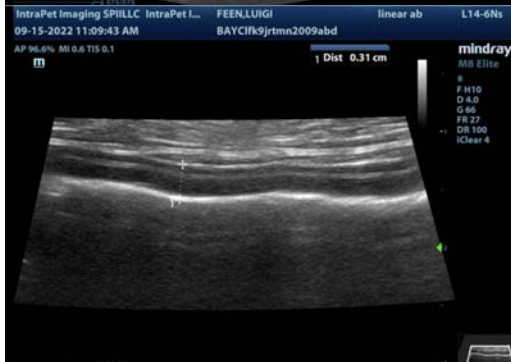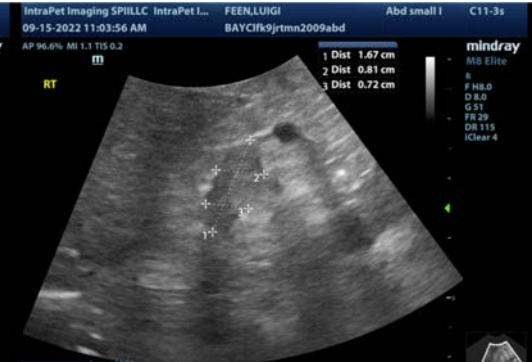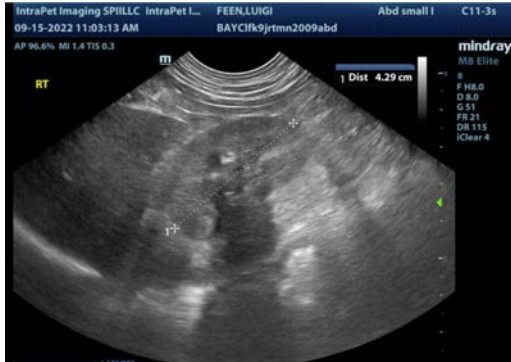INTERPRETATION OF THE FINDINGS & FURTHER RECOMMENDATIONS

The bladder wall is severely thickened and irregular. On initial evaluation, this looks like severe cystitis, but there is an area of more normal bladder wall, which makes me concerned that this is a very extensive bladder mass. Recommend traumatic catheterization with sampling for a culture. Recommend treatment of the

infection based on culture and sensitivity results and submitting cytology for evaluation of the bladder. If this is not diagnostic due to the concurrent cystitis, recommend resampling once the infection is under control. Additionally, you could consider a urine BRAF test. If this test is negative, it is non-diagnostic. If it is positive, it would increase the likelihood of a transitional cell carcinoma but is not definitively diagnostic. Additionally, you could consider a fine needle aspirate of the prostate or even the urinary bladder wall, but there would be risk for tracking neoplastic cells through the body wall.

If a diagnosis can be obtained, recommend consultation with a veterinary oncologist regarding treatment options and prognosis.





The information and recommendations provided are based on the images presented by the referring veterinarian/sonographer. No evaluation can be communicated regarding pathology that was not visible in the image/video clips provided.

Thank you for this referral. If the clinical or image interpretation does not parallel your findings or if I can be of any further assistance please contact me.

Kathleen Sennello DVM,MS, Diplomate ACVIM (Small animal Internal Medicine)
kathleen.sennello@sonopath.com