

**DATE**

9/15/21

PRESENTING CLINICAL SIGNS

History: urinary incontinence. Was being treated for a UTI but urination is not improving. P was urinating more while on Proin, so O stopped giving it. Blood work was repeated on 8/28/21. Concern for UTI or other cause of bladder inflammation (neo?). Liver value elevations are concerning for a new active hepatic process. Current Medications: Proin 50mg 1 tablet PO BID - started 8/13/21; D/C by owner.

PATIENT

Stanley Coles

Lab Results: (8/4/21): CBC: Neutrophilia & Monocytosis: likely inflammation and/or infection vs stress Leukogram; Chem: Slight increase in ALP: likely stress vs HAC vs liver disease; UA: UTI present; TT4: Low: hypothyroid vs euthyroid sick.

SPECIES

Canine

(8/28/21): CBC: RBC are WNL now (was anemic), Leukocytosis (Neutrophilia, monocytosis and eosinophilia) Improved from previous labs but still elevated; Chem: Elevated ALT and ALP (not previously increased); UA: Well concentrated, Proteinuria with active sediment so UPC wasn't run, Pyuria and hematuria; TT4: WNL. Radiographs: Not provided by the veterinarian.

BREED

Labrador Mix

Date of Previous IntraPet Ultrasound: 9-1-2021.

Sedation: Sedation not required for scan.

Stat Report: STAT report not requested by the veterinarian.

SEX

Neutered male

ULTRASONOGRAPHIC EXAMINATION OF THE ABDOMEN**Urinary System****AGE**

1/7/09

The urinary bladder is moderately distended with echogenic urine and dependent debris. The apical bladder wall is mildly thickened and progressively becomes more abnormal as it reaches the trigone regions, which becomes severely thickened creating a mass effect. This extends into the proximal urethra with irregular, thickened mucosa. An external diameter of the proximal urethra was 2.86 cm. This, irregular tissue is mineralized in some areas and is contiguous with a large, abnormal, irregular, mineralized prostate.

WEIGHT

108.8 lbs

The prostate is large in size and measured 4.1 cm in diameter on the sagittal view. It has irregular margins and very irregular parenchyma. It is contiguous with greatly thickened, irregular urethra. Areas of mineralization are present in the tissue. The findings are most consistent with a prostatic mass, which is contiguous with urethral and trigonal mass.

INTERPRETED BY

Kathleen Sennello
DVM, MS, Diplomate
ACVIM (Small Animal
Internal Medicine)

The left kidney has a normal shape and size (7.6 cm). Overall echogenicity is normal with adequate corticomedullary distinction and a typical 1:3 cortex:medulla ratio. There is no evidence of perinephric inflammation or effusion. There is no evidence of pyelectasia, nephroliths, infarcts or hydronephrosis. Renal vasculature is normal.

HOSPITAL NAME

Taylorsville VC

The right kidney is somewhat rounded and abnormal in shape. It measures slightly enlarged at 8.24 cm. The overall echogenicity is increased and there is severe pyelectasia that extended up into the calices causing signs of early hydronephrosis. Pyelectasia measures at 1.7 cm.

REFERRING VET

Dr. Bray

Adrenal Glands

The left adrenal gland is normal in size measuring 0.68 cm at the caudal pole It is observed in its normal position cranial to the left renal artery. It is normal in appearance (uniformly hypoechoic) and shape with no evidence of a mass effect.

INVOICE

91837

The right adrenal gland is normal in size measuring 0.78 cm at the caudal pole It is observed in its normal position between the cranial aspect of the right kidney and the caudal vena cava. It is normal in appearance (uniformly hypoechoic) and shape with no evidence of a mass effect.

Spleen

The spleen was surgically removed on 8/19/17.

Liver

The liver is subjectively normal in size, and echogenicity with smooth peripheral margins. The parenchyma is homogenous echotexture. The visible portions of the vasculature and biliary tract appear normal. No focal nodules or cystic lesions are observed. The gallbladder lumen is moderately distended. The wall of the gall bladder is not thickened and has a smooth mucosal surface. Luminal contents are primarily anechoic. The cystic and common bile ducts are normal/not visible.

Gastrointestinal

The stomach contains minimal luminal contents. It measures at a normal thickness of <0.7cm with some variability due to the presence of rugal folds. The distinction of the gastric wall layers is adequate and there is no impression of reduced peristaltic activity. No masses or focal lesions were observed.

The visualized areas of duodenum, jejunum and ileum have a relatively uniform diameter with minimal fluid distension. Wall thickness is normal. Bowel loops follow a curvilinear path with distinct wall layering maintaining the typical 1:3 muscularis:mucosa layer ratio. The duodenum measured as normal (between 0.3-0.5cm in wall thickness) and the jejunum measured as normal (between 0.2-0.47cm.) Visualized peristalsis appears appropriate. There were no focal lesions consistent with obstruction or a mass effect observed.

The ileocecal junction was visualized and exhibited normal intact wall layering and is subjectively of normal thickness. Sections of colon are visualized with formed fecal material and gas shadowing distally. There is no observed focal or generalized colon wall thickening or loss of layering.

Pancreas

The pancreas is normal and isoechoic to surrounding mesentery. There is no evidence of nodules or cystic lesions. There is no evidence of regional mesenteric inflammation or fluid.

Free Abdomen

Evaluation of the peritoneal cavity did not reveal any evidence of effusion, or subjective lymphadenomegaly. The Medial iliac nodes appear normal and there was no evidence of a caudal aortic thrombus at the bifurcation. The omentum is of normal uniform echogenicity.

ULTRASONOGRAPHIC FINDINGS

PRIMARY FINDINGS:

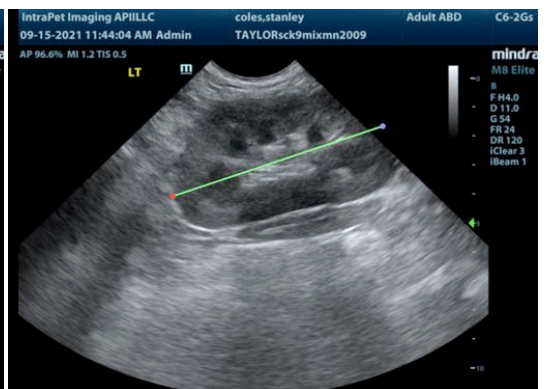
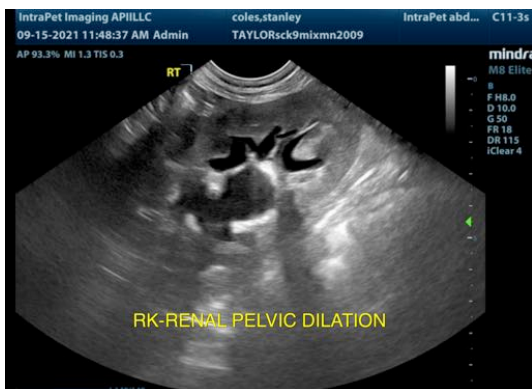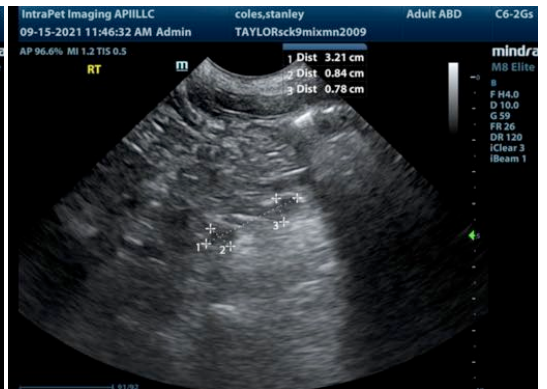
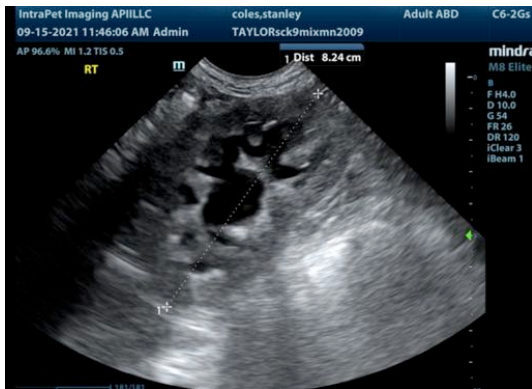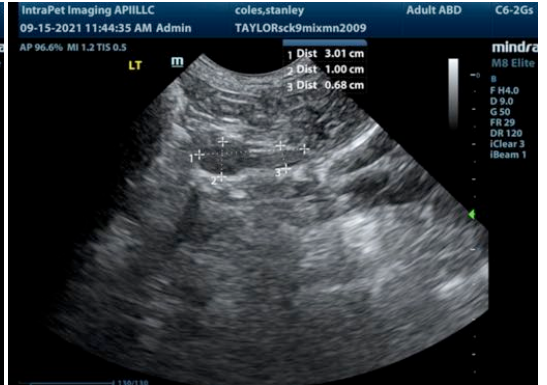
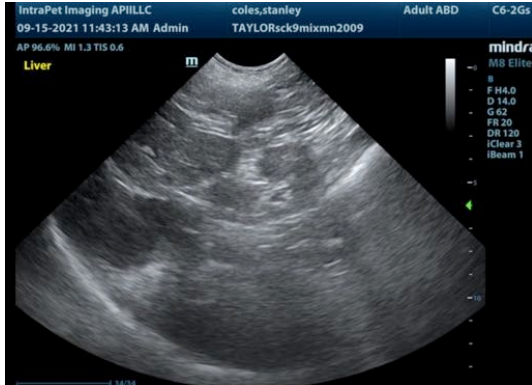
- Large mass involving the trigone, proximal urethra and prostate. The findings are most consistent with the carcinoma or other neoplastic process.
- Early hydronephrosis of the right kidney. The findings are supportive of an obstructive process to the right kidney (likely due to mass in the trigone area).

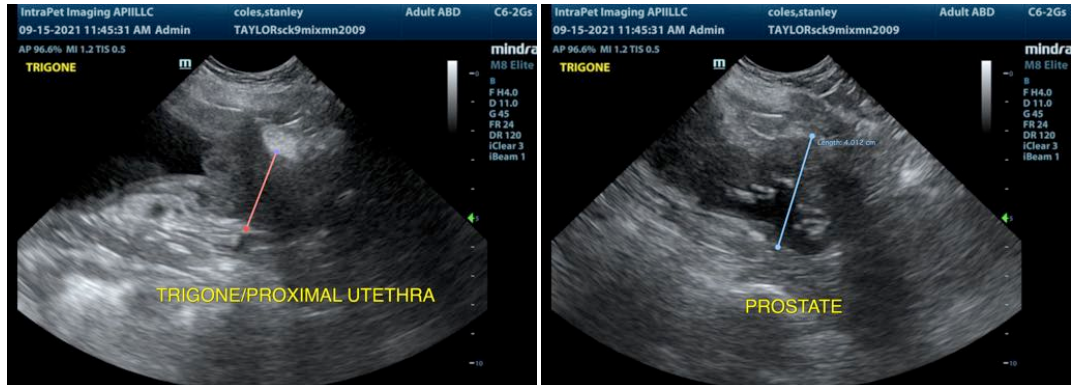
SECONDARY FINDINGS:

- No spleen. Splenectomy 8/9/17.

INTERPRETATION OF THE FINDINGS & FURTHER RECOMMENDATIONS

The previously visualized urethra bladder and prostatic mass is still apparent and appears to have progressed somewhat as now the right kidney appears obstructed. This is unlikely to be a surgical lesion. Consider FNA of the prostate or traumatic catheterization. Alternately a positive BRAF mutation test is likely diagnostic enough to confirm the cancerous process. I recommend three view thoracic radiographs and referral to a veterinarian oncologist for treatment recommendations.





The information and recommendations provided are based on the images presented by the referring veterinarian. No evaluation can be communicated regarding pathology that was not visible in the image/video clips provided.

Thank you for this referral. If the clinical or image interpretation does not parallel your findings or if I can be of any further assistance please contact me.

Kathleen Sennello DVM,MS, Diplomate ACVIM (Small animal Internal Medicine)
kathleen.sennello@sonopath.com