

**DATE**

9/15/21

PRESENTING CLINICAL SIGNS

History: presented to TVC for the first time on 9/7/21 for discharge from eyes. BCS is a 3/9 concern for neoplasia.

PATIENT

Hercules Dunbar

Current Medications: BNP – OU, Tacrolimus OU BID – Lifetime, Celluvisc - OTC until Tacrolimus arrives, Cephalexin 500mg 2 capsules BID until recheck in 2 weeks, Gabapentin 100mg 2 tab SID, Rimadyl 75mg SID. Lab Results: Severely elevated neutrophil count @ 41943 (2940-12670)- concern for organ abscess; Elevated calcium- neoplastic vs postprandial; Hypoalbumemia with elevated UPC- protein loss through kidneys +/- liver dysfunction; Total T4 slightly low @ 0.8 (1-4)- suspect normal for p.

SPECIES

Canine

Radiographs: Not provided by the veterinarian.

Date of Previous IntraPet Ultrasound: No previous IntraPet scans.

Sedation: Sedation not required for scan.

Stat Report: STAT report not requested by the veterinarian.

BREED

Rottweiler

ULTRASONOGRAPHIC EXAMINATION OF THE ABDOMEN**Urinary System****SEX**

Neutered male

The urinary bladder is moderately distended with anechoic urine and echogenic debris. The Bladder wall, trigone, ureteral papillae and visible urethra (to a depth of 2cm) appear normal with no evidence of wall thickening, mucosal irregularities or masses. There is a thin line of mineralized shadowing sandy debris in the dependent portion of the urinary bladder.

AGE

3/1/12

The prostate is normal in size and shape for this neutered male dog. The parenchyma is homogenous and the external margins are smooth. The prostatic urethra appears normal with no evidence of irregularity, invasion, mass effect or calculi.

WEIGHT

78 lbs

The left kidney has a normal shape and size (7.48 cm). Overall echogenicity is slightly hyperechoic with poor corticomedullary distinction and a typical 1:3 cortex:medulla ratio. There is no evidence of perinephric inflammation or effusion. Small non-obstructive nephroliths were noted in the left kidney. There is no evidence of pyelectasia, infarcts or hydroureter. Renal vasculature is normal.

INTERPRETED BY

Kathleen Sennello
DVM, MS, Diplomate
ACVIM (Small Animal
Internal Medicine)

The right kidney has a normal shape and size (7.8 cm). Overall echogenicity is slightly hyperechoic with poor corticomedullary distinction and a typical 1:3 cortex:medulla ratio. There is no evidence of perinephric inflammation or effusion. Small non-obstructive nephroliths were noted in the right kidney. There is no evidence of pyelectasia, infarcts or hydroureter. Renal vasculature is normal.

HOSPITAL NAME

Taylorsville VC

Adrenal Glands

The left adrenal gland is normal in size measuring 0.69 cm at the caudal pole It is observed in its normal position cranial to the left renal artery. It is normal in appearance (uniformly hypoechoic) and shape with no evidence of a mass effect.

REFERRING VET

Dr. Earp

The right adrenal gland is normal in size measuring 0.84 cm at the caudal pole It is observed in its normal position between the cranial aspect of the right kidney and the caudal vena cava. It is normal in appearance (uniformly hypoechoic) and shape with no evidence of a mass effect.

INVOICE

91838

Spleen

The spleen is subjectively normal in size, echotexture is homogenous, and the splenic capsule is smooth with no irregularities. The blood flow through the hilus and splenic parenchyma appears normal. No focal parenchymal abnormalities are visualized.

Liver

The liver is subjectively normal in size, and echogenicity with smooth peripheral margins. The parenchyma is heterogenous in echotexture with subtle, indistinct focal mottling. The visible portions of the vasculature and biliary tract appear normal. No focal nodules or cystic lesions are observed. The gallbladder lumen is moderately distended. The wall of the gall bladder is not thickened and has a smooth mucosal surface. Luminal contents are primarily anechoic. The cystic and common bile ducts are normal/not visible.

Gastrointestinal

The stomach contains minimal luminal contents. It measures at a normal thickness of <0.7cm with some variability due to the presence of rugal folds. The distinction of the gastric wall layers is adequate and there is no impression of reduced peristaltic activity. No masses or focal lesions were observed.

The visualized areas of duodenum, jejunum and ileum have a relatively uniform diameter with minimal fluid distension. Wall thickness is normal. Bowel loops follow a curvilinear path with distinct wall layering maintaining the typical 1:3 muscularis:mucosa layer ratio. The duodenum measured as normal (between 0.3-0.5cm in wall thickness) and the jejunum measured as normal (between 0.2-0.47cm.) Visualized peristalsis appears appropriate. There were no focal lesions consistent with obstruction or a mass effect observed.

The ileocecal junction was visualized and exhibited normal intact wall layering and is subjectively of normal thickness. Sections of colon are visualized with formed fecal material and gas shadowing distally. There is no observed focal or generalized colon wall thickening or loss of layering.

Pancreas

The pancreas is normal and isoechoic to surrounding mesentery. There is no evidence of nodules or cystic lesions. There is no evidence of regional mesenteric inflammation or fluid.

Free Abdomen

Evaluation of the peritoneal cavity did not reveal any evidence of effusion, or subjective lymphadenomegaly. The Medial iliac nodes appear normal and there was no evidence of a caudal aortic thrombus at the bifurcation. The omentum is of normal uniform echogenicity.

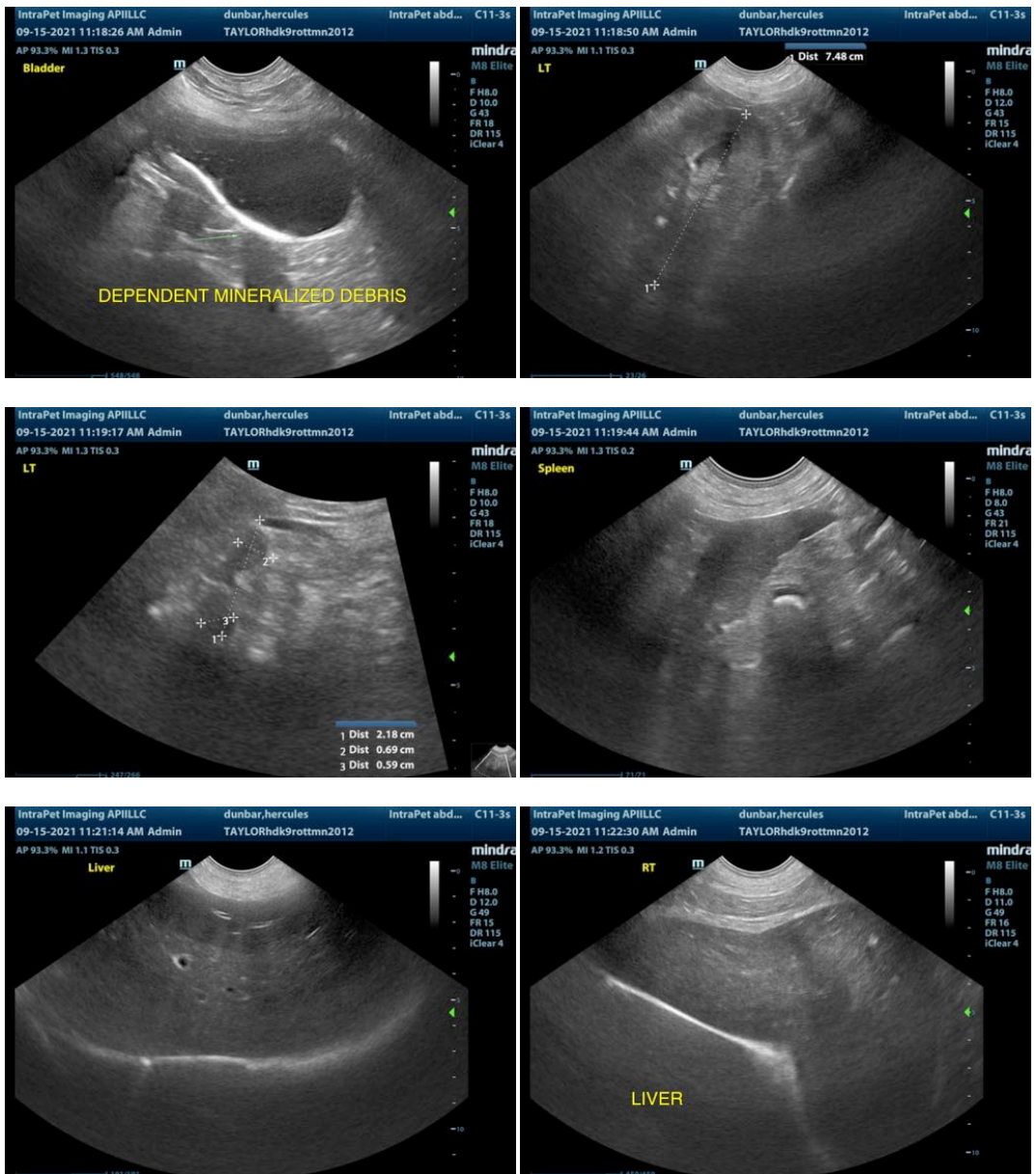
ULTRASONOGRAPHIC FINDINGS

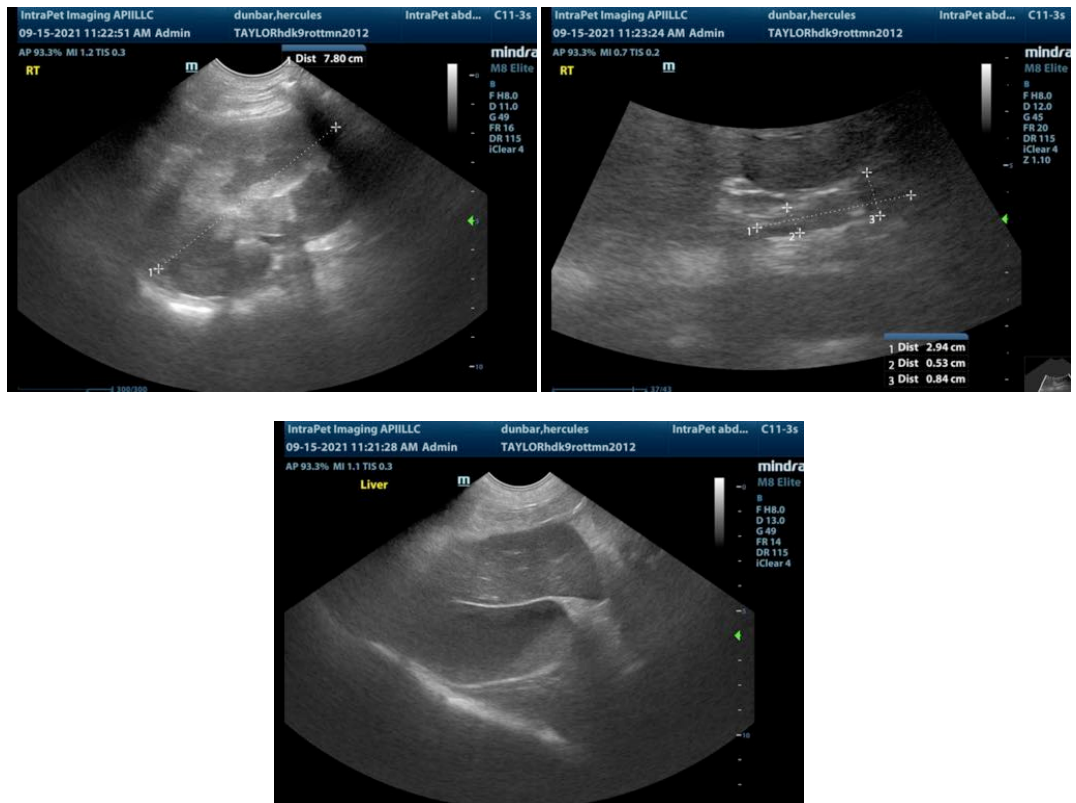PRIMARY FINDINGS:

- Large amount of echogenic debris in the urinary bladder. The echogenic debris in the bladder lumen could be consistent with cells, crystals, and/or mucus. Recommend urinalysis and culture.
- Decreased corticomedullary distinction in both kidneys with non-obstructive nephroliths. Mild loss of corticomedullary distinction in both kidneys could be consistent with chronic degenerative disease or interstitial nephrosis.
- Hypoechoic, heterogenous liver. The diffuse hepatic changes are non-specific and could be consistent with vacuolar hepatopathy, nodular hyperplasia, inflammatory/immune-mediated disease, fibrosis, extramedullary hematopoiesis, toxic hepatopathy (e.g., copper), infiltrative neoplasia (less likely) or other hepatopathy. Hypoechoic appearance favors and infiltrative or inflammatory/infectious condition.

INTERPRETATION OF THE FINDINGS & FURTHER RECOMMENDATIONS

The obvious source for the hypercalcemia and low albumin was not identified. Mild abnormalities were noted associated with the liver and kidneys. I recommend further work-up to try to differentiate causes. I recommend rectal exam to look for an anal gland mass. I also recommend urinalysis and culture and urine protein to creatinine ratio to see if the proteinuria is significant. A liver function test and a GI panel with a quantitative PLI, B12 and folate to look for underlying intestinal disease is warranted. The microcytic anemia combined with hypoalbuminemia could be consistent with GI blood loss so check for evidence of melena and a fecal floatation. Three view thoracic radiographs and hypercalcemia malignancy panel. Additionally consider FNA of the liver.





The information and recommendations provided are based on the images presented by the referring veterinarian. No evaluation can be communicated regarding pathology that was not visible in the image/video clips provided.

Thank you for this referral. If the clinical or image interpretation does not parallel your findings or if I can be of any further assistance please contact me.

Kathleen Sennello DVM,MS, Diplomate ACVIM (Small animal Internal Medicine)
kathleen.sennello@sonopath.com