



PATIENT

Ellie Kampf

SPECIES

Canine

BREED

Golden Retriever/Shepherd X

SEX

Intact Female

AGE

11 Years

WEIGHT

40.6 Pounds

INTERPRETED BY

Kathleen Sennello DVM,
MS, Diplomate ACVIM
(Small Animal Internal
Medicine)

IMAGING PERFORMED BY

Kelly Vazquez

HOSPITAL NAME

Wetwood Regional

REFERRING VET

Dr. Giammanco

INVOICE

25428

DATE

9/15/21

PRESENTING CLINICAL SIGNS

Patient presents for marked weight loss, significant muscle wasting, non-ambulatory for 2-3 days, inappetent x 3 days.

Abnormal PE/Chem/CBC/UA Results: Anemia: HCT 28.6%, BUN 48, 4DX (neg), Lepto PCR pending, T4 6.0.

ULTRASONOGRAPHIC EXAMINATION OF THE ABDOMEN

Urinary System

The urinary bladder is moderately distended with anechoic urine. The Bladder wall, trigone, ureteral papillae and visible urethra (to a depth of 2cm) appear normal with no evidence of wall thickening, mucosal irregularities, masses or cystic calculi.

The left kidney has a normal shape and size (5.98 cm). Overall echogenicity is normal with adequate corticomedullary distinction and a typical 1:3 cortex:medulla ratio. There is no evidence of perinephric inflammation or effusion. There is no evidence of pyelectasia, nephroliths, infarcts or hydroureter. Renal vasculature is normal.

The right kidney has a normal shape and size (5.28 cm). Overall echogenicity is normal with adequate corticomedullary distinction and a typical 1:3 cortex:medulla ratio. There is no evidence of perinephric inflammation or effusion. There is no evidence of pyelectasia, nephroliths, infarcts or hydroureter. Renal vasculature is normal.

Adrenal Glands

The region of left adrenal (Cranial to left renal artery) is unremarkable but the adrenal is not distinctly visualized. No evidence of a mass effect.

The region of the right adrenal (between right cranial kidney and vena cava) is unremarkable, but the adrenal is not distinctly visualized. No evidence of a mass effect.

Spleen

The spleen is subjectively normal in size, echotexture is homogenous, and the splenic capsule is smooth with no irregularities. The blood flow through the hilus and splenic parenchyma appears normal. No focal parenchymal abnormalities are visualized.

Liver

The liver is subjectively normal in size, and echogenicity with smooth peripheral margins. The parenchyma is homogenous echotexture. The visible portions of the vasculature and biliary tract appear normal. No focal nodules or cystic lesions are observed.

The gallbladder lumen is moderately distended. The wall of the gall bladder is not thickened and has a smooth mucosal surface. Luminal contents are primarily anechoic. The cystic and common bile ducts are normal/not visible.

Gastrointestinal

The stomach contains minimal luminal contents. It measures as slightly thickened in some areas with some variability due to the presence of rugal folds. One area appears to have decreased layering and measures up to 1.3 cm, but I suspect it is a somewhat obliqued view, so significance is difficult to determine. There is no evidence of reduced peristaltic activity.



PATIENT

Ellie Kampf

The visualized areas of duodenum, jejunum and ileum have a uniform diameter with minimal fluid distension. Wall appears subjectively, mildly increased. Bowel loops follow a typical curvilinear path with distinct wall layering. Duodenum wall measured 0.41 cm. Jejunum wall measured 0.24 cm. Visualized peristalsis appears appropriate. There were no focal lesions consistent with obstruction or a mass effect observed.

SPECIES

Canine

The ileocecal junction was visualized and exhibited normal intact wall layering and is subjectively of normal thickness. Sections of colon are visualized with formed fecal material and gas shadowing distally. There is no observed focal or generalized colon wall thickening or loss of layering.

BREED

Golden Retriever/Shepherd X

Pancreas

The pancreas is normal and isoechoic to surrounding mesentery. There is no evidence of nodules or cystic lesions. There is no evidence of regional mesenteric inflammation or fluid.

SEX

Intact Female

Free Abdomen

Evaluation of the peritoneal cavity did not reveal any evidence of effusion, or subjective lymphadenomegaly. The Medial iliac nodes appear normal and there was no evidence of a caudal aortic thrombus at the bifurcation. The omentum is of normal uniform echogenicity.

AGE

11 Years

ULTRASONOGRAPHIC FINDINGS

WEIGHT

40.6 Pounds

- Subjectively thickened small intestine – The mild small intestinal wall changes may be a normal variant in this patient or could be consistent with an inflammatory process (e.g., inflammatory bowel disease).
- Questionable gastric wall thickening – The stomach wall thickening could be consistent with inflammation, edema, infiltrative neoplasia, imaging artifact due to rugal folds, other.

INTERPRETED BY

Kathleen Sennello DVM, MS, Diplomate ACVIM (Small Animal Internal Medicine)

INTERPRETATION OF THE FINDINGS & FURTHER RECOMMENDATIONS

An obvious lesion responsible for the weight loss described is not clearly identified. The stomach wall appears thickened in some areas, but this can easily be misinterpreted in oblique views, or with evaluation of rugal folds. Additionally, the bowel subjectively appears normal but measures at relatively normal thickness. These findings could be consistent with IBD or be normal in an older pet. If thyroid levels are elevated (not sure of your normal range), then consider palpation of the cervical area for a thyroid carcinoma. Recommend 3-view thoracic radiographs. If no metabolic causes are found, then consider a GI panel to look for evidence of a B12 insufficiency or a folate abnormality, which could be an indicator of small intestinal disease. If primary GI disease is suspected, you could consider an upper GI endoscopy for further evaluation.

IMAGING PERFORMED BY

Kelly Vazquez

HOSPITAL NAME

Wetwood Regional

REFERRING VET

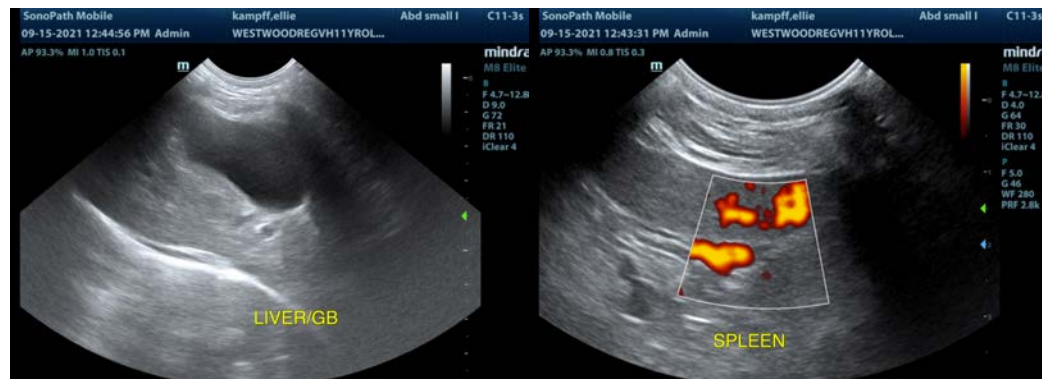Dr. Giammanco

INVOICE

25428

DATE

9/15/21





PATIENT

Ellie Kampf

SPECIES

Canine

BREED

Golden Retriever/Shepherd X

SEX

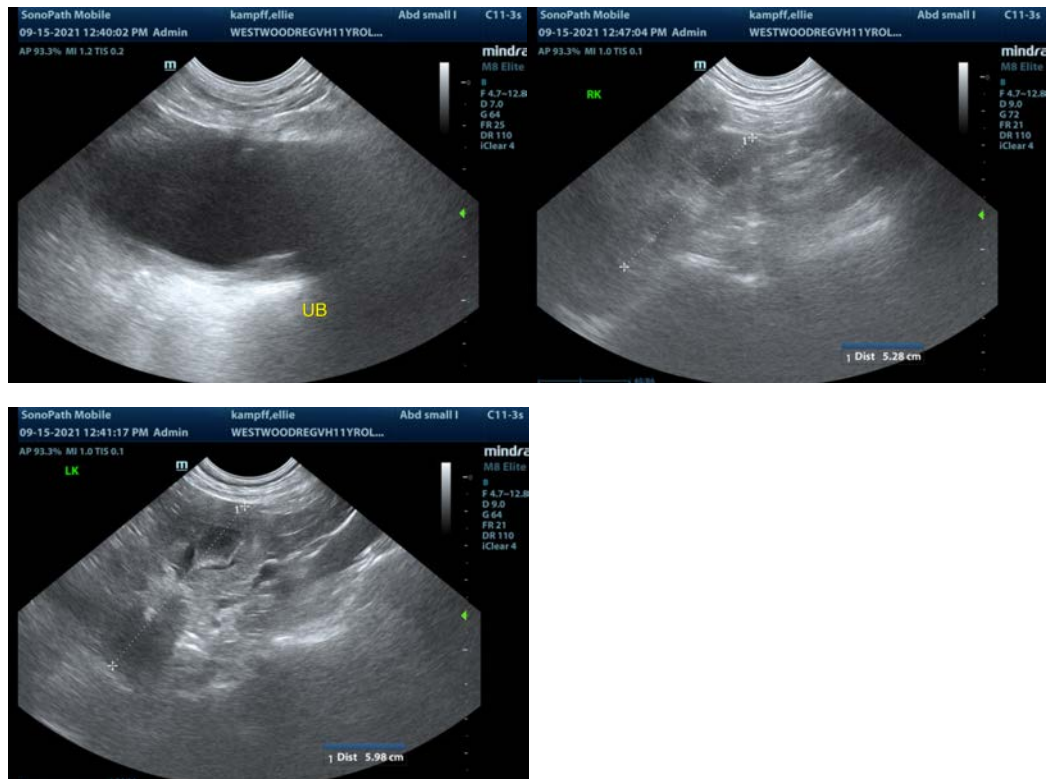
Intact Female

AGE

11 Years

WEIGHT

40.6 Pounds



INTERPRETED BY

Kathleen Sennello DVM,
MS, Diplomate ACVIM
(Small Animal Internal
Medicine)

**IMAGING
PERFORMED BY**

Kelly Vazquez

HOSPITAL NAME

Wetwood Regional

REFERRING VET

Dr. Giammanco

INVOICE

25428

DATE

9/15/21

The information and recommendations provided are based on the images presented by the referring veterinarian. No evaluation can be communicated regarding pathology that was not visible in the image/video clips provided.

Thank you for this referral. If the clinical or image interpretation does not parallel your findings or if I can be of any further assistance please contact me.

Kathleen Sennello DVM,MS, Diplomate ACVIM (Small animal Internal Medicine)
kathleen.sennello@sonopath.com