

DATE

9/15/21

PRESENTING CLINICAL SIGNS

History: 4 yo MN DSH. Weight was 12.8 lbs. in June 2021 at AWW. Weight 9/3 was 10.5 lb. Not eating well. Failed empiric injectable Cerenia and Mirataz trial. No vomiting/diarrhea.
Current Medications: Mirataz trans dermally x 10 days. No significant improvement.
Lab Results: 9/3/2021 fPL normal at 0.7, Monocytosis 2184, Elevated Hct 52.9% (subclinically dehydrated).
Date of Previous IntraPet Ultrasound: No previous IntraPet scans.
Sedation: Not needed.
Stat Report: Not requested.

PATIENT

David Borden

SPECIES

Feline

BREED

Domestic Shorthair

SEX

Neutered male

AGE

7/5/17

WEIGHT

10.5 lbs

INTERPRETED BY

Kathleen Sennello
DVM, MS, Diplomate
ACVIM (Small Animal
Internal Medicine)

HOSPITAL NAME

Paradise AH

REFERRING VET

Dr. Riehl

INVOICE

91851

ULTRASONOGRAPHIC EXAMINATION OF THE ABDOMEN

Urinary System

The urinary bladder is moderately distended with anechoic urine. The Bladder wall, trigone, ureteral papillae and visible urethra (to a depth of 2cm) appear normal with no evidence of wall thickening, mucosal irregularities, masses or cystic calculi.

The left kidney has a normal shape and size (3.76 cm). Overall echogenicity is normal with adequate corticomedullary distinction and a typical 1:3 cortex:medulla ratio. There is no evidence of perinephric inflammation or effusion. There is no evidence of pyelectasia, nephroliths, infarcts or hydroureter. Renal vasculature is normal.

The right kidney has a normal shape and size (4.08 cm). Overall echogenicity is normal with adequate corticomedullary distinction and a typical 1:3 cortex:medulla ratio. There is no evidence of perinephric inflammation or effusion. There is no evidence of pyelectasia, nephroliths, infarcts or hydroureter. Renal vasculature is normal.

Adrenal Glands

The left adrenal gland is normal in size measuring 0.47 cm at the caudal pole. It is observed in its normal position cranial to the left renal artery. It is normal in appearance (uniformly hypoechoic) and shape with no evidence of a mass effect.

The right adrenal gland is normal in size measuring 0.47 cm at the caudal pole. It is observed in its normal position between the cranial aspect of the right kidney and the caudal vena cava. It is normal in appearance (uniformly hypoechoic) and shape with no evidence of a mass effect.

Spleen

The spleen is subjectively normal in size, echotexture is homogenous, and the splenic capsule is smooth with no irregularities. The blood flow through the hilus and splenic parenchyma appears normal. No focal parenchymal abnormalities are visualized.

Liver

The liver is subjectively normal in size, and echogenicity with smooth peripheral margins. The parenchyma is homogenous echotexture. The visible portions of the vasculature and biliary tract appear normal. No focal nodules or cystic lesions are observed. The gallbladder lumen is moderately distended. The wall of the gall bladder is not thickened and has a smooth mucosal surface. Luminal contents are primarily anechoic. The cystic and common bile ducts are normal/not visible.

Gastrointestinal

The stomach is moderately dilated with fluid and irregular shadowing material most consistent with normal ingesta and gas. It measures at a normal thickness of <0.36cm with some variability due to the presence of rugal folds. The distinction of the gastric wall layering is adequate and there is no impression of reduced peristaltic activity. No masses or focal lesions were observed.

The visualized areas of duodenum, jejunum and ileum have a uniform diameter with minimal fluid distension. Wall thickness is normal to slightly increased. Bowel loops follow a typical curvilinear path with distinct wall layering, but some areas display a prominent muscularis layer which does not display the typical 1:3 muscularis:mucosa layer ratio. The jejunum measured 0.23 cm. Visualized peristalsis appears appropriate. There were no focal lesions consistent with obstruction or a mass effect observed.

The ileocecal junction was visualized and exhibited normal intact wall layering and is subjectively of normal thickness. Sections of colon are visualized with formed fecal material and gas shadowing distally. There is no observed focal or generalized colon wall thickening or loss of layering.

Pancreas

The region of the pancreas is normal and isoechoic to surrounding mesentery. There is no evidence of nodules or cystic lesions. There is no evidence of regional mesenteric inflammation or fluid.

Free Abdomen

There was a small amount of free abdominal fluid. There is a severe mesenteric lymphadenopathy/abdominal mass. There is a large, mid abdominal mass that measured 6.61 x 6.6 cm. The mass is solid and irregular. I cannot visualize any association with other organs. I suspect a large lymph node or pancreatic origin. The omentum is of increased echogenicity around the abdominal mass.

Other

A brief view of the heart was submitted. Trace pericardial and non-cardiogenic pleural effusion was present suggestive for likely metastatic thoracic disease.

ULTRASONOGRAPHIC FINDINGS

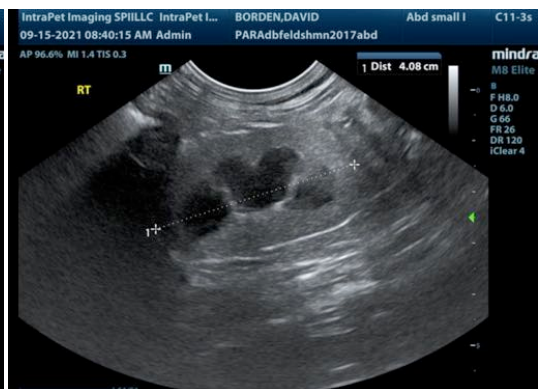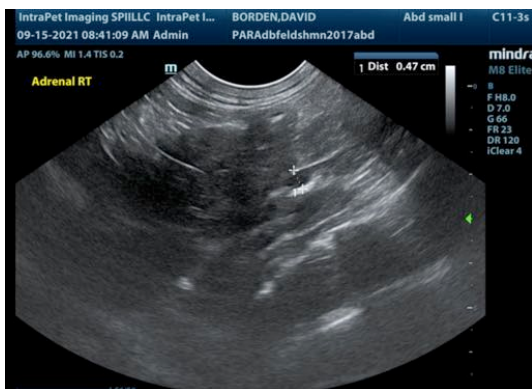
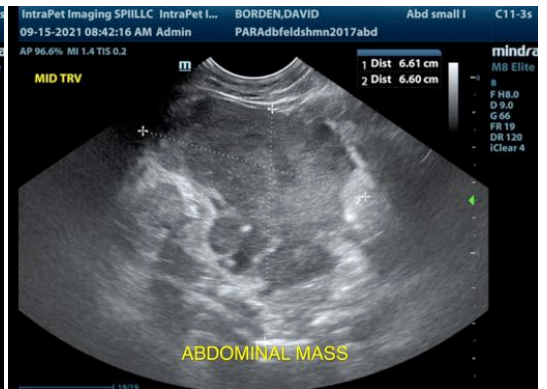
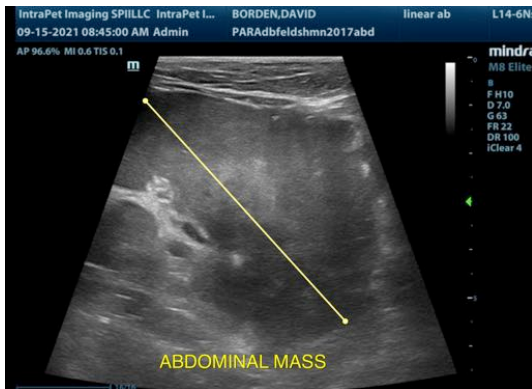
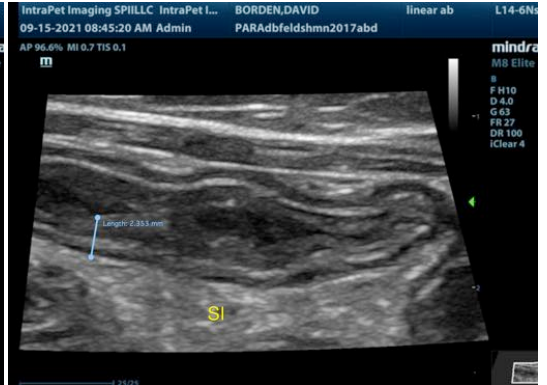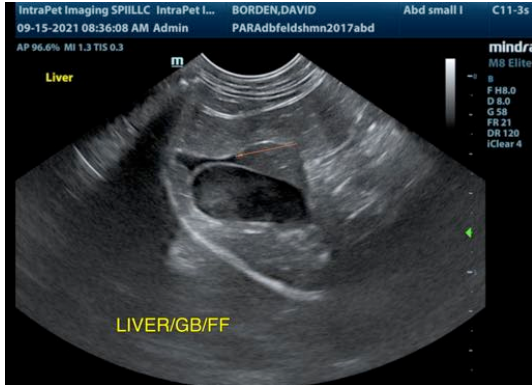
PRIMARY FINDINGS:

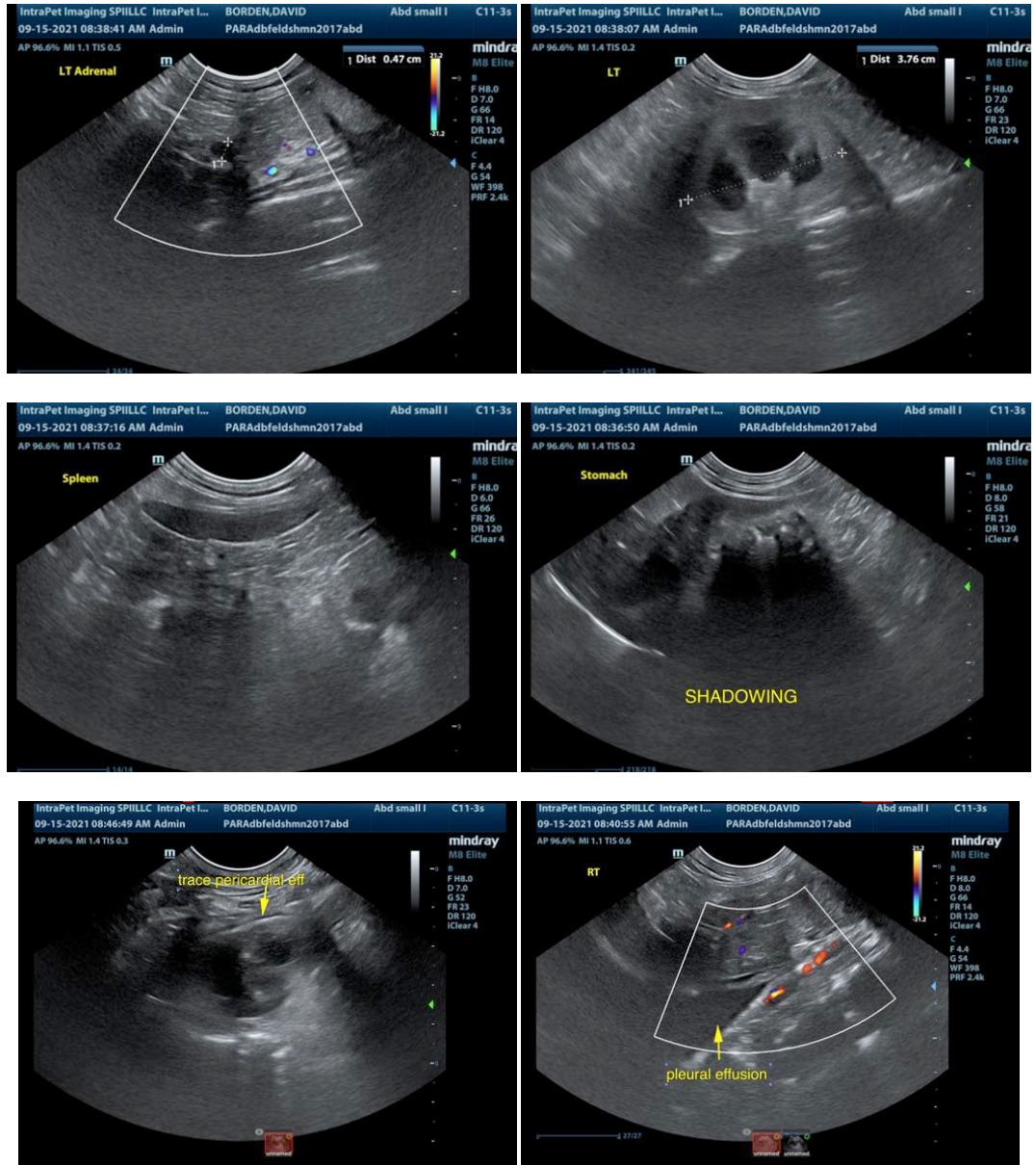
- Large mid abdominal mass. I suspect a very large lymph node or possible pancreatic mass?
- Prominent muscularis layer to the small intestine. The small intestinal wall changes are most consistent with an inflammatory process (i.e., inflammatory bowel disease) with a low possibility of emerging lymphoma.
- Small volume pleural and peritoneal effusion-Recommend thoracic radiographs

INTERPRETATION OF THE FINDINGS & FURTHER RECOMMENDATIONS

There is a large, midabdominal mass visualized. The origin of this mass is unclear. It could be a lymph node or have a small attachment that is not readily apparent. In some images there appears to be a possible pancreatic duct going through it, but this is not apparent with color flow, so it is difficult to say for sure. I recommend a FNA of the lesion.

If lymphoma is ruled out based on FNA, then consider a referral to a veterinary surgeon for possible preoperative CT or exploratory surgery for possible removal/biopsy. If cytology is diagnostic, consider referral to a veterinary oncologist for treatment recommendations. I recommend three view thoracic radiographs.





The information and recommendations provided are based on the images presented by the referring veterinarian. No evaluation can be communicated regarding pathology that was not visible in the image/video clips provided.

Thank you for this referral. If the clinical or image interpretation does not parallel your findings or if I can be of any further assistance please contact me.

Kathleen Sennello DVM,MS, Diplomate ACVIM (Small animal Internal Medicine)
 kathleen.sennello@sonopath.com