



PATIENT

Bandit Emerson

SPECIES

Canine

BREED

German Shepherd

SEX

Neutered Male

AGE

10 Years

WEIGHT

56 kg

INTERPRETED BY

Kathleen Sennello DVM,
MS, Diplomate ACVIM
(Small Animal Internal
Medicine)

IMAGING PERFORMED BY

Jolee Stegemoller

HOSPITAL NAME

North Idaho AH

REFERRING VET

Dr. Dawn Mehra

INVOICE

25438

DATE

9/15/21

PRESENTING CLINICAL SIGNS

Presented for ultrasound following serial elevations in ALP and ALT after seeing some weight loss over time.

Abnormal PE/Chem/CBC/UA Results: 9/15/21 - ALT 219, ALP 281 8/22/21 - ALT 172, ALP 213 8/31/20 - ALT 298, ALP 434

ULTRASONOGRAPHIC EXAMINATION OF THE ABDOMEN

Urinary System

The urinary bladder is moderately distended with anechoic urine. The Bladder wall, trigone, ureteral papillae and visible urethra (to a depth of 2cm) appear normal with no evidence of wall thickening, mucosal irregularities, masses or cystic calculi.

The prostate is normal in size and shape for this neutered male dog. The parenchyma is homogenous and the external margins are smooth. The prostatic urethra appears normal with no evidence of irregularity, invasion, mass effect or calculi.

The left kidney has a normal shape and size (9.68 cm). Overall echogenicity is normal with adequate corticomedullary distinction and a typical 1:3 cortex:medulla ratio. There is no evidence of perinephric inflammation or effusion. Rare non-obstructive nephroliths are present. There is no evidence of pyelectasia, infarcts or hydroureter. Renal vasculature is normal.

The right kidney has a normal shape and size (9.57 cm). Overall echogenicity is normal with adequate corticomedullary distinction and a typical 1:3 cortex:medulla ratio. There is no evidence of perinephric inflammation or effusion. Pinpoint non-obstructive nephroliths are present. There is no evidence of pyelectasia, infarcts or hydroureter. Renal vasculature is normal.

Adrenal Glands

The left adrenal gland is normal in size measuring 0.94 cm at the caudal pole. It is observed in its normal position cranial to the left renal artery. It is normal in appearance (uniformly hypoechoic) and shape with no evidence of a mass effect.

The right adrenal gland is normal in size measuring 0.73 cm at the caudal pole. It is observed in its normal position between the cranial aspect of the right kidney and the caudal vena cava. It is normal in appearance (uniformly hypoechoic) and shape with no evidence of a mass effect.

Spleen

The spleen is prominent in size and the echotexture is homogenous. The splenic capsule is smooth with no visible irregularities. Rare discrete focal hyperechoic, perivascular parenchymal abnormalities are present. The appearance of these lesions is most consistent with benign splenic myelolipomas. The blood flow through the hilus and splenic parenchyma appears normal.

Liver

The liver is subjectively normal in size, and echogenicity with smooth peripheral margins. The parenchyma is heterogenous in echotexture with subtle, indistinct focal mottling. The visible portions of the vasculature and biliary tract appear normal. No focal nodules or cystic lesions are observed.

The gallbladder lumen is moderately distended. The wall of the gall bladder is not thickened and has a smooth mucosal surface. Luminal contents are primarily anechoic. The cystic and common bile ducts are normal/not visible.



PATIENT

Gastrointestinal

Bandit Emerson

The stomach contains minimal luminal contents. It measures at a normal thickness of <0.7cm with some variability due to the presence of rugal folds. The distinction of the gastric wall layers is adequate and there is no impression of reduced peristaltic activity. No masses or focal lesions were observed.

SPECIES

Canine

The visualized areas of duodenum, jejunum and ileum have a relatively uniform diameter with minimal fluid distension. Wall thickness is normal. Bowel loops follow a curvilinear path with distinct wall layering maintaining the typical 1:3 muscularis:mucosa layer ratio. The duodenum measured as normal (between 0.3-0.5cm in wall thickness) and the jejunum measured as normal (between 0.2-0.47cm.)

BREED

German Shepherd

Visualized peristalsis appears appropriate. There were no focal lesions consistent with obstruction or a mass effect observed.

SEX

Neutered Male

The ileocecal junction was visualized and exhibited normal intact wall layering and is subjectively of normal thickness. Sections of colon are visualized with formed fecal material and gas shadowing distally. There is no observed focal or generalized colon wall thickening or loss of layering.

Pancreas

AGE

10 Years

The pancreas is normal and isoechoic to surrounding mesentery. There is no evidence of nodules or cystic lesions. There is no evidence of regional mesenteric inflammation or fluid.

Free Abdomen

WEIGHT

56 kg

Evaluation of the peritoneal cavity did not reveal any evidence of effusion, or subjective lymphadenomegaly. The Medial iliac nodes appear normal and there was no evidence of a caudal aortic thrombus at the bifurcation. The omentum is of normal uniform echogenicity.

PRIMARY FINDINGS

- Heterogeneous liver – The diffuse hepatic changes are non-specific and could be consistent with vacuolar hepatopathy, nodular hyperplasia, inflammatory/immune-mediated disease, fibrosis, extramedullary hematopoiesis, toxic hepatopathy (e.g., copper), infiltrative neoplasia (less likely) or other hepatopathy.
- Subjectively large spleen with hyperechoic foci – Most consistent with benign myelolipomas.

INTERPRETED BY

Kathleen Sennello DVM,
MS, Diplomate ACVIM
(Small Animal Internal
Medicine)

IMAGING PERFORMED BY

Jolee Stegemoller

HOSPITAL NAME

North Idaho AH

SECONDARY FINDINGS

- Occasional pinpoint non-obstructive nephroliths in both kidneys – The hyperechoic mineralized foci observed at the corticomedullary junction of the left/right kidney are consistent with small, non-obstructive nephroliths.

REFERRING VET

Dr. Dawn Mehra

INTERPRETATION OF THE FINDINGS & FURTHER RECOMMENDATIONS

The ultrasonographic findings were relatively mild and could be normal for this individual, but given the chronic liver enzyme elevations, I would recommend:

INVOICE

25438

DATE

9/15/21

- Consider close evaluation of history for possible toxic changes examine medications, diet, dietary indiscretion etc...
- Consider PCR on urine/serum for leptospirosis (if not on antibiotics)/serology if recent antibiotic history
- If not already done, consider pre and post prandial bile acids to evaluate liver function
- Consider Fine needle aspirate if round cell neoplasia is on your differential list (25 g needle, normal coags)



PATIENT

Bandit Emerson

- If no response to supportive care (denamarin, fluids, antibiotics, +/- ursodiol etc...) Consider liver biopsy with samples obtained for histopathology, culture, and copper levels.

SPECIES

Canine

The spleen very well may be normal for this dog. I feel German Shepherds particularly have prominent spleens. However, if weight loss continued, you could consider a fine needle aspirate of the spleen and a GI panel to evaluate for underlying intestinal disease.

BREED

German Shepherd

SEX

Neutered Male

AGE

10 Years

WEIGHT

56 kg

INTERPRETED BY

Kathleen Sennello DVM, MS, Diplomate ACVIM (Small Animal Internal Medicine)

IMAGING PERFORMED BY

Jolee Stegemoller

HOSPITAL NAME

North Idaho AH

REFERRING VET

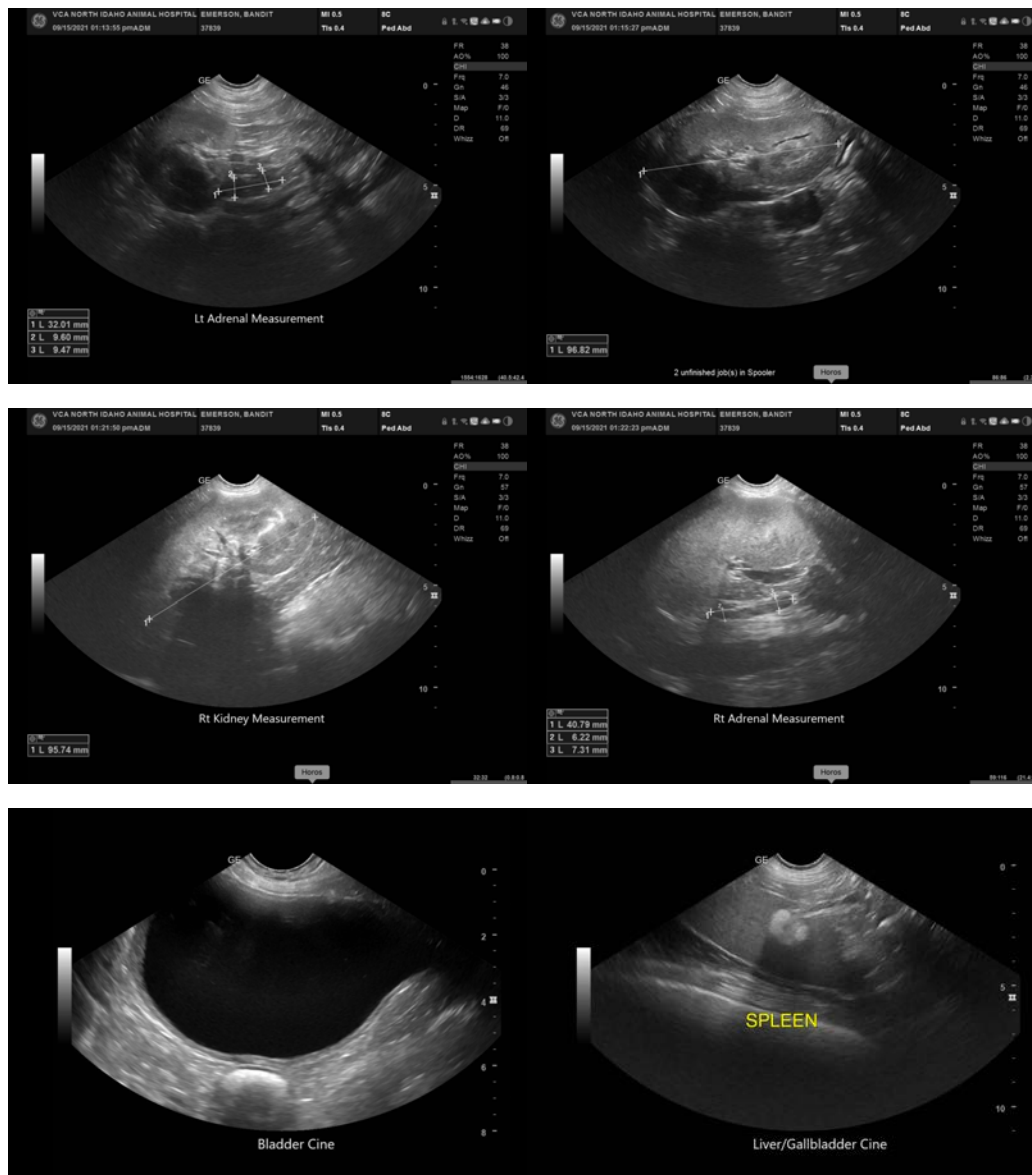
Dr. Dawn Mehra

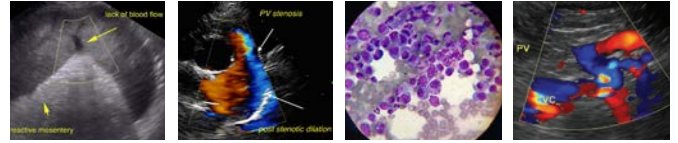
INVOICE

25438

DATE

9/15/21





PATIENT

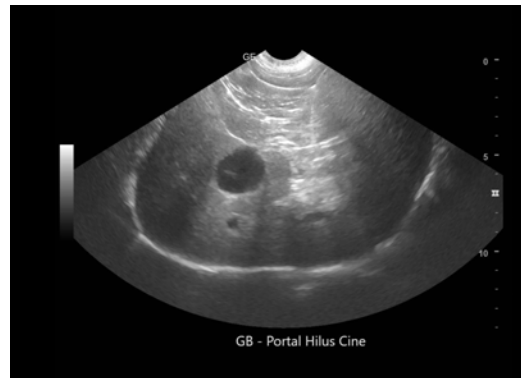
Bandit Emerson

SPECIES

Canine

BREED

German Shepherd



SEX

Neutered Male

AGE

10 Years

WEIGHT

56 kg

The information and recommendations provided are based on the images presented by the referring veterinarian. No evaluation can be communicated regarding pathology that was not visible in the image/video clips provided.

Thank you for this referral. If the clinical or image interpretation does not parallel your findings or if I can be of any further assistance please contact me.

Kathleen Sennello DVM,MS, Diplomate ACVIM (Small animal Internal Medicine)
kathleen.sennello@sonopath.com

INTERPRETED BY

Kathleen Sennello DVM,
MS, Diplomate ACVIM
(Small Animal Internal
Medicine)

**IMAGING
PERFORMED BY**

Jolee Stegemoller

HOSPITAL NAME

North Idaho AH

REFERRING VET

Dr. Dawn Mehra

INVOICE

25438

DATE

9/15/21