



**PATIENT**

Twitch Manning

**PRESENTING CLINICAL SIGNS**

Chronic vomiting. History of CKD PE: Obese Unkept coat with dander Vomiting occasionally sometimes with grass Anorexia this morning

**SPECIES**

Feline

Abnormal PE/Chem/CBC/UA Results: AST 249 IU/L ALT 1226 IU/L Total Bili 2.0mg/dL Creatinine 2.5 mg/dL Amylase 1891 IU/L PSL 278 U/L

**BREED**

DSH

**ULTRASONOGRAPHIC EXAMINATION OF THE ABDOMEN**

**Urinary System**

The urinary bladder is moderately distended with anechoic urine. The Bladder wall, trigone, ureteral papillae and visible urethra (to a depth of 2cm) appear normal with no evidence of wall thickening, mucosal irregularities, masses or cystic calculi.

**SEX**

Spayed Female

The left kidney has a normal shape and size (3.25 cm). Overall echogenicity is slightly hyperechoic with poor corticomedullary distinction and a typical 1:3 cortex:medulla ratio. There is no evidence of focal perinephric inflammation or effusion. There is no evidence of pyelectasia, nephroliths, infarcts or hydroureter. Renal vasculature is normal.

**AGE**

14 Years

The right kidney has a normal shape and size (3.16 cm). Overall echogenicity is slightly hyperechoic with poor corticomedullary distinction and a typical 1:3 cortex:medulla ratio. There is no evidence of focal perinephric inflammation or effusion. There is no evidence of pyelectasia, nephroliths, infarcts or hydroureter. Renal vasculature is normal.

**WEIGHT**

15 Pounds

**Adrenal Glands**

The left adrenal gland is normal in size measuring 0.34 cm at the caudal pole. It is observed in its normal position cranial to the left renal artery. It is normal in appearance (uniformly hypoechoic) and shape with no evidence of a mass effect.

The region of the right adrenal (between right cranial kidney and vena cava) is unremarkable, but the adrenal is not distinctly visualized. No evidence of a mass effect.

**INTERPRETED BY**

Kathleen Sennello DVM,  
MS, Diplomate ACVIM  
(Small Animal Internal  
Medicine)

**Spleen**

The spleen is subjectively normal in size (0.6 cm in width at the level of the hilus), echotexture is homogenous, and the splenic capsule is smooth with no irregularities. The blood flow through the hilus and splenic parenchyma appears normal. No focal parenchymal abnormalities are visualized.

**IMAGING PERFORMED BY**

Dr. Carter

**Liver**

The liver is subjectively normal in size, and hypoechoic with smooth peripheral margins. The parenchyma is heterogenous in echotexture with subtle, indistinct focal mottling. The visible portions of the vasculature and biliary tract appear normal. No focal nodules or cystic lesions are observed.

**HOSPITAL NAME**

Willamette VH

**REFERRING VET**

Dr. Porter

The gallbladder lumen is minimally distended. There are numerous shadowing hyperechoic foci within the gallbladder lumen, most consistent with small stones. The bile duct extending from the gallbladder appears thickened, irregular, and dilated. It follows a tortuous path with intermittent intraluminal stones. The largest stone measures 0.61 cm. The width of the bile duct in that region measures 0.51 cm. There is surrounding inflammation. No focal point of obstruction is visualized.

**INVOICE**

41338

**DATE**

9/14/22



**PATIENT**

Twitch Manning

**SPECIES**

Feline

**BREED**

DSH

**SEX**

Spayed Female

**AGE**

14 Years

**WEIGHT**

15 Pounds

**INTERPRETED BY**

Kathleen Sennello DVM,  
MS, Diplomate ACVIM  
(Small Animal Internal  
Medicine)

**IMAGING  
PERFORMED BY**

Dr. Carter

**HOSPITAL NAME**

Willamette VH

**REFERRING VET**

Dr. Porter

**INVOICE**

41338

**DATE**

9/14/22

**Gastrointestinal**

The stomach contains minimal luminal contents. It measures at a normal thickness of <0.36cm with some variability due to the presence of rugal folds. The distinction of the gastric wall layers is adequate and there is no impression of reduced peristaltic activity. No masses or focal lesions were observed.

The visualized areas of duodenum, jejunum and ileum have a relatively uniform diameter with minimal fluid distension. Wall thickness is normal. Bowel loops follow a curvilinear path with distinct wall layering maintaining the typical 1:3 muscularis:mucosa layer ratio. The duodenum measured as normal (between 0.13-0.38cm in wall thickness) and the jejunum measured as normal (between 0.15-0.36cm.) Visualized peristalsis appears appropriate. There were no focal lesions consistent with obstruction or a mass effect observed.

The ileocecal junction was visualized and exhibited normal intact wall layering and is subjectively of normal thickness. Sections of colon are visualized with formed fecal material and gas shadowing distally. There is no observed focal or generalized colon wall thickening or loss of layering.

**Pancreas**

The pancreas is prominent and hypoechoic as compared to the surrounding isoechoic mesentery. There is no evidence of nodules or cystic lesions. There is no evidence of regional mesenteric inflammation or fluid.

**Free Abdomen**

Evaluation of the peritoneal cavity did not reveal any evidence of effusion, or subjective lymphadenomegaly. The Medial iliac nodes appear normal and there was no evidence of a caudal aortic thrombus at the bifurcation. The omentum is hyperechoic in the right cranial quadrant, most consistent with inflammation surrounding the bile duct.

**ULTRASONOGRAPHIC FINDINGS**

- Gallbladder stones with numerous stones extending into the bile duct with severe bile duct dilation and thickening – findings are consistent with gallbladder stones and intermittent partial obstructions of the bile duct.
- Decreased corticomedullary distinction in both kidneys – Mild loss of corticomedullary distinction in both kidneys could be consistent with chronic degenerative disease or interstitial nephrosis.
- Hypoechoic, prominent pancreas – The pancreatic changes are most consistent with mild pancreatitis or a recent episode of pancreatic inflammation.
- Hypoechoic, heterogeneous liver – Hepatic changes are non-specific and could be consistent with inflammation/infection (cholangiohepatitis), infiltrative neoplasia, lipidosis or other hepatopathy.

**INTERPRETATION OF THE FINDINGS & FURTHER RECOMMENDATIONS**

There are stones visible in the gallbladder that appear to be extending into the bile duct, causing inflammation, dilation, and partial obstruction. No focal point of obstruction is visualized, but there is a large amount of surrounding inflammation. Additionally, the pancreas is somewhat prominent. Findings are most consistent with numerous partial intermittent bile duct obstructions with secondary inflammations and cholecystitis +/- pancreatitis. Recommend medical management with IV fluids, Ursodiol, antibiotics, and probiotics. You could consider a fine needle aspirate of the liver, provided



**PATIENT**

Twitch Manning

coagulation parameters permit, and continued monitoring of the gallbladder and bile duct for progressive dilation. Pain medication would also be helpful.

**SPECIES**

Feline

Based on the history of chronic vomiting, it is possible that this also incorporates pancreatic and small intestinal disease with some element of Triaditis, although this is primary cholecystitis with gallbladder stones. You could consider a novel protein/hydrolyzed protein prescription diet and other therapies for underlying GI disease.

**BREED**

DSH

The changes in the kidneys are consistent with chronic progressive renal disease. Recommend a blood pressure, urinalysis, and culture.

**SEX**

Spayed Female

**AGE**

14 Years

**WEIGHT**

15 Pounds

**INTERPRETED BY**

Kathleen Sennello DVM, MS, Diplomate ACVIM (Small Animal Internal Medicine)

**IMAGING PERFORMED BY**

Dr. Carter

**HOSPITAL NAME**

Willamette VH

**REFERRING VET**

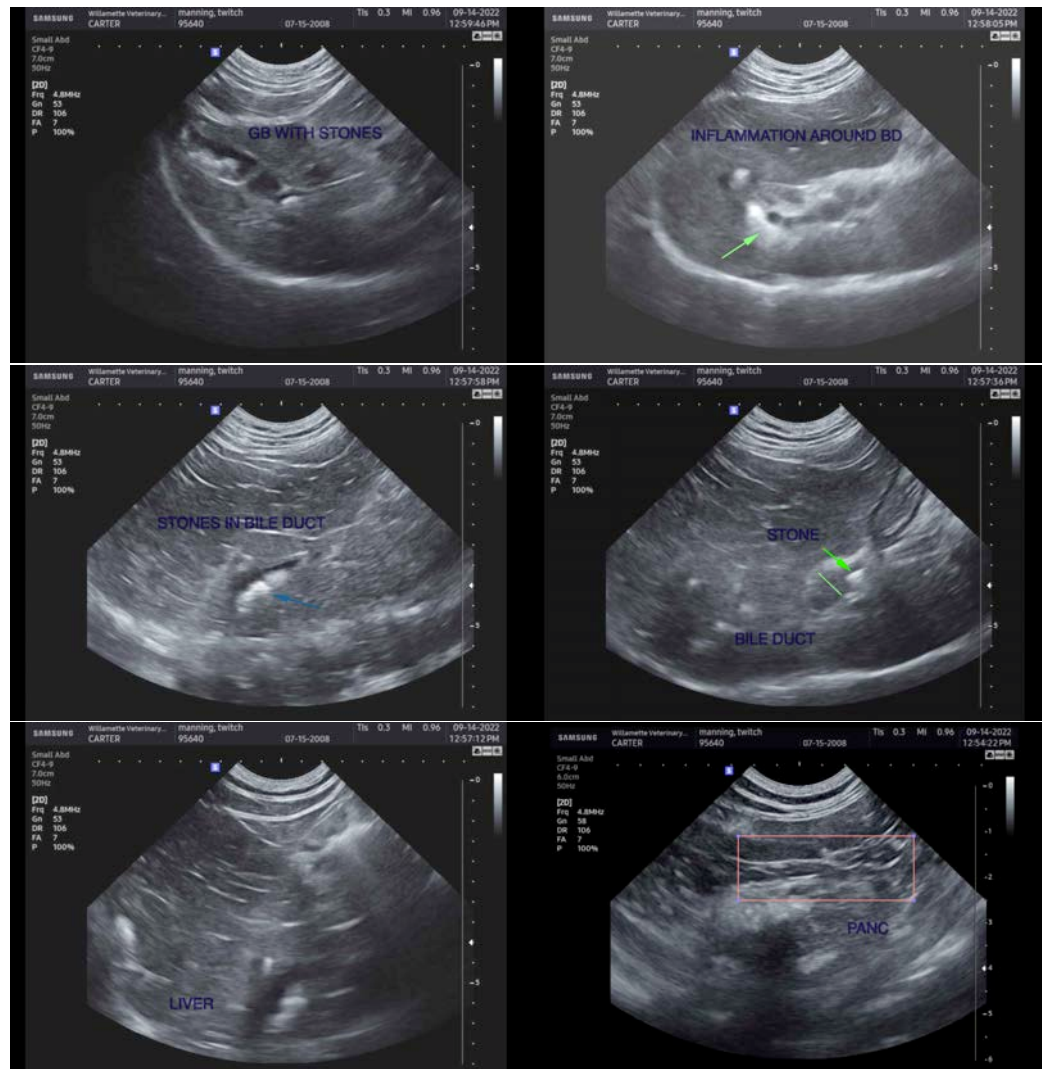
Dr. Porter

**INVOICE**

41338

**DATE**

9/14/22





**PATIENT**

Twitch Manning

**SPECIES**

Feline

**BREED**

DSH

**SEX**

Spayed Female

**AGE**

14 Years

**WEIGHT**

15 Pounds

**INTERPRETED BY**

Kathleen Sennello DVM,  
MS, Diplomate ACVIM  
(Small Animal Internal  
Medicine)

**IMAGING  
PERFORMED BY**

Dr. Carter

**HOSPITAL NAME**

Willamette VH

**REFERRING VET**

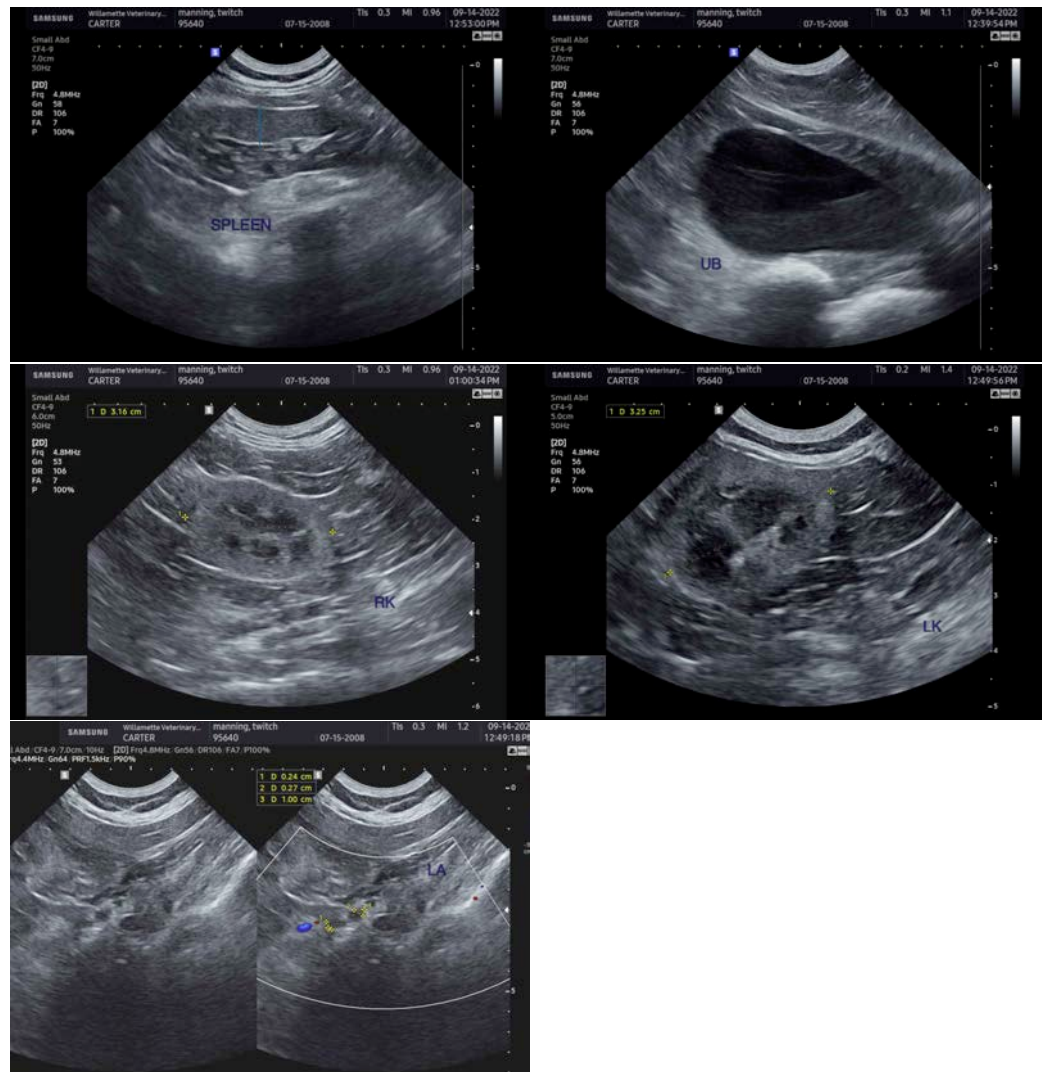
Dr. Porter

**INVOICE**

41338

**DATE**

9/14/22



The information and recommendations provided are based on the images presented by the referring veterinarian/sonographer. No evaluation can be communicated regarding pathology that was not visible in the image/video clips provided.

Thank you for this referral. If the clinical or image interpretation does not parallel your findings or if I can be of any further assistance please contact me.

Kathleen Sennello DVM,MS, Diplomate ACVIM (Small animal Internal Medicine)

kathleen.sennello@sonopath.com