



PATIENT

Simon Schmidt

PRESENTING CLINICAL SIGNS

ALT had been trending upwards, but has been acting clinically normal e/d+ and no v/d

SPECIES

Canine

ULTRASONOGRAPHIC EXAMINATION OF THE ABDOMEN

Urinary System

The urinary bladder is moderately distended with anechoic urine. The Bladder wall, trigone, ureteral papillae and visible urethra (to a depth of 2cm) appear normal with no evidence of wall thickening, mucosal irregularities, masses or cystic calculi.

BREED

Cockapoo

The visualized areas of prostate and surrounding tissue appear normal. Unfortunately, the prostate is not fully visualized likely due to its intrapelvic location. Correlate with rectal exam findings.

SEX

Neutered Male

The left kidney has a normal shape and size (5.2 cm). Overall echogenicity is normal with adequate corticomedullary distinction and a typical 1:3 cortex:medulla ratio. There is no evidence of focal perinephric inflammation or effusion. There is no evidence of pyelectasia, nephroliths, infarcts or hydroureter. Renal vasculature is normal.

AGE

12 Years

The right kidney has a normal shape and size (4.5 cm). Overall echogenicity is normal with adequate corticomedullary distinction and a typical 1:3 cortex:medulla ratio. There is no evidence of focal perinephric inflammation or effusion. There is no evidence of pyelectasia, nephroliths, infarcts or hydroureter. Renal vasculature is normal.

WEIGHT

24.8 Pounds

Adrenal Glands

The left adrenal gland is normal in size measuring 0.55 cm at the caudal pole. It is observed in its normal position cranial to the left renal artery. It is normal in appearance (uniformly hypoechoic) and shape with no evidence of a mass effect.

INTERPRETED BY

Kathleen Sennello DVM,
MS, Diplomate ACVIM
(Small Animal Internal
Medicine)

The right adrenal gland is normal in size measuring 0.56 cm at the caudal pole. It is observed in its normal position between the cranial aspect of the right kidney and the caudal vena cava. It is normal in appearance (uniformly hypoechoic) and shape with no evidence of a mass effect.

IMAGING PERFORMED BY

Dr. Gallick

Spleen

The spleen is subjectively normal in size, echotexture is homogenous, and the splenic capsule is smooth with no irregularities. The blood flow through the hilus and splenic parenchyma appears normal. There is a distinct hyperechoic nodule visualized within the parenchyma measuring 0.96 cm in diameter.

HOSPITAL NAME

Magnolia Springs VC

Liver

The liver is subjectively normal in size, and echogenicity with smooth peripheral margins. The parenchyma is heterogenous in echotexture with subtle, indistinct focal mottling. The visible portions of the vasculature and biliary tract appear normal. There are numerous ill-defined hypoechoic nodules distributed throughout the parenchyma, varying in size from 0.5-1.0 cm. Additionally, there is a slightly larger, irregular, hyperechoic nodule measuring 1.78 cm x 1.66 cm.

REFERRING VET

Dr. Gallick

INVOICE

41347

The gallbladder lumen is moderately distended. The wall of the gall bladder is not thickened and has a smooth mucosal surface. Luminal contents are mild and primarily anechoic. The cystic and common bile ducts are normal/not visible.

DATE

9/14/22



PATIENT

Simon Schmidt

Gastrointestinal

The stomach contains minimal luminal contents. It measures at a normal thickness of <0.7cm with some variability due to the presence of rugal folds. The distinction of the gastric wall layers is adequate and there is no impression of reduced peristaltic activity. No masses or focal lesions were observed.

SPECIES

Canine

The visualized areas of duodenum, jejunum and ileum have a uniform diameter with minimal fluid distension. Wall appears subjectively, mildly increased. Bowel loops follow a typical curvilinear path with distinct wall layering. Duodenum wall measured 0.54 cm. Jejunum wall measured 0.39 cm.

BREED

Cockapoo

Visualized peristalsis appears appropriate. There were no focal lesions consistent with obstruction or a mass effect observed.

SEX

Neutered Male

The ileocecal junction was visualized and exhibited normal intact wall layering and is subjectively of normal thickness. Sections of colon are visualized with formed fecal material and gas shadowing distally. There is no observed focal or generalized colon wall thickening or loss of layering.

AGE

12 Years

Pancreas

The pancreas is normal and isoechoic to surrounding mesentery. There is no evidence of nodules or cystic lesions. There is no evidence of regional mesenteric inflammation or fluid.

WEIGHT

24.8 Pounds

Free Abdomen

Evaluation of the peritoneal cavity did not reveal any evidence of effusion, or subjective lymphadenomegaly. The Medial iliac nodes appear normal and there was no evidence of a caudal aortic thrombus at the bifurcation. The omentum is of normal uniform echogenicity.

ULTRASONOGRAPHIC FINDINGS

INTERPRETED BY

Kathleen Sennello DVM,
MS, Diplomate ACVIM
(Small Animal Internal
Medicine)

- Hyperechoic nodule in the spleen – The appearance of this nodule trends towards a more benign etiology, but a fine needle aspirate would be necessary to rule out a neoplastic lesion.
- Heterogeneous liver with ill-defined hypoechoic nodules – The diffuse hepatic changes are non-specific and could be consistent with vacuolar hepatopathy, nodular hyperplasia, inflammatory/immune-mediated disease, fibrosis, extramedullary hematopoiesis, toxic hepatopathy (e.g., copper), infiltrative neoplasia (less likely) or other hepatopathy. The nodules observed trend toward a more benign process but underlying neoplasia cannot be ruled out.
- Subjectively thickened small intestine – The mild small intestinal wall changes may be a normal variant in this patient or could be consistent with an inflammatory process (e.g., inflammatory bowel disease).

IMAGING PERFORMED BY

Dr. Gallick

HOSPITAL NAME

Magnolia Springs VC

INTERPRETATION OF THE FINDINGS & FURTHER RECOMMENDATIONS

The liver appears to have diffuse ill-defined, hypoechoic nodules as well as an occasional larger hypoechoic nodule. These could represent a benign or neoplastic disease process. Consider the following recommendations:

REFERRING VET

Dr. Gallick

- Induction phenomena are the most common cause for an elevation in ALP. These are systemic illnesses that 'turn on' the liver enzyme. Causes of this include Cushing's disease, dental disease, arthritis, and numerous others. In many cases the exact cause is unclear but as long as ultrasound and bile acids tests are normal most patients do not have progressive changes in their liver. While liver biopsy is not routinely performed, vacuolar hepatopathy, is noted on most biopsies. This is often non-progressive but in rare cases can be more severe and lead to liver failure.

INVOICE

41347

DATE

9/14/22



PATIENT

Simon Schmidt

- If signs of cushings disease are present recommend endocrine function testing to evaluate for cushings disease.

SPECIES

Canine

- Consider fine needle aspirate to rule out round cell neoplasia -if this is a concern.

BREED

Cockapoo

- Consider long term use of denamarin, and monitoring for the signs of cushings developing.

- A primary vacuolar hepatopathy can be breed related and is seen in Scottish Terriers, Schnauzers, Cocker spaniels etc..

SEX

Neutered Male

AGE

12 Years

WEIGHT

24.8 Pounds

INTERPRETED BY

Kathleen Sennello DVM,
MS, Diplomate ACVIM
(Small Animal Internal
Medicine)

IMAGING PERFORMED BY

Dr. Gallick

HOSPITAL NAME

Magnolia Springs VC

REFERRING VET

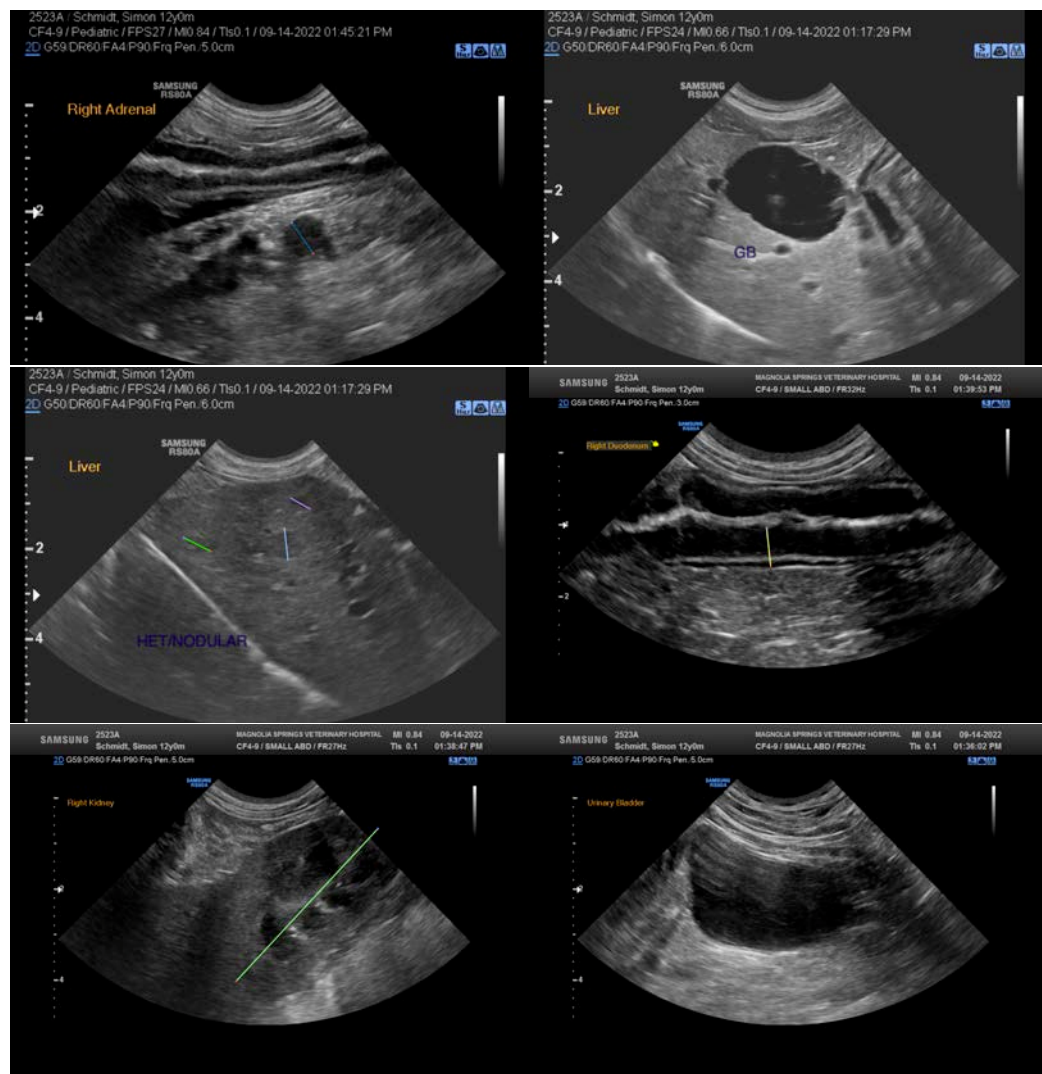
Dr. Gallick

INVOICE

41347

DATE

9/14/22





PATIENT

Simon Schmidt

SPECIES

Canine

BREED

Cockapoo

SEX

Neutered Male

AGE

12 Years

WEIGHT

24.8 Pounds

INTERPRETED BY

Kathleen Sennello DVM,
MS, Diplomate ACVIM
(Small Animal Internal
Medicine)

**IMAGING
PERFORMED BY**

Dr. Gallick

HOSPITAL NAME

Magnolia Springs VC

REFERRING VET

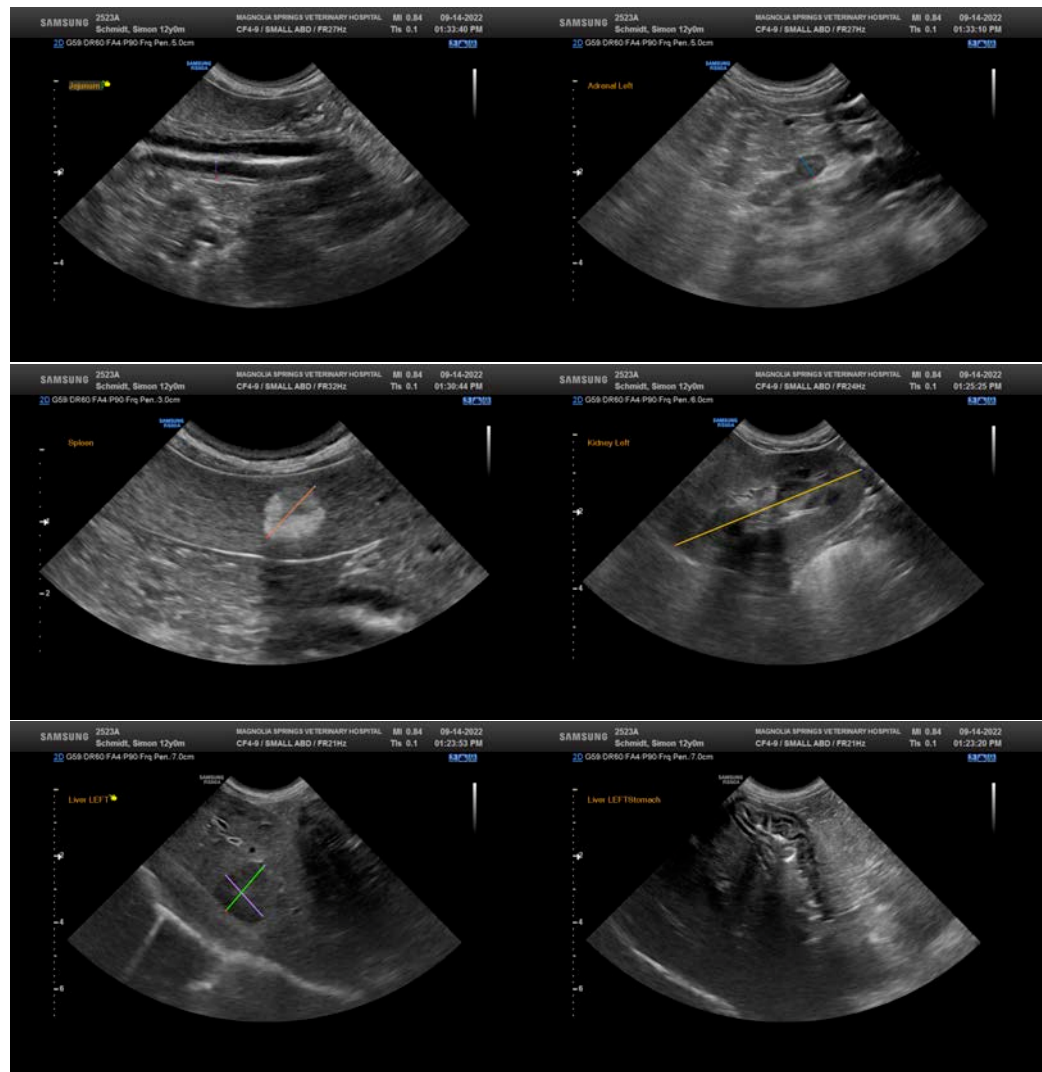
Dr. Gallick

INVOICE

41347

DATE

9/14/22



The information and recommendations provided are based on the images presented by the referring veterinarian/sonographer. No evaluation can be communicated regarding pathology that was not visible in the image/video clips provided.

Thank you for this referral. If the clinical or image interpretation does not parallel your findings or if I can be of any further assistance please contact me.

Kathleen Sennello DVM,MS, Diplomate ACVIM (Small animal Internal Medicine)

kathleen.sennello@sonopath.com