SonoPath
Clinical Sonography & Telecytology

EDUCATIONAL TELECONSULTATION SERVICES™

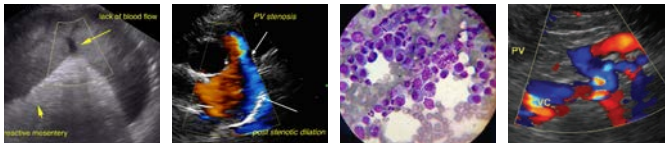

SonoPath.com™
1-800-838-4268 info@sonopath.com

PATIENT
Harvey Bramhill

SPECIES
Canine

BREED
St. Bernard X

SEX
Neutered Male

AGE
6 Years

WEIGHT
42 kg

INTERPRETED BY
Kathleen Sennello DVM, MS, Diplomate ACVIM (Small Animal Internal Medicine)

IMAGING PERFORMED BY
Dr. Donna Markland

HOSPITAL NAME
Island Mobile Paws VS

REFERRING VET
Central Island Vet Emergency Hospital

INVOICE
41268

DATE
9/13/22

PRESENTING CLINICAL SIGNS

Harvey presented on September 11 for straining to defecate and vomiting after meals for a few days. He had been seen chewing on a rubber boot by a friend about one week prior to this, but seemed fine for several days until the clinical signs occurred. Harvey is also given Milk Bone Chew sticks. On PE, Harvey was tense and reactive to abdominal palpation, but otherwise there were no significant exam findings. Harvey was given methadone, and radiographs and CBC/Chem were done. No significant findings on any diagnostic testing (radiographs are attached for review). Harvey was given 300 mL SQ fluids and cerenia in hospital and discharged on oral metronidazole on September 12 in the AM. Harvey presented again on September 12 in the PM because he still seemed nauseated/hypersalivating and was not eating well He was started on IV fluids at 200 mL/hr, cerenia, and panprotazole pending ultrasound. Harvey was given 0.2 mg/kg butorphanol IV prior to the scan.
Abnormal PE/Chem/CBC/UA Results: All WNL

ULTRASONOGRAPHIC EXAMINATION OF THE ABDOMEN

Urinary System

The urinary bladder is moderately distended with anechoic urine. The Bladder wall, trigone, ureteral papillae and visible urethra (to a depth of 2cm) appear normal with no evidence of wall thickening, mucosal irregularities, masses or cystic calculi.

The prostate is normal in size (1.33 cm) and shape for this neutered male dog. The parenchyma is homogenous and the external margins are smooth. The prostatic urethra appears normal with no evidence of irregularity, invasion, mass effect or calculi.

The left kidney has a normal shape and size (7.52 cm). Overall echogenicity is normal with adequate corticomedullary distinction and a typical 1:3 cortex:medulla ratio. There is no evidence of focal perinephric inflammation or effusion. There is no evidence of pyelectasia, nephroliths, infarcts or hydroureter. Renal vasculature is normal.

The right kidney has a normal shape and size (7.75 cm). Overall echogenicity is normal with adequate corticomedullary distinction and a typical 1:3 cortex:medulla ratio. There is no evidence of focal perinephric inflammation or effusion. There is no evidence of pyelectasia, nephroliths, infarcts or hydroureter. Renal vasculature is normal.

Adrenal Glands

The left adrenal gland is normal in size measuring 0.50 cm at the caudal pole. It is observed in its normal position cranial to the left renal artery. It is normal in appearance (uniformly hypoechoic) and shape with no evidence of a mass effect.

The right adrenal gland is normal in size measuring 0.50 cm at the caudal pole. It is observed in its normal position between the cranial aspect of the right kidney and the caudal vena cava. It is normal in appearance (uniformly hypoechoic) and shape with no evidence of a mass effect.

Spleen

The spleen is subjectively normal in size, echotexture is homogenous, and the splenic capsule is smooth with no irregularities. The blood flow through the hilus and splenic parenchyma appears normal. No focal parenchymal abnormalities are visualized.

Liver

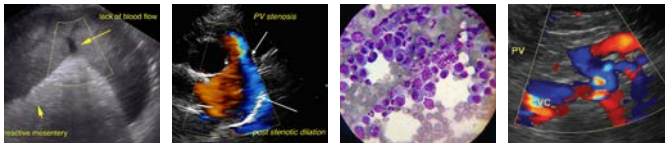

SonoPath.com™
1-800-838-4268 info@sonopath.com

PATIENT

Harvey Bramhill

SPECIES

Canine

BREED

St. Bernard X

SEX

Neutered Male

AGE

6 Years

WEIGHT

42 kg

INTERPRETED BY

Kathleen Sennello DVM, MS, Diplomate ACVIM (Small Animal Internal Medicine)

IMAGING PERFORMED BY

Dr. Donna Markland

HOSPITAL NAME

Island Mobile Paws VS

REFERRING VET

Central Island Vet Emergency Hospital

INVOICE

41268

DATE

9/13/22

The liver is subjectively normal in size, and echogenicity with smooth peripheral margins. The parenchyma is homogenous echotexture. The visible portions of the vasculature and biliary tract appear normal. No focal nodules or cystic lesions are observed.

The gallbladder lumen is moderately distended. The wall of the gall bladder is not thickened and has a smooth mucosal surface. Luminal contents are mild and primarily anechoic. The cystic and common bile ducts are normal/not visible.

Gastrointestinal

The stomach contains minimal luminal contents. It measures at a normal thickness of <0.7cm with some variability due to the presence of rugal folds. The distinction of the gastric wall layers is adequate and there is no impression of reduced peristaltic activity. No masses or focal lesions were observed.

Most of the visualized areas of duodenum, jejunum and ileum have a relatively uniform diameter with minimal fluid distension. There is a section of proximal duodenum that appears moderately fluid dilated. Wall thickness is mildly increased at .45cm . Bowel loops follow a curvilinear path with distinct wall layering maintaining the typical 1:3 muscularis:mucosa layer ratio. The areas of non dilated duodenal wall measured normal at 0.37 cm. The jejunum wall measured normal at 0.31 cm. Visualized peristalsis appears appropriate in most areas. The fluid dilated proximal duodenum appears to possibly have some evidence of stasis with chyme dilation. There is no evidence of obvious foreign material in this area of the duodenum, but continued monitoring is warranted.

The ileocecal junction was visualized and exhibited normal intact wall layering and is subjectively of normal thickness. Sections of colon are visualized with formed fecal material and gas shadowing distally. There is no observed focal or generalized colon wall thickening or loss of layering.

Pancreas

The pancreas is normal and isoechoic to surrounding mesentery. There is no evidence of nodules or cystic lesions. There is no evidence of regional mesenteric inflammation or fluid.

Free Abdomen

Evaluation of the peritoneal cavity did not reveal any evidence of effusion. There are occasional prominent mesenteric lymph nodes, with one measuring 0.78 cm. The omentum is generally of normal echogenicity.

ULTRASONOGRAPHIC FINDINGS

- Focal fluid/chyme dilation and mild thickening of the proximal duodenum – The significance of this is unclear, as no focal foreign material is visualized. Rehydration and continued monitoring is warranted.

INTERPRETATION OF THE FINDINGS & FURTHER RECOMMENDATIONS

The ultrasonographic changes observed on today's scan were relatively mild. There is a section of proximal duodenum that appears fluid/chyme dilated, and then abruptly narrows to empty duodenum. This could represent an area of diseased bowel or inflammation/focal ileus. There is no obvious shadowing foreign material in this area so less likely an area of partial obstruction without a significant shadow.

Recommend rehydration and supportive therapy with serial imaging (rads +/- us in 48hrs-sooner if not doing well) If this area appears persistently fluid dilated despite therapy and is not responding to symptomatic evaluation, then surgical evaluation could be considered. Additionally, you could give a small amount of barium and follow with radiographs to see if it traverses the duodenum normally or

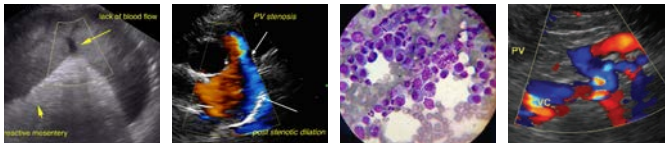

SonoPath.com
1-800-838-4268 info@sonopath.com

PATIENT

Harvey Bramhill

SPECIES

Canine

BREED

St. Bernard X

SEX

Neutered Male

AGE

6 Years

WEIGHT

42 kg

INTERPRETED BY

Kathleen Sennello DVM, MS, Diplomate ACVIM (Small Animal Internal Medicine)

IMAGING PERFORMED BY

Dr. Donna Markland

HOSPITAL NAME

Island Mobile Paws VS

REFERRING VET

Central Island Vet Emergency Hospital

INVOICE

41268

DATE

9/13/22

clings to any foreign material. Hopefully this is a case of dietary indiscretion and gastroenteritis, but continued monitoring is warranted. Additionally, a baseline cortisol should be considered, as the adrenals are subjectively normal in size but appear somewhat "flat".

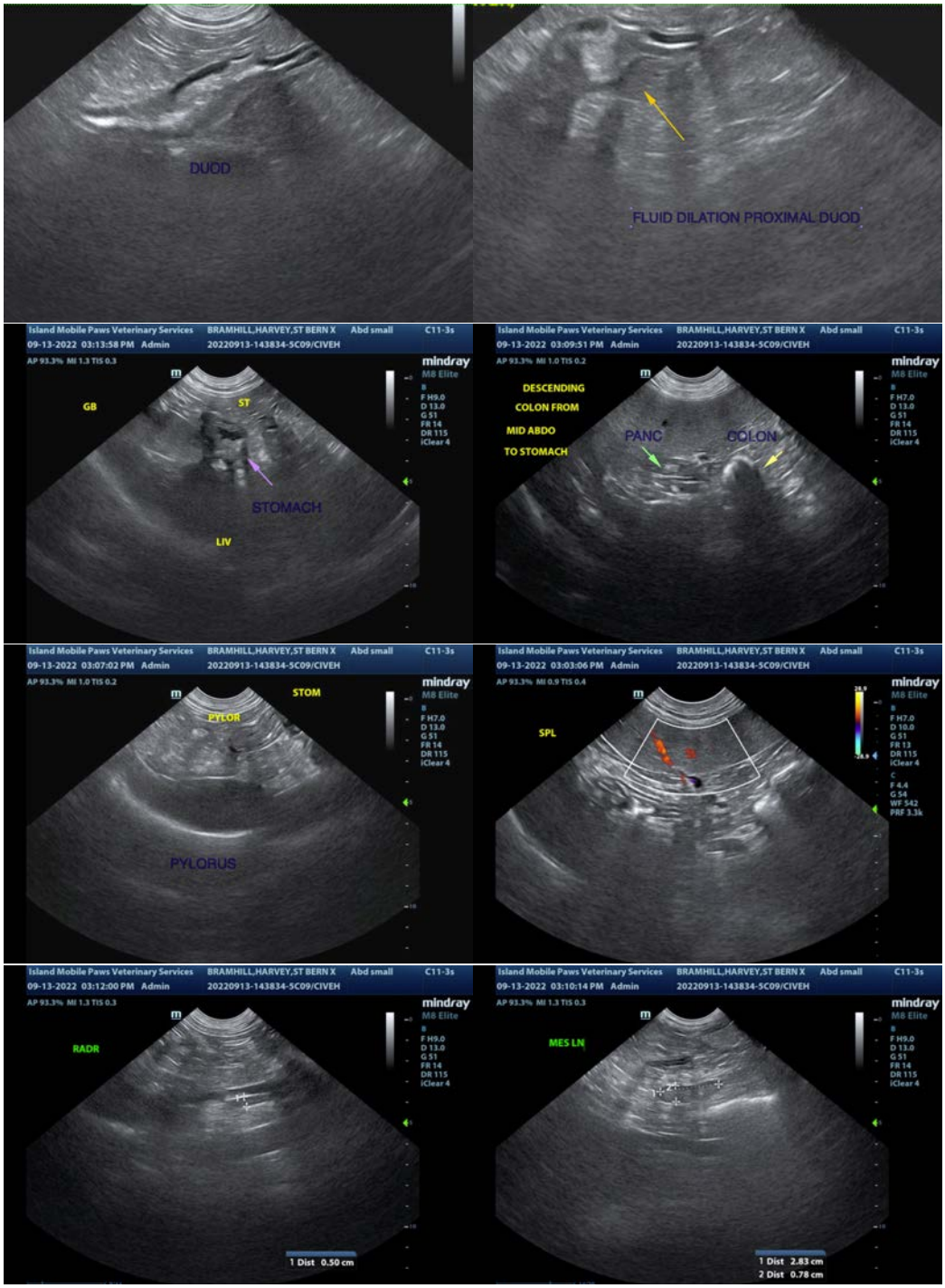

SonoPath

Clinical Sonography & Telecytology

EDUCATIONAL TELECONSULTATION SERVICES™

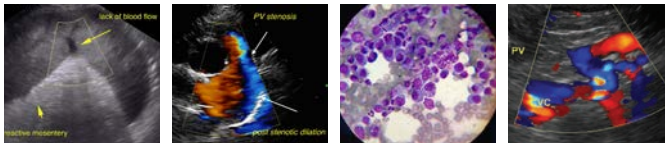

SonoPath.com™

1-800-838-4268 info@sonopath.com

PATIENT

Harvey Bramhill

SPECIES

Canine

BREED

St. Bernard X

SEX

Neutered Male

AGE

6 Years

WEIGHT

42 kg

INTERPRETED BY

Kathleen Sennello DVM, MS, Diplomate ACVIM (Small Animal Internal Medicine)

IMAGING PERFORMED BY

Dr. Donna Markland

HOSPITAL NAME

Island Mobile Paws VS

REFERRING VET

Central Island Vet Emergency Hospital

INVOICE

41268

DATE

9/13/22

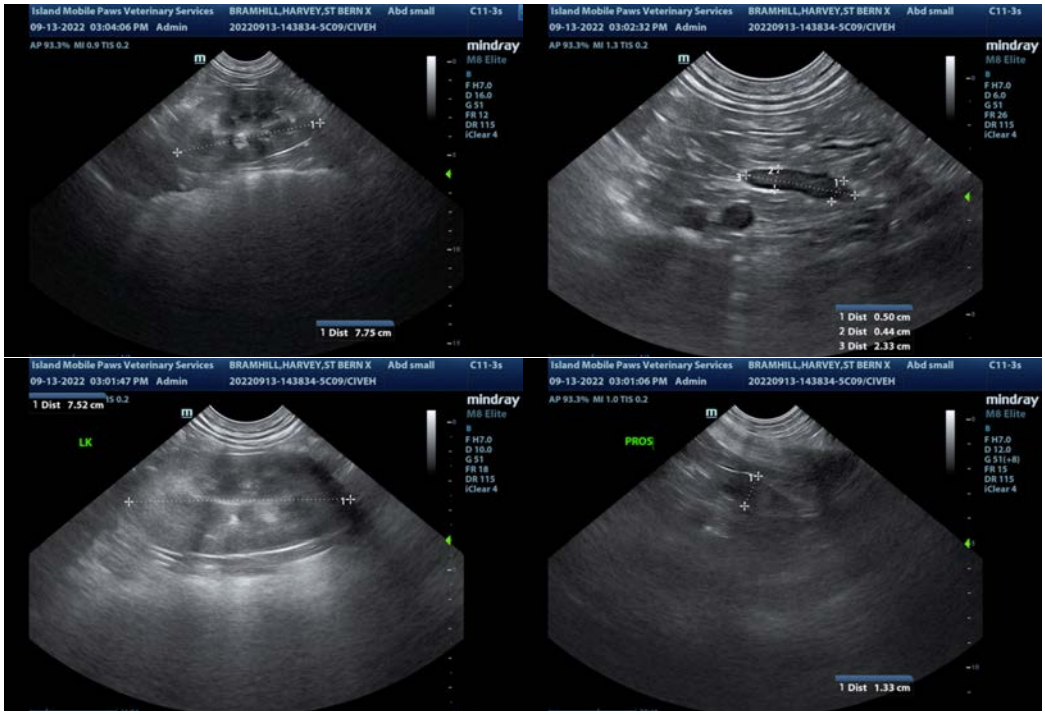

The information and recommendations provided are based on the images presented by the referring veterinarian/sonographer. No evaluation can be communicated regarding pathology that was not visible in the image/video clips provided.

Thank you for this referral. If the clinical or image interpretation does not parallel your findings or if I can be of any further assistance please contact me.

Kathleen Sennello DVM,MS, Diplomate ACVIM (Small animal Internal Medicine)

kathleen.sennello@sonopath.com