

**DATE**

9/14/21

PRESENTING CLINICAL SIGNS

History: P presented for LUTD, confirmed UTI. Chronic weight loss noted over repeat examinations from 6 pounds to 4.9 pounds in 2.5 months. Intermittent vomiting and diarrhea. Severe dental calculus on examination, muscle atrophy and no other changes.

PATIENT

Teena Wright

Current Medications: Provable PO SID, Mirtazapine 1.5-inch ribbon TD SID PRN, Renal K Powder PO BID. Lab Results: CKD stage 2, stable over multiple years, hypokalemia.

Radiographs: Not provided by the veterinarian.

Date of Previous IntraPet Ultrasound: No previous IntraPet scans.

Sedation: Sedation not required for scan.

Stat Report: STAT report not requested by the veterinarian.

SPECIES

Feline

BREED

Domestic Shorthair

SEX

Spayed Female

AGE

4/30/06

WEIGHT

4.9 lbs

ULTRASONOGRAPHIC EXAMINATION OF THE ABDOMEN**Urinary System**

The urinary bladder is moderately distended with anechoic urine. The Bladder wall, trigone, ureteral papillae and visible urethra (to a depth of 2cm) appear normal with no evidence of wall thickening, mucosal irregularities, masses or cystic calculi.

The left kidney has a normal shape and size (3.1 cm). Overall echogenicity is slightly hyperechoic with poor corticomedullary distinction and a typical 1:3 cortex:medulla ratio. There is no evidence of perinephric inflammation or effusion. A large, non-obstructive nephrolith was noted. There is no evidence of pyelectasia, infarcts or hydroureter. Renal vasculature is normal.

The right kidney has a normal shape and size (3.07 cm). Overall echogenicity is slightly hyperechoic with poor corticomedullary distinction and a typical 1:3 cortex:medulla ratio. There is no evidence of perinephric inflammation or effusion. A large, non-obstructive nephrolith was noted. There is no evidence of pyelectasia, infarcts or hydroureter. Renal vasculature is normal.

INTERPRETED BY

Kathleen Sennello
DVM, MS, Diplomate
ACVIM (Small Animal
Internal Medicine)

Adrenal Glands

The region of left adrenal (Cranial to left renal artery) is unremarkable but the adrenal is not distinctly visualized. No evidence of a mass effect.

The region of the right adrenal (between right cranial kidney and vena cava) is unremarkable, but the adrenal is not distinctly visualized. No evidence of a mass effect.

HOSPITAL NAME

Cat Hospital at Towson

Spleen

The spleen is subjectively normal in size, echotexture is homogenous, and the splenic capsule is smooth with no irregularities. The blood flow through the hilus and splenic parenchyma appears normal. No focal parenchymal abnormalities are visualized.

REFERRING VET

Dr. Fitzgerald

Liver

The liver is subjectively normal in size, and echogenicity with smooth peripheral margins. The parenchyma is homogenous echotexture. The visible portions of the vasculature and biliary tract appear normal. No focal nodules or cystic lesions are observed. The gallbladder lumen is moderately distended. The wall of the gall bladder is not thickened and has a smooth mucosal surface. Luminal contents are primarily anechoic. The cystic and common bile ducts are normal/not visible.

INVOICE

91811

Gastrointestinal

The stomach contains minimal luminal contents. It measures at a normal thickness of <0.36cm with some variability due to the presence of rugal folds. The distinction of the gastric wall layers is adequate and there is no impression of reduced peristaltic activity. No masses or focal lesions were observed.

The visualized areas of duodenum, jejunum and ileum have a uniform diameter with minimal fluid distension. Wall thickness is normal to slightly increased. Bowel loops follow a typical curvilinear path with distinct wall layering, but some areas display a prominent muscularis layer which does not display the typical 1:3 muscularis:mucosa layer ratio. The jejunum measured 0.24 cm. Visualized peristalsis appears appropriate. There were no focal lesions consistent with obstruction or a mass effect observed.

The ileocecal junction was visualized and exhibited normal intact wall layering and is subjectively of normal thickness. Sections of colon are visualized with formed fecal material and gas shadowing distally. There is no observed focal or generalized colon wall thickening or loss of layering.

Pancreas

The pancreas is large and hypoechoic to surrounding mesentery. There is no evidence of nodules or cystic lesions. There is evidence of regional mesenteric inflammation. Consistent with mild/moderate pancreatitis.

Free Abdomen

Evaluation of the peritoneal cavity did not reveal any evidence of effusion, or subjective lymphadenomegally. The Medial iliac nodes appear normal and there was no evidence of a caudal aortic thrombus at the bifurcation. The omentum is of normal uniform echogenicity.

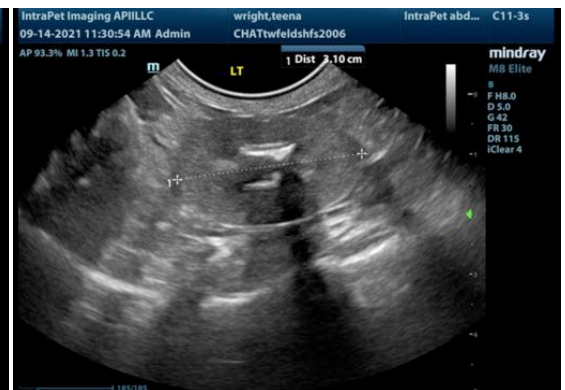
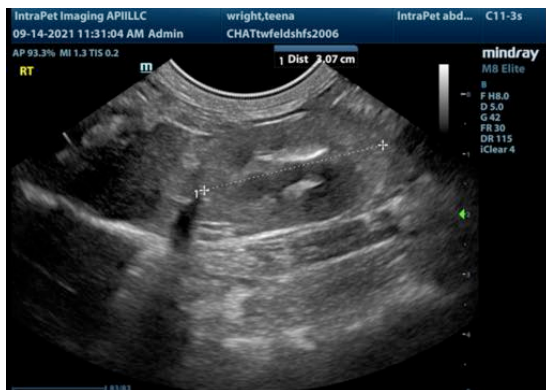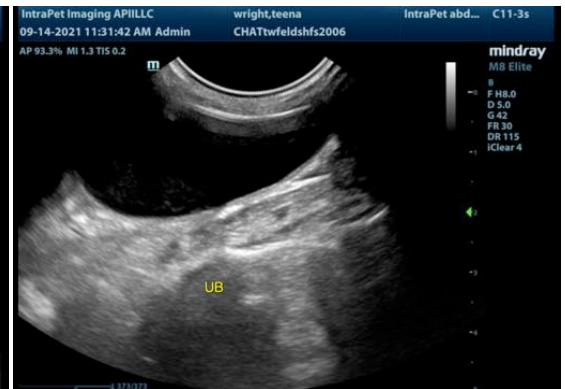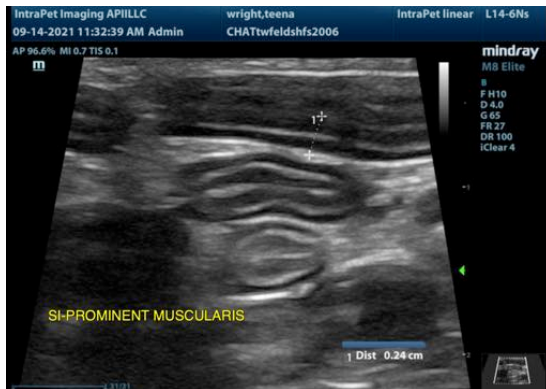
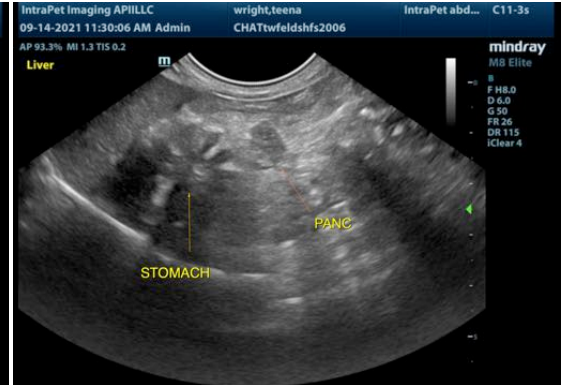
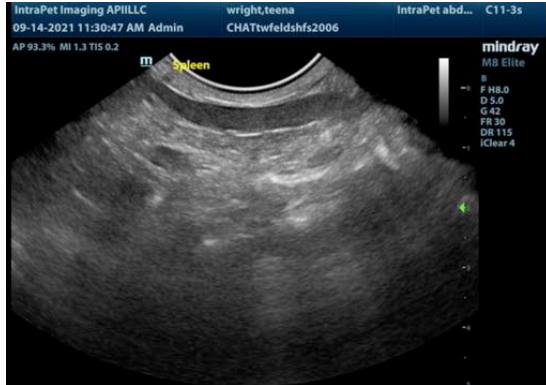ULTRASONOGRAPHIC FINDINGS

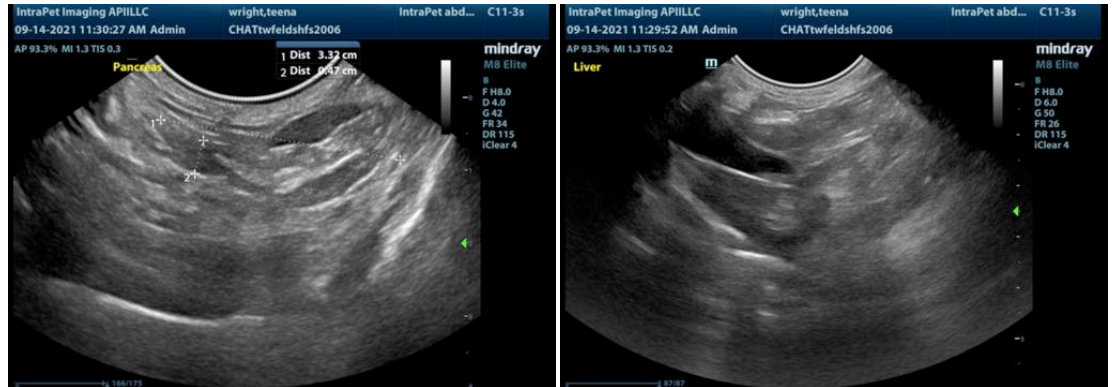
PRIMARY FINDINGS:

- Prominent muscularis layer to the small intestine. The small intestinal wall changes are most consistent with an inflammatory process (i.e., inflammatory bowel disease) with a low possibility of emerging lymphoma.
- Mild to moderate pancreatic inflammation. The pancreatic changes are most consistent with mild/moderate pancreatitis/pancreatic infiltration. I recommend fPLI testing and continued monitoring for improvement or possible development of a pancreatic abscess. Consider FNA if not improving.
- Decreased corticomedullary distinction in both kidneys with left-sided, non-obstructive nephrolith. Mild loss of corticomedullary distinction in both kidneys could be consistent with chronic degenerative disease or interstitial nephrosis.

INTERPRETATION OF THE FINDINGS & FURTHER RECOMMENDATIONS

The pancreas is large and prominent. It can be consistent with current pancreatitis or recent episode of pancreatitis. Consider a GI panel with quantitative fPLI, B12 and folate to further evaluate the pancreas and the small intestine. Additionally, the small intestine has a prominent muscularis layer. This can be found in some older cats, but can also be associated with GI disease. The primary concern would be pancreatitis +/- underlying small intestinal issues. I recommend symptomatic treatment for pancreatitis and possible diet change. If symptoms are not improving you may need to consider intestinal biopsies.





The information and recommendations provided are based on the images presented by the referring veterinarian. No evaluation can be communicated regarding pathology that was not visible in the image/video clips provided.

Thank you for this referral. If the clinical or image interpretation does not parallel your findings or if I can be of any further assistance please contact me.

Kathleen Sennello DVM,MS, Diplomate ACVIM (Small animal Internal Medicine)
kathleen.sennello@sonopath.com