



**PATIENT**

Lucky Johnson

**PRESENTING CLINICAL SIGNS**

P presented for wellness exam and interested in doing a dental/oral procedure. On screening bw inc ALP noted, no PU/PD/PP reported by O.

**SPECIES**

Canine

Abnormal PE/Chem/CBC/UA Results: PE: grade 4 dental dz, halitosis, all else WNL SW: CBC: plt ct: 415H; Chem: ALP: 445H, gluc: 141H, triglyc: 305H T4: 3.2; UA: SG: 1.044, 1+ prot, quiet sediment

**BREED**

Terrier

**ULTRASONOGRAPHIC EXAMINATION OF THE ABDOMEN**

**Urinary System**

**SEX**

Neutered Male

The urinary bladder is moderately distended with anechoic urine. The Bladder wall, trigone, ureteral papillae and visible urethra (to a depth of 2cm) appear normal with no evidence of wall thickening, mucosal irregularities, masses or cystic calculi.

**AGE**

9 Years

The prostate is normal in size (0.54 cm) and shape for this neutered male dog. The parenchyma is homogenous and the external margins are smooth. The prostatic urethra appears normal with no evidence of irregularity, invasion, mass effect or calculi.

**WEIGHT**

21 Pounds

The left kidney has a normal shape and size (4.68 cm). Overall echogenicity is normal with adequate corticomedullary distinction and a typical 1:3 cortex:medulla ratio. There is no evidence of focal perinephric inflammation or effusion. There is no evidence of pyelectasia, nephroliths, infarcts or hydroureter. Renal vasculature is normal.

**INTERPRETED BY**

Kathleen Sennello DVM,  
MS, Diplomate ACVIM  
(Small Animal Internal  
Medicine)

The right kidney has a normal shape and size (4.75 cm) with pinpoint non-obstructive nephroliths. Overall echogenicity is normal with adequate corticomedullary distinction and a typical 1:3 cortex:medulla ratio. There is no evidence of focal perinephric inflammation or effusion. There is no evidence of pyelectasia, nephroliths, infarcts or hydroureter. Renal vasculature is normal.

**IMAGING PERFORMED BY**

Dr. Megan Cassels-  
Conway

**Adrenal Glands**

The left adrenal gland is normal in size measuring 0.59 cm at the caudal pole. It is observed in its normal position cranial to the left renal artery. It is normal in appearance (uniformly hypoechoic) and shape with no evidence of a mass effect.

**HOSPITAL NAME**

Central Broward AH

The right adrenal gland is normal in size measuring 0.58 cm at the caudal pole. It is observed in its normal position between the cranial aspect of the right kidney and the caudal vena cava. It is normal in appearance (uniformly hypoechoic) and shape with no evidence of a mass effect.

**Spleen**

The spleen is subjectively normal in size, echotexture is homogenous, and the splenic capsule is smooth with no irregularities. The blood flow through the hilus and splenic parenchyma appears normal. No focal parenchymal abnormalities are visualized.

**REFERRING VET**

Dr. Janeen Lezcano

**Liver**

**INVOICE**

41281

The liver is subjectively normal in size, and echogenicity with smooth peripheral margins. The parenchyma is heterogenous in echotexture with subtle, indistinct focal mottling. The visible portions of the vasculature and biliary tract appear normal. There are numerous indistinct hypoechoic, irregular nodules throughout the parenchyma measuring 0.63 cm, 0.62 cm, etc. Additionally, there are two

**DATE**

9/13/22



**PATIENT**

Lucky Johnson

discrete hyperechoic nodules visualized measuring 0.78 cm x 0.55 cm and 0.68 cm x 0.61 cm. None of these lesions disrupt normal architecture.

**SPECIES**

Canine

The gallbladder lumen is moderately distended. The wall of the gall bladder is not thickened and has a smooth mucosal surface. Luminal contents are mild and primarily anechoic. The cystic and common bile ducts are normal/not visible.

**Gastrointestinal**

**BREED**

Terrier

The stomach contains minimal luminal contents. It measures at a normal thickness of <0.7cm with some variability due to the presence of rugal folds. The distinction of the gastric wall layers is adequate and there is no impression of reduced peristaltic activity. No masses or focal lesions were observed.

**SEX**

Neutered Male

The visualized areas of duodenum, jejunum and ileum have a relatively uniform diameter with minimal fluid distension. Wall thickness is normal. Bowel loops follow a curvilinear path with distinct wall layering maintaining the typical 1:3 muscularis:mucosa layer ratio. The duodenum measured as normal (between 0.3-0.5cm in wall thickness) and the jejunum measured as normal (between 0.2-0.47cm.) Visualized peristalsis appears appropriate. There were no focal lesions consistent with obstruction or a mass effect observed.

**AGE**

9 Years

The ileocecal junction was visualized and exhibited normal intact wall layering and is subjectively of normal thickness. Sections of colon are visualized with formed fecal material and gas shadowing distally. There is no observed focal or generalized colon wall thickening or loss of layering.

**WEIGHT**

21 Pounds

**Pancreas**

The pancreas is normal and isoechoic to surrounding mesentery. There is no evidence of nodules or cystic lesions. There is no evidence of regional mesenteric inflammation or fluid.

**INTERPRETED BY**

Kathleen Sennello DVM,  
MS, Diplomate ACVIM  
(Small Animal Internal  
Medicine)

**Free Abdomen**

Evaluation of the peritoneal cavity did not reveal any evidence of effusion, or subjective lymphadenomegaly. The Medial iliac nodes appear normal and there was no evidence of a caudal aortic thrombus at the bifurcation. The omentum is of normal uniform echogenicity.

**ULTRASONOGRAPHIC FINDINGS**

**IMAGING PERFORMED BY**

Dr. Megan Cassels-  
Conway

**HOSPITAL NAME**

Central Broward AH

- Heterogeneous liver with ill-defined hypoechoic nodules and two well defined hyperechoic nodules – The diffuse hepatic changes are non-specific and could be consistent with vacuolar hepatopathy, nodular hyperplasia, inflammatory/immune-mediated disease, fibrosis, extramedullary hematopoiesis, toxic hepatopathy (e.g., copper), infiltrative neoplasia (less likely) or other hepatopathy. The nodules observed trend toward a more benign process but underlying neoplasia cannot be ruled out.
- Pinpoint non-obstructive nephroliths visualized within the right kidney – The hyperechoic mineralized foci observed at the corticomedullary junction of the right kidney are consistent with small, non-obstructive nephroliths.

**REFERRING VET**

Dr. Janeen Lezcano

**INTERPRETATION OF THE FINDINGS & FURTHER RECOMMENDATIONS**

**INVOICE**

41281

The liver is heterogeneous with ill-defined hypoechoic nodules throughout the parenchyma and two hyperechoic nodules. The appearance of these nodules trends towards a benign process, as no criteria for malignancy are present, although an underlying neoplastic process cannot be definitively ruled out. There are no significant changes associated with the biliary tract, so these findings are supportive of a primary hepatopathy. These are my recommendations for a primary ALP elevation:

**DATE**

9/13/22



**PATIENT**

Lucky Johnson

**SPECIES**

Canine

**BREED**

Terrier

**SEX**

Neutered Male

**AGE**

9 Years

**WEIGHT**

21 Pounds

- Induction phenomena are the most common cause for an elevation in ALP. These are systemic illnesses that 'turn on' the liver enzyme. Causes of this include Cushing's disease, dental disease, arthritis, and numerous others. In many cases the exact cause is unclear but as long as ultrasound and bile acids tests are normal most patients do not have progressive changes in their liver. While liver biopsy is not routinely performed, vacuolar hepatopathy, is noted on most biopsies. This is often non-progressive but in rare cases can be more severe and lead to liver failure.
- If signs of cushings disease are present recommend endocrine function testing to evaluate for cushings disease.
- Consider fine needle aspirate to rule out round cell neoplasia -if this is a concern.
- If a cause for the ALP elevation is not identified: I recommend recheck general blood work every 6 months, ultrasound once per year, and bile acids test every 1-2 years based on other results. If the ALP continues to climb a biopsy could be considered.
- Consider long term use of denamarin, and monitoring for the signs of cushings developing.
- A primary vacuolar hepatopathy can be breed related and is seen in Scottish Terriers, Schnauzers, Cocker spaniels etc..

Provided a liver function test is normal, there is unlikely to be a significant risk associated with a dental procedure.

**INTERPRETED BY**

Kathleen Sennello DVM,  
MS, Diplomate ACVIM  
(Small Animal Internal  
Medicine)

**IMAGING PERFORMED BY**

Dr. Megan Cassels-  
Conway

**HOSPITAL NAME**

Central Broward AH

**REFERRING VET**

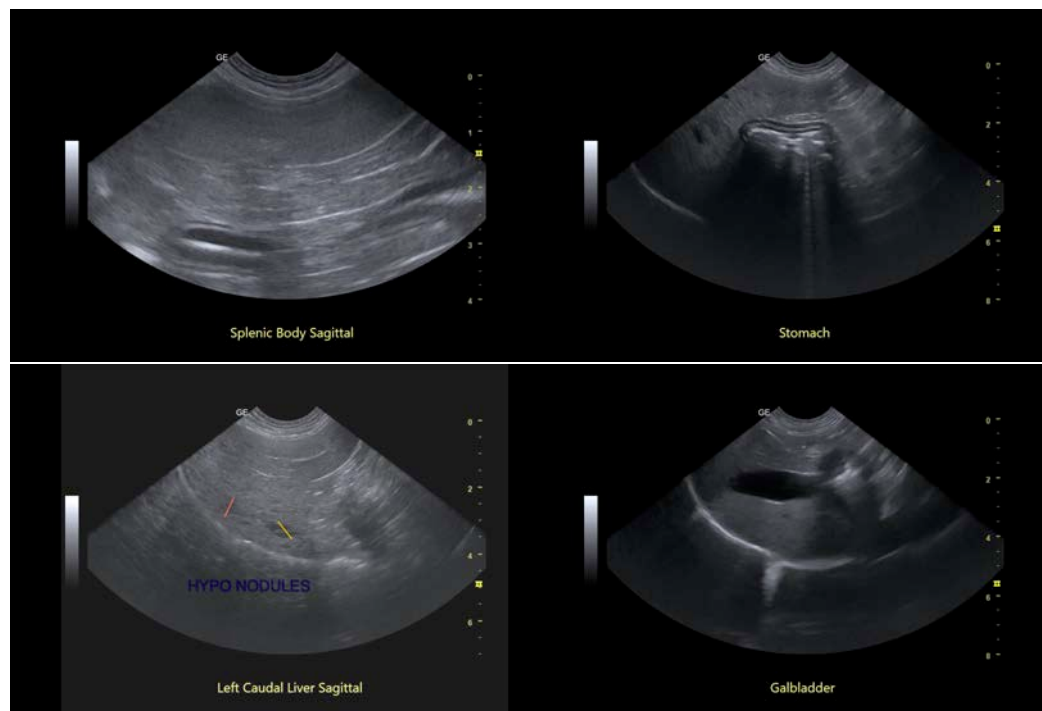
Dr. Janeen Lezcano

**INVOICE**

41281

**DATE**

9/13/22





**PATIENT**

Lucky Johnson

**SPECIES**

Canine

**BREED**

Terrier

**SEX**

Neutered Male

**AGE**

9 Years

**WEIGHT**

21 Pounds

**INTERPRETED BY**

Kathleen Sennello DVM,  
MS, Diplomate ACVIM  
(Small Animal Internal  
Medicine)

**IMAGING  
PERFORMED BY**

Dr. Megan Cassels-  
Conway

**HOSPITAL NAME**

Central Broward AH

**REFERRING VET**

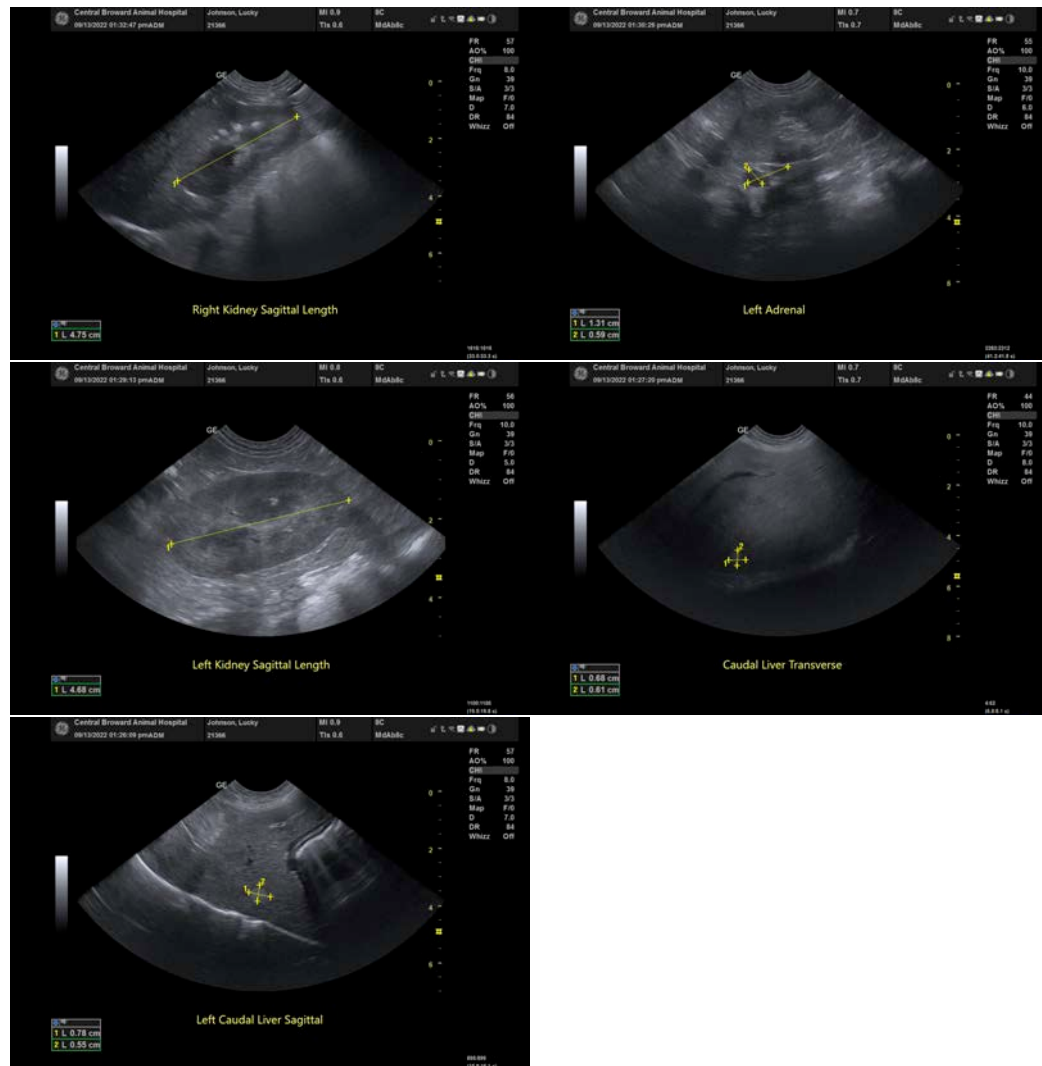
Dr. Janeen Lezcano

**INVOICE**

41281

**DATE**

9/13/22



The information and recommendations provided are based on the images presented by the referring veterinarian/sonographer. No evaluation can be communicated regarding pathology that was not visible in the image/video clips provided.

Thank you for this referral. If the clinical or image interpretation does not parallel your findings or if I can be of any further assistance please contact me.

Kathleen Sennello DVM,MS, Diplomate ACVIM (Small animal Internal Medicine)

kathleen.sennello@sonopath.com