



PATIENT

Leelu Strutt

PRESENTING CLINICAL SIGNS

Previously diagnosed with diabetes at last clinic and possible IBD? Is on Lantus insulin.
Abnormal PE/Chem/CBC/UA Results: Increased glucose 19.2, ALT increased 144, decreased K 3.3.
Urinalysis showed 4+ glucose, neg ketones, sp grav greater than 1.050.

SPECIES

Feline

ULTRASONOGRAPHIC EXAMINATION OF THE ABDOMEN

Urinary System

BREED

DMH

The urinary bladder is moderately distended with anechoic urine. The Bladder wall, trigone, ureteral papillae and visible urethra (to a depth of 2cm) appear normal with no evidence of wall thickening, mucosal irregularities, masses or cystic calculi.

SEX

Spayed Female

The left kidney has a normal shape and size (3.84 cm) with mild pyelectasia of 0.19 cm. Overall echogenicity is slightly hyperechoic with poor corticomedullary distinction and a typical 1:3 cortex:medulla ratio. There is no evidence of perinephric inflammation or effusion. There is no evidence of nephroliths, infarcts or hydroureter. Renal vasculature is normal.

AGE

7 Years

The right kidney has a normal shape and size (3.38 cm). Overall echogenicity is slightly hyperechoic with poor corticomedullary distinction and a typical 1:3 cortex:medulla ratio. There is no evidence of perinephric inflammation or effusion. There is no evidence of pyelectasia, nephroliths, infarcts or hydroureter. Renal vasculature is normal.

WEIGHT

11.3 Pounds

Adrenal Glands

The left adrenal gland is normal in size measuring 0.32 cm at the caudal pole. It is observed in its normal position cranial to the left renal artery. It is normal in appearance (uniformly hypoechoic) and shape with no evidence of a mass effect.

INTERPRETED BY

Kathleen Sennello
DVM, MS, Diplomate
ACVIM (Small Animal
Internal Medicine)

The right adrenal gland is normal in size measuring 0.35 cm at the caudal pole. It is observed in its normal position between the cranial aspect of the right kidney and the caudal vena cava. It is normal in appearance (uniformly hypoechoic) and shape with no evidence of a mass effect.

Spleen

IMAGING PERFORMED BY

Crystal Hill

The spleen is subjectively normal in size, echotexture is homogenous, and the splenic capsule is smooth with no irregularities. The blood flow through the hilus and splenic parenchyma appears normal. No focal parenchymal abnormalities are visualized.

HOSPITAL NAME

AH of Stoney Creek

Liver

The liver is subjectively normal in size, and echogenicity with smooth peripheral margins. The parenchyma is homogenous echotexture. The visible portions of the vasculature and biliary tract appear normal. No focal nodules or cystic lesions are observed.

REFERRING VET

Dr. Ozimok

The gallbladder lumen is moderately distended. The wall of the gall bladder is not thickened and has a smooth mucosal surface. Luminal contents are primarily anechoic. The cystic and common bile ducts are normal/not visible.

INVOICE

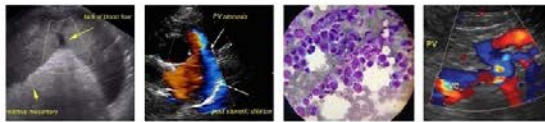
25333

Gastrointestinal

The stomach contains minimal luminal contents. It measures at a normal thickness of <0.36cm with some variability due to the presence of rugal folds. The distinction of the gastric wall layers is adequate and there is no impression of reduced peristaltic activity. No masses or focal lesions were observed.

DATE

9/10/21



PATIENT

Leelu Strutt

The visualized areas of duodenum, jejunum and ileum have a relatively uniform diameter with minimal fluid distension. Wall thickness is normal. Bowel loops follow a curvilinear path with distinct wall layering maintaining the typical 1:3 muscularis:mucosa layer ratio. Jejunum wall measured 0.19 cm. Visualized peristalsis appears appropriate. There were no focal lesions consistent with obstruction or a mass effect observed.

SPECIES

Feline

The ileocecal junction was visualized and exhibited normal intact wall layering and is subjectively of normal thickness. Sections of colon are visualized with formed fecal material and gas shadowing distally. There is no observed focal or generalized colon wall thickening or loss of layering.

BREED

DMH

Pancreas

The pancreas is normal and isoechoic to surrounding mesentery. There is no evidence of nodules or cystic lesions. There is no evidence of regional mesenteric inflammation or fluid.

SEX

Spayed Female

Free Abdomen

Evaluation of the peritoneal cavity did not reveal any evidence of effusion, or subjective lymphadenomegaly. The Medial iliac nodes appear normal and there was no evidence of a caudal aortic thrombus at the bifurcation. The omentum is of normal uniform echogenicity.

AGE

7 Years

ULTRASONOGRAPHIC FINDINGS

- Mildly reduced corticomedullary distinction in both kidneys and mild left-sided pyelectasia – Mild loss of corticomedullary distinction in both kidneys could be consistent with chronic degenerative disease or interstitial nephrosis. Pyelectasia of the left kidney could be consistent with pyelonephritis, chronic renal disease, secondary to PU/PD or fluid therapy (if applicable), other.

WEIGHT

11.3 Pounds

INTERPRETED BY

Kathleen Sennello
DVM, MS, Diplomate
ACVIM (Small Animal
Internal Medicine)

INTERPRETATION OF THE FINDINGS & FURTHER RECOMMENDATIONS

The changes observed were mild. The kidney changes could very well be age related, and the left-sided pyelectasia could be consistent with PU/PD or very mild pyelonephritis. Recommend urinalysis and culture if not already done. No lesions were observed in the liver, so at this point I would consider working on regulating the diabetes, and reassess liver values in the near future. If liver enzymes continue to rise, you could consider a liver function test and a fine needle aspirate of the liver. I did not see any evidence of concurrent pancreatitis. If GI signs are present, you could consider a quantitative fPLI, B12 and folate to further evaluate for these issues.

IMAGING PERFORMED BY

Crystal Hill

HOSPITAL NAME

AH of Stoney Creek

REFERRING VET

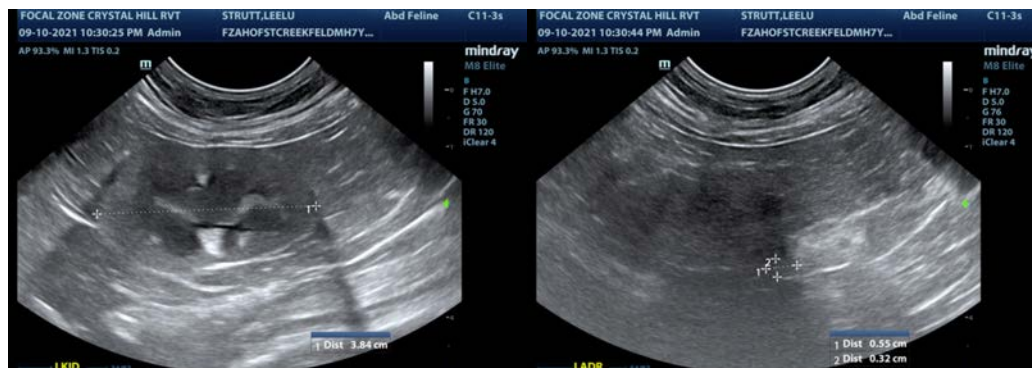
Dr. Ozimok

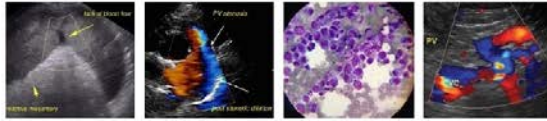
INVOICE

25333

DATE

9/10/21





PATIENT

Leelu Strutt

SPECIES

Feline

BREED

DMH

SEX

Spayed Female

AGE

7 Years

WEIGHT

11.3 Pounds

INTERPRETED BY

Kathleen Sennello
DVM, MS, Diplomate
ACVIM (Small Animal
Internal Medicine)

**IMAGING
PERFORMED BY**

Crystal Hill

HOSPITAL NAME

AH of Stoney Creek

REFERRING VET

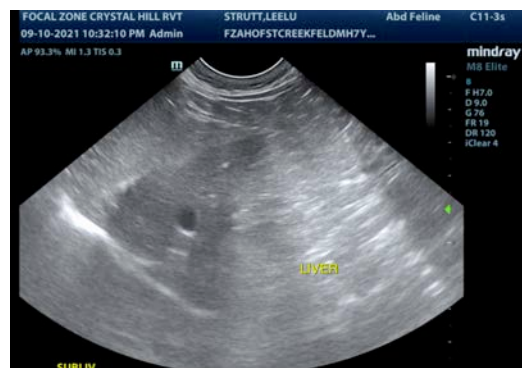
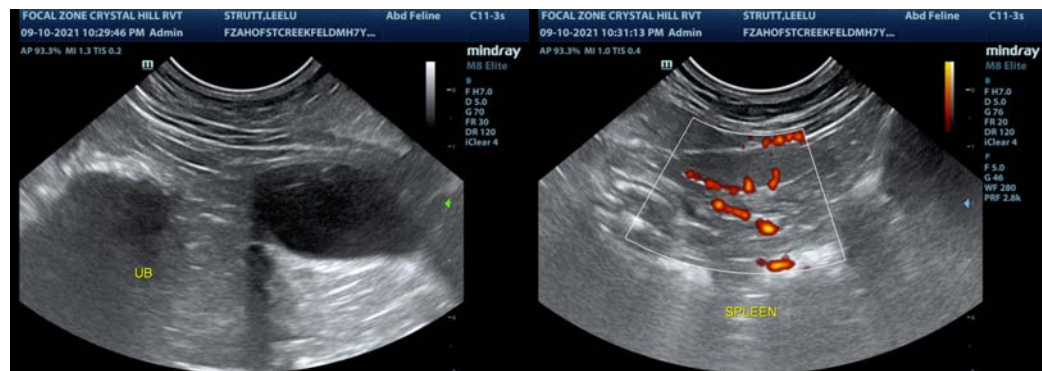
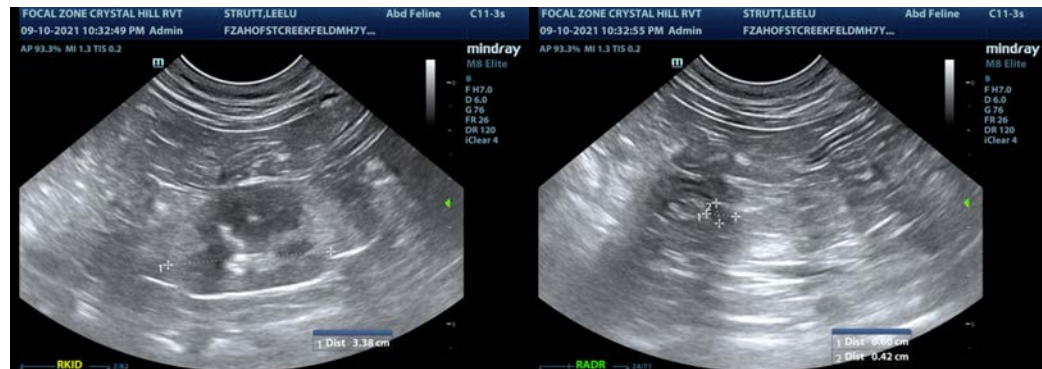
Dr. Ozimok

INVOICE

25333

DATE

9/10/21



The information and recommendations provided are based on the images presented by the referring veterinarian. No evaluation can be communicated regarding pathology that was not visible in the image/video clips provided.

Thank you for this referral. If the clinical or image interpretation does not parallel your findings or if I can be of any further assistance please contact me.

Kathleen Sennello DVM,MS, Diplomate ACVIM (Small animal Internal Medicine)

kathleen.sennello@sonopath.com