



**PATIENT**

Max Detitta

**SPECIES**

Canine

**BREED**

Welsh Terrier

**SEX**

Neutered Male

**AGE**

10 Years

**WEIGHT**

29 Pounds

**INTERPRETED BY**

Kathleen Sennello DVM,  
MS, Diplomate ACVIM  
(Small Animal Internal  
Medicine)

**IMAGING  
PERFORMED BY**

Dr. Scott

**HOSPITAL NAME**

Ho Ho Kus VH

**REFERRING VET**

Dr. Eisenberg

**INVOICE**

12896

**DATE**

9/1/21

**PRESENTING CLINICAL SIGNS**

History: clinically WNL, work up for PLN, UPC 1.2

Abnormal PE/Chem/CBC/UA Results: PE WNL CBC/Chem WNL, LDDS WNL, urine culture negative

**ULTRASONOGRAPHIC EXAMINATION OF THE ABDOMEN**

**Urinary System**

The urinary bladder is moderately distended with anechoic urine. The Bladder wall, trigone, ureteral papillae and visible urethra (to a depth of 2cm) appear normal with no evidence of wall thickening, mucosal irregularities, masses or cystic calculi.

The prostate is normal in size (0.7 cm) and shape for this neutered male dog. The parenchyma is homogenous and the external margins are smooth. The prostatic urethra appears normal with no evidence of irregularity, invasion, mass effect or calculi.

The right kidney has a normal shape and size (5.0 cm). Overall echogenicity is normal with adequate corticomedullary distinction and a typical 1:3 cortex:medulla ratio. There is no evidence of perinephric inflammation or effusion. There is no evidence of pyelectasia, nephroliths, infarcts or hydronephrosis. Renal vasculature is normal.

The left kidney has a normal shape and size (4.6 cm). Overall echogenicity is normal with adequate corticomedullary distinction and a typical 1:3 cortex:medulla ratio. There is no evidence of perinephric inflammation or effusion. There is no evidence of pyelectasia, nephroliths, infarcts or hydronephrosis. Renal vasculature is normal.

**Adrenal Glands**

The left adrenal gland is normal in size measuring 0.56 cm. It is observed in its normal position cranial to the left renal artery. It is normal in appearance (uniformly hypoechoic) and shape with no evidence of a mass effect.

The region of the right adrenal (between right cranial kidney and vena cava) is unremarkable, but the adrenal is not distinctly visualized. No evidence of a mass effect.

**Spleen**

The spleen is subjectively normal in size, echotexture is homogenous, and the splenic capsule is smooth with no irregularities. The blood flow through the hilus and splenic parenchyma appears normal. There is a small hypoechoic nodule visualized, measuring 0.7 cm which does not deviate the capsule.

**Liver**

The liver is subjectively normal in size, and echogenicity with smooth peripheral margins. The parenchyma is heterogenous in echotexture with subtle, indistinct focal mottling. The visible portions of the vasculature and biliary tract appear normal. There is a slightly irregular hyperechoic nodule visualized towards the periphery of the liver, measuring 1.0 cm and numerous ill-defined hypoechoic nodules varying in size from 0.3 cm to 0.5 cm. The gall bladder lumen is moderately distended. The wall of the gall bladder is not thickened and has a smooth mucosal surface. Luminal contents are primarily anechoic. The cystic and common bile ducts are normal/not visible.

**Gastrointestinal**



**PATIENT**

Max Detitta

The stomach contains minimal luminal contents. It measures at a normal thickness of <0.7cm with some variability due to the presence of rugal folds. The distinction of the gastric wall layers is adequate and there is no impression of reduced peristaltic activity. No masses or focal lesions were observed.

**SPECIES**

Canine

The visualized areas of duodenum, jejunum and ileum have a relatively uniform diameter with minimal fluid distension. Wall thickness is normal. Bowel loops follow a curvilinear path with distinct wall layering maintaining the typical 1:3 muscularis:mucosa layer ratio. The duodenum measured as normal (between 0.3-0.5cm in wall thickness) and the jejunum measured as normal (between 0.2-0.47cm.)

**BREED**

Welsh Terrier

Visualized peristalsis appears appropriate. There were no focal lesions consistent with obstruction or a mass effect observed.

**SEX**

Neutered Male

The ileocecal junction was visualized and exhibited normal intact wall layering and is subjectively of normal thickness. Sections of colon are visualized with formed fecal material and gas shadowing distally. There is no observed focal or generalized colon wall thickening or loss of layering.

***Pancreas***

**AGE**

10 Years

The pancreas is normal and isoechoic to surrounding mesentery. There is no evidence of nodules or cystic lesions. There is no evidence of regional mesenteric inflammation or fluid.

***Free Abdomen***

**WEIGHT**

29 Pounds

Evaluation of the peritoneal cavity did not reveal any evidence of effusion, or subjective lymphadenomegaly. The Medial iliac nodes appear normal and there was no evidence of a caudal aortic thrombus at the bifurcation. The omentum is of normal uniform echogenicity.

**ULTRASONOGRAPHIC FINDINGS**

**INTERPRETED BY**

Kathleen Sennello DVM,  
MS, Diplomate ACVIM  
(Small Animal Internal  
Medicine)

- Small hypoechoic splenic nodule- There is a non-cavitated, hypoechoic splenic nodule visualized. Differentials include lymphoid hyperplasia, extramedullary hematopoiesis, infiltrative neoplasia, inflammation, other. Cytology or histopathology would be necessary to get a definitive diagnosis
- Heterogeneous liver with ill-defined hypoechoic nodules and one hyperechoic nodule- The diffuse hepatic changes are non-specific and could be consistent with vacuolar hepatopathy, nodular hyperplasia, inflammatory/immune-mediated disease, fibrosis, extramedullary hematopoiesis, toxic hepatopathy (e.g., copper), infiltrative neoplasia (less likely) or other hepatopathy

**IMAGING PERFORMED BY**

Dr. Scott

**HOSPITAL NAME**

Ho Ho Kus VH

**INTERPRETATION OF THE FINDINGS & FURTHER RECOMMENDATIONS**

The ultrasonographic findings were relatively mild and non-specific. There is a hypoechoic nodule in the spleen. Options moving forward include continued monitoring with ultrasound, fine needle aspirate or splenectomy. Additionally, the liver is somewhat nodular. These favor a more benign process, but there is a more hyperechoic nodule that shows irregular towards the periphery of the liver which could be aspirated as it looks somewhat dissimilar to the other nodules.

**REFERRING VET**

Dr. Eisenberg

**INVOICE**

12896

I think it's unlikely that any of these factors are complicating or causing the protein losing nephropathy reported. If not already done, I recommend blood pressure evaluation, evaluation for vector borne diseases and chest radiographs.

**DATE**

9/1/21



**PATIENT**

Max Detitta

**SPECIES**

Canine

**BREED**

Welsh Terrier

**SEX**

Neutered Male

**AGE**

10 Years

**WEIGHT**

29 Pounds

**INTERPRETED BY**

Kathleen Sennello DVM,  
MS, Diplomate ACVIM  
(Small Animal Internal  
Medicine)

**IMAGING  
PERFORMED BY**

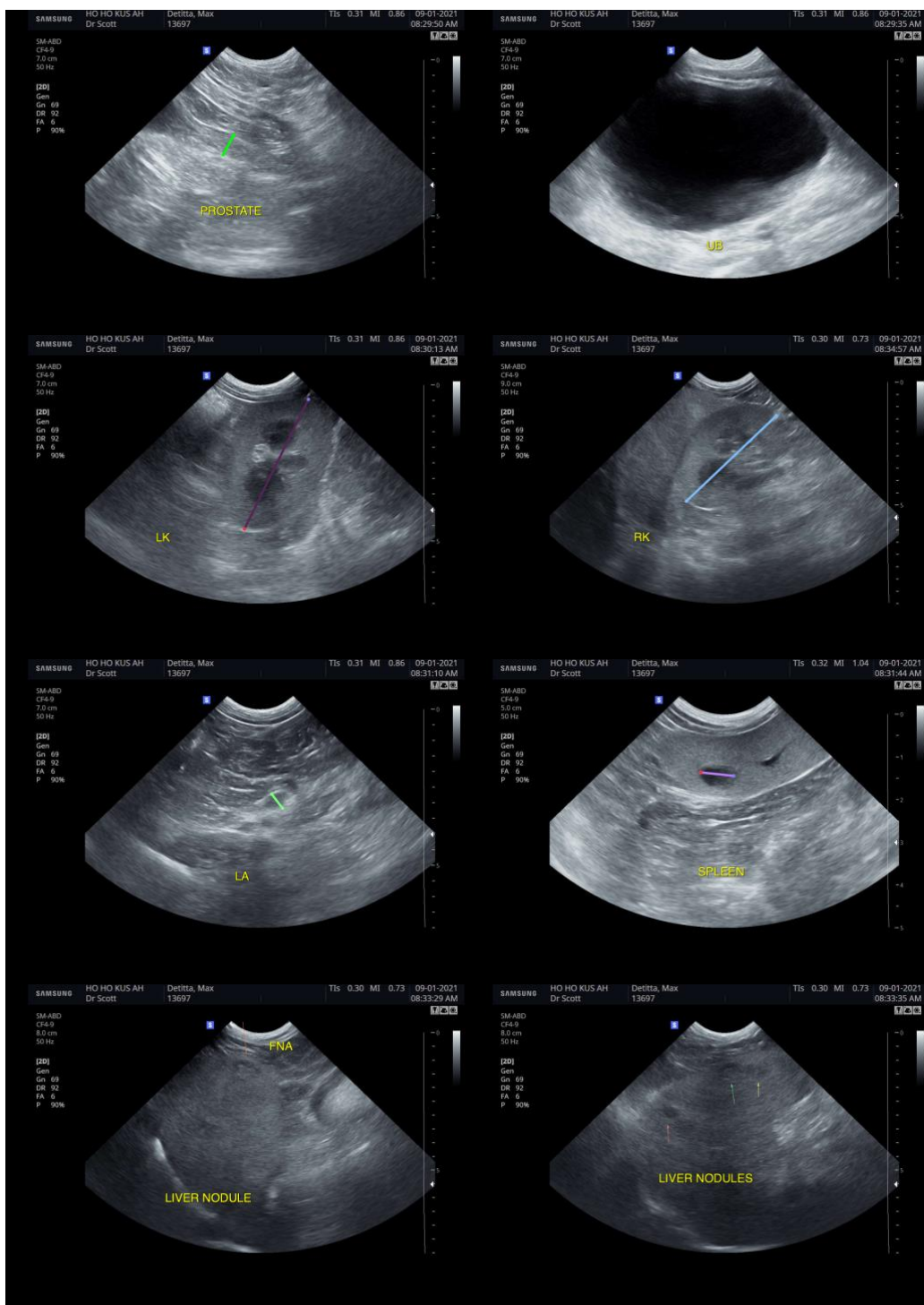
Dr. Scott

**HOSPITAL NAME**

Ho Ho Kus VH

**REFERRING VET**

Dr. Eisenberg



**INVOICE**

12896

**DATE**

9/1/21

The information and recommendations provided are based on the images presented by the referring veterinarian. No evaluation can be communicated regarding pathology that was not visible in the image/video clips provided.

Thank you for this referral. If the clinical or image interpretation does not parallel your findings or if I can be of any further assistance please contact me.



**PATIENT**

Max Detitta

Kathleen Sennello DVM,MS, Diplomate ACVIM (Small animal Internal Medicine)  
kathleen.sennello@sonopath.com

**SPECIES**

Canine

**BREED**

Welsh Terrier

**SEX**

Neutered Male

**AGE**

10 Years

**WEIGHT**

29 Pounds

**INTERPRETED BY**

Kathleen Sennello DVM,  
MS, Diplomate ACVIM  
(Small Animal Internal  
Medicine)

**IMAGING  
PERFORMED BY**

Dr. Scott

**HOSPITAL NAME**

Ho Ho Kus VH

**REFERRING VET**

Dr. Eisenberg

**INVOICE**

12896

**DATE**

9/1/21