



PATIENT PRESENTING CLINICAL SIGNS

Cole Miller
During wellness exam on 6/7/23 after sending out bloodwork, discovered abnormal BUN and ALP levels. Patient has been getting routine bloodwork done since he was a year old. - Patient is having no clinical signs - On and off diarrhea with blood since Summer of 2022, p is on Hills Science diet Z/D, diarrhea happens when he steals housemates food or eats things he shouldn't like a leaf outside - Patient is on RX Clay

SPECIES

Canine

BREED

Scottish Terrier

Abnormal PE/Chem/CBC/UA Results: 6/7/23 - Abnormal BUN and ALP on routine bloodwork with it previously being normal 8/2/23 - rechecked Idexx Chem25 with SDMA and IDEXX T4 with a urinalysis, ALP remained elevated, BUN was up one point and urinalysis was boring.

SEX

Neutered Male

ULTRASONOGRAPHIC EXAMINATION OF THE ABDOMEN

Urinary System

AGE

2 Years

The urinary bladder is minimally distended with anechoic urine. The Bladder wall, trigone, ureteral papillae and visible urethra (to a depth of 2cm) appear normal with no evidence of wall thickening, mucosal irregularities, masses or cystic calculi. Lack of urine distention impairs full evaluation of the urinary bladder.

WEIGHT

35.4 Pounds

The prostate is normal in size (0.83 cm) and shape for this neutered male dog. The parenchyma is homogenous and the external margins are smooth. The prostatic urethra appears normal with no evidence of irregularity, invasion, mass effect or calculi.

INTERPRETED BY

Kathleen Sennello DVM,
MS, Diplomate ACVIM
(Small Animal Internal
Medicine)

The left kidney has a normal shape and size (4.65 cm). Overall echogenicity is normal with adequate corticomedullary distinction and a typical 1:3 cortex:medulla ratio. There is no evidence of focal perinephric inflammation or effusion. There is no evidence of pyelectasia, nephroliths, infarcts or hydroureter. Renal vasculature is normal.

IMAGING PERFORMED BY

Dr. Jo Goodman

The right kidney has a normal shape and size (4.87 cm). Overall echogenicity is normal with adequate corticomedullary distinction and a typical 1:3 cortex:medulla ratio. There is no evidence of focal perinephric inflammation or effusion. There is no evidence of pyelectasia, nephroliths, infarcts or hydroureter. Renal vasculature is normal.

HOSPITAL NAME

Evandale-Blue Ash Pet
Hospital

Adrenal Glands

The left adrenal gland is normal in size measuring 0.50 cm at the caudal pole. It is observed in its normal position cranial to the left renal artery. It is normal in appearance (uniformly hypoechoic) and shape with no evidence of a mass effect.

REFERRING VET

Dr. Jo Goodman

The right adrenal gland is normal in size measuring 0.70 cm at the caudal pole. It is observed in its normal position between the cranial aspect of the right kidney and the caudal vena cava. It is normal in appearance (uniformly hypoechoic) and shape with no evidence of a mass effect.

INVOICE

44537

Spleen

DATE

8/9/23

The spleen is subjectively normal in size, echotexture is homogenous, and the splenic capsule is smooth with no irregularities. The blood flow through the hilus and splenic parenchyma appears normal. No focal parenchymal abnormalities are visualized.



PATIENT *Liver*

Cole Miller The liver is subjectively normal in size, and echogenicity with smooth peripheral margins. The parenchyma is homogenous echotexture. The visible portions of the vasculature and biliary tract appear normal. No focal nodules or cystic lesions are observed.

SPECIES

Canine

The gall bladder lumen is moderately distended. The wall of the gall bladder is not thickened and has a smooth mucosal surface. There is a moderate amount of non-organized echogenic debris. The cystic and common bile ducts are normal/not visible.

BREED

Scottish Terrier

Gastrointestinal

SEX

Neutered Male

The stomach contains minimal luminal contents. It measures at a normal thickness of <0.7cm with some variability due to the presence of rugal folds. The distinction of the gastric wall layers is adequate and there is no impression of reduced peristaltic activity. No masses or focal lesions were observed.

AGE

2 Years

The visualized areas of duodenum, jejunum and ileum have a relatively uniform diameter with minimal fluid distension. Wall thickness is normal. Bowel loops follow a curvilinear path with distinct wall layering maintaining the typical 1:3 muscularis:mucosa layer ratio. Duodenum wall measures 0.36 cm. Jejunum wall measures 0.27 cm. Visualized peristalsis appears appropriate. There were no focal lesions consistent with obstruction or a mass effect observed.

WEIGHT

35.4 Pounds

The ileocecal junction was visualized and exhibited normal intact wall layering and is subjectively of normal thickness. Sections of colon are visualized with formed fecal material and gas shadowing distally. There is no observed focal or generalized colon wall thickening or loss of layering.

INTERPRETED BY

Kathleen Sennello DVM,
MS, Diplomate ACVIM
(Small Animal Internal
Medicine)

Pancreas

The area of the pancreas is normal and isoechoic to surrounding mesentery. There is no evidence of nodules or cystic lesions. There is no evidence of regional mesenteric inflammation or fluid.

Free Abdomen

Evaluation of the peritoneal cavity did not reveal any evidence of effusion, or subjective lymphadenomegaly. The Medial iliac nodes appear normal and there was no evidence of a caudal aortic thrombus at the bifurcation. The omentum is of normal uniform echogenicity.

IMAGING PERFORMED BY

Dr. Jo Goodman

ULTRASONOGRAPHIC FINDINGS

HOSPITAL NAME

Evandale-Blue Ash Pet
Hospital

- Moderate debris in the gallbladder – The significance of the aggregated gallbladder debris is unclear. This could represent an early mucocele, cholestasis, or may be secondary to fasting but seems unlikely to be causing a current issue. Recommend continued monitoring.

REFERRING VET

Dr. Jo Goodman

INTERPRETATION OF THE FINDINGS & FURTHER RECOMMENDATIONS

INVOICE

44537

Today's scan appears relatively normal. Subjectively, there is a moderate amount of debris in the gallbladder, which may be excessive for a younger dog, but this is unlikely causing clinical disease. If desired, chronic Ursodiol therapy could be instituted and continued monitoring of the gallbladder. These are my general recommendations for a primary elevation in ALP:

DATE

8/9/23

- Consider close evaluation of history for possible toxic changes examine medications, diet, dietary indiscretion etc...



PATIENT

Cole Miller

SPECIES

Canine

BREED

Scottish Terrier

SEX

Neutered Male

AGE

2 Years

WEIGHT

35.4 Pounds

INTERPRETED BY

Kathleen Sennello DVM,
MS, Diplomate ACVIM
(Small Animal Internal
Medicine)

IMAGING PERFORMED BY

Dr. Jo Goodman

HOSPITAL NAME

Evandale-Blue Ash Pet
Hospital

REFERRING VET

Dr. Jo Goodman

INVOICE

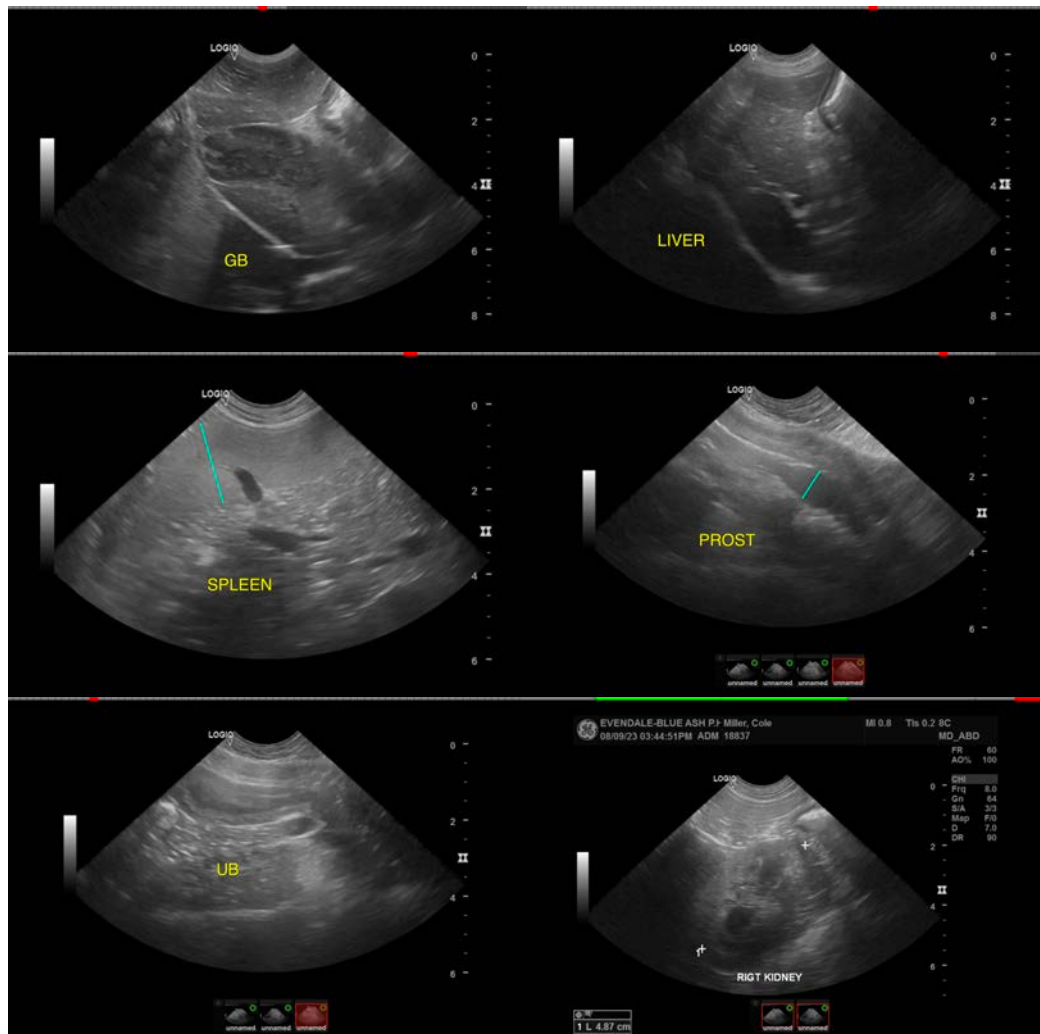
44537

DATE

8/9/23

- Consider PCR on urine/serum for leptospirosis (if not on antibiotics)/serology if recent antibiotic history
- If not already done, consider pre and post prandial bile acids to evaluate liver function
- If the ALP is significantly elevated relative to the ALT and symptoms consistent with Cushing's are present, consider adrenal function testing (ACTH stim)
- Consider Fine needle aspirate if round cell neoplasia is on your differentia list (25 g needle, normal coags)
- If no response to supportive care (Denamarin, fluids, antibiotics, +/- ursodiol etc.) Consider liver biopsy with samples obtained for histopathology, culture, and copper levels.

This is most likely consistent with a breed associated hepatopathy (Scotty hepatopathy), although very early Cushing's or gallbladder disease is possible.





PATIENT

Cole Miller

SPECIES

Canine

BREED

Scottish Terrier

SEX

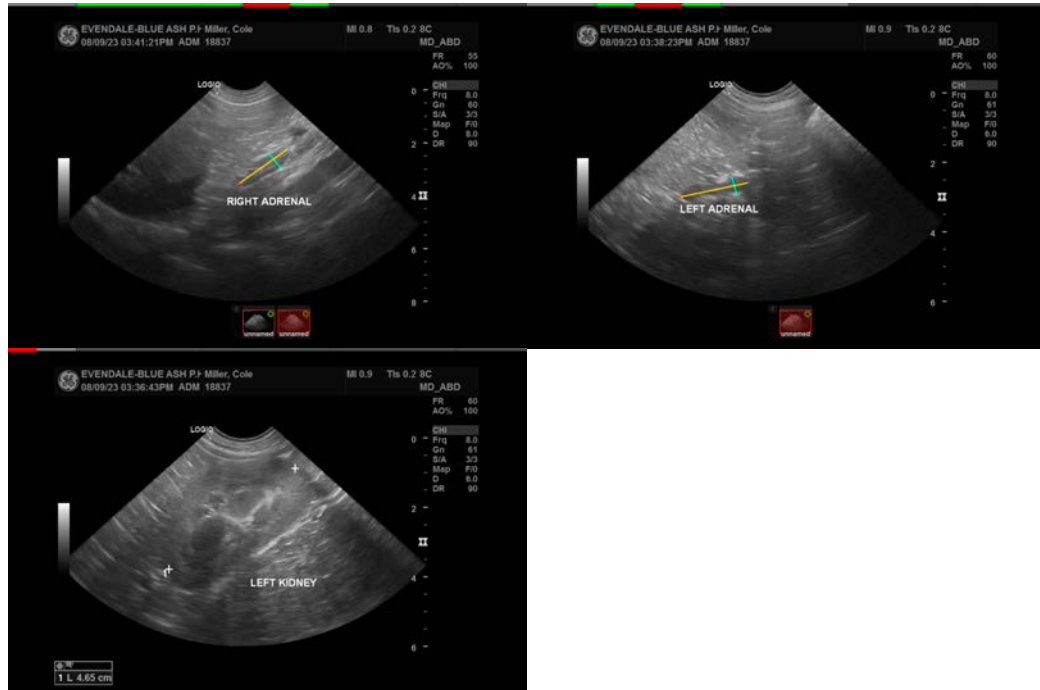
Neutered Male

AGE

2 Years

WEIGHT

35.4 Pounds



INTERPRETED BY

Kathleen Sennello DVM,
MS, Diplomate ACVIM
(Small Animal Internal
Medicine)

**IMAGING
PERFORMED BY**

Dr. Jo Goodman

HOSPITAL NAME

Evandale-Blue Ash Pet
Hospital

REFERRING VET

Dr. Jo Goodman

INVOICE

44537

DATE

8/9/23

The information and recommendations provided are based on the images presented by the referring veterinarian/sonographer. No evaluation can be communicated regarding pathology that was not visible in the image/video clips provided.

Thank you for this referral. If the clinical or image interpretation does not parallel your findings or if I can be of any further assistance please contact me.

Kathleen Sennello DVM,MS, Diplomate ACVIM (Small animal Internal Medicine)

info@sonopath.com