



PATIENT

Little Girl Kurtz

SPECIES

Feline

BREED

DSH

SEX

Spayed Female

AGE

11 Years

WEIGHT

6.62 Pounds

INTERPRETED BY

Kathleen Sennello DVM,
MS, Diplomate ACVIM
(Small Animal Internal
Medicine)

**IMAGING
PERFORMED BY**

Dr. Sheldon

HOSPITAL NAME

Advanced PetCare
of Oakland

REFERRING VET

Dr. Sheldon

INVOICE

40273

DATE

8/9/22

PRESENTING CLINICAL SIGNS

History of vomiting, decreased appetite for 2-3 months. Past couple of days has been urinating and defecating in the closet. She is hiding more, no more accidents as of today. Eating more on cerenia but still not alot. No longer vomiting other than hair once since starting cerenia. No diarrhea. Recommend screening rads-declined.

Abnormal PE/Chem/CBC/UA Results: Bloodwork: slightly high eosinophil count, urinalysis no significant findings. Fecal negative. BCS 4/10.

ULTRASONOGRAPHIC EXAMINATION OF THE ABDOMEN

Urinary System

The urinary bladder is moderately distended with mild primarily suspended echogenic debris present. The Bladder wall, trigone, ureteral papillae and visible urethra (to a depth of 2cm) appear normal with no evidence of wall thickening, mucosal irregularities, masses or calculi. Echogenic debris of this type can be associated with small crystals, cellular debris and proteinaceous debris.

The left kidney has a normal shape and size (2.93 cm). Overall echogenicity is slightly hyperechoic with poor corticomedullary distinction and a typical 1:3 cortex:medulla ratio. There is no evidence of perinephric inflammation or effusion. There is no evidence of pyelectasia, nephroliths, infarcts or hydroureter. Renal vasculature is normal.

The right kidney is borderline small (2.6 cm) and irregular in shape, likely due to previous infarct. There is a 0.84 cm non-obstructive nephrolith visualized. Overall echogenicity is slightly hyperechoic with poor corticomedullary distinction and a typical 1:3 cortex:medulla ratio. There is no evidence of perinephric inflammation or effusion. There is no evidence of pyelectasia or hydroureter. Renal vasculature is normal.

Adrenal Glands

The region of left adrenal (Cranial to left renal artery) is unremarkable but the adrenal is not distinctly visualized. No evidence of a mass effect.

The region of the right adrenal (between right cranial kidney and vena cava) is unremarkable, but the adrenal is not distinctly visualized. No evidence of a mass effect.

Spleen

The spleen is subjectively normal in size (0.86 cm in width at the level of the hilus), echotexture is homogenous, and the splenic capsule is smooth with no irregularities. The blood flow through the hilus and splenic parenchyma appears normal. No focal parenchymal abnormalities are visualized.

Liver

The liver is subjectively normal in size, and echogenicity with smooth peripheral margins. The parenchyma is homogenous echotexture. The visible portions of the vasculature and biliary tract appear normal. No focal nodules or cystic lesions are observed.

The gallbladder lumen is moderately distended. The wall of the gall bladder is not thickened and has a smooth mucosal surface. Luminal contents are primarily anechoic. The cystic and common bile ducts are normal/not visible.



PATIENT

Gastrointestinal

Little Girl Kurtz

The stomach is mildly to moderately dilated with fluid and irregular shadowing material most consistent with normal ingesta and gas. It measures at a normal thickness of <0.36cm with some variability due to the presence of rugal folds. The distinction of the gastric wall layering is adequate and there is no impression of reduced peristaltic activity. No masses or focal lesions were observed.

SPECIES

Feline

The visualized areas of duodenum, jejunum and ileum have a uniform diameter with minimal fluid distension. Wall thickness is normal to slightly increased. Bowel loops follow a typical curvilinear path with distinct wall layering, but some areas display a prominent muscularis layer which does not display the typical 1:3 muscularis:mucosa layer ratio. Jejunum wall measured 0.29 cm. Visualized peristalsis appears appropriate. There were no focal lesions consistent with obstruction or a mass effect observed.

BREED

DSH

SEX

Spayed Female

The ileocecal junction was visualized and exhibited normal intact wall layering and is subjectively of normal thickness. Sections of colon are visualized with formed fecal material and gas shadowing distally. There is no observed focal or generalized colon wall thickening or loss of layering.

Pancreas

AGE

11 Years

The pancreas is normal and isoechoic to surrounding mesentery. There is no evidence of nodules or cystic lesions. There is no evidence of regional mesenteric inflammation or fluid.

Free Abdomen

WEIGHT

6.62 Pounds

Evaluation of the peritoneal cavity did not reveal any evidence of effusion. There is a significant mesenteric lymphadenopathy present with lymph nodes measuring 0.45, 0.42, and larger lymph node measuring 1.0 cm x 2.65 cm. The omentum is hyperechoic around the enlarged lymph nodes.

PRIMARY FINDINGS

- Echogenic debris in the urinary bladder – The echogenic debris in the bladder lumen could be consistent with cells, crystals, and/or mucus.
- Prominent muscularis layer to the small intestine – The small intestinal wall changes are most consistent with an inflammatory process (i.e., inflammatory bowel disease) with a low possibility of emerging lymphoma.
- Moderate mesenteric lymphadenopathy – The prominent abdominal lymph nodes are most consistent with reactive lymphadenitis or lymphoid hyperplasia. Neoplastic infiltration is considered less likely.

INTERPRETED BY

Kathleen Sennello DVM,
MS, Diplomate ACVIM
(Small Animal Internal
Medicine)

IMAGING PERFORMED BY

Dr. Sheldon

HOSPITAL NAME

Advanced PetCare
of Oakland

REFERRING VET

Dr. Sheldon

SECONDARY FINDINGS

- Decreased corticomedullary distinction in both kidneys with a right-sided non-obstructive nephrolith and likely previous infarct – The bilateral renal findings are consistent with age-related change. The solitary renal lesion identified is ill defined and hyperechoic, this could be consistent with a previous renal infarct and can be an indicator of current or previous renal disease.
- Mild/moderate ingesta within the gastric lumen – Correlate with feeding history. If the patient was adequately fasted, consider delayed gastric emptying or a partial outflow tract obstruction (none observed).

INVOICE

40273

DATE

8/9/22



PATIENT

Little Girl Kurtz

SPECIES

Feline

BREED

DSH

SEX

Spayed Female

AGE

11 Years

WEIGHT

6.62 Pounds

INTERPRETATION OF THE FINDINGS & FURTHER RECOMMENDATIONS

The small bowel overall appears somewhat “ropey” with a prominent muscularis layer. Additionally, there are some enlarged, irregular mesenteric lymph nodes visualized. These findings are suggestive of primary gastrointestinal disease.

- Consider a novel protein/hydrolyzed protein prescription diet.
- Consider a GI panel to Texas A&M for a qualitative fPLI, TLI, cobalamin and folate.
- Consider three view thoracic radiographs to rule out concurrent thoracic disease/involvement.
- Consider a fine needle aspirate of a mesenteric lymph node.
- If cytology of a lymph node is not helpful, and there is no response to dietary therapy, consider obtaining GI biopsies.

Both kidneys appear somewhat small and irregular. Additionally, there is some echogenic debris in the urinary bladder. Consider urinalysis, culture and blood pressure evaluation.

INTERPRETED BY

Kathleen Sennello DVM, MS, Diplomate ACVIM (Small Animal Internal Medicine)

IMAGING PERFORMED BY

Dr. Sheldon

HOSPITAL NAME

Advanced PetCare of Oakland

REFERRING VET

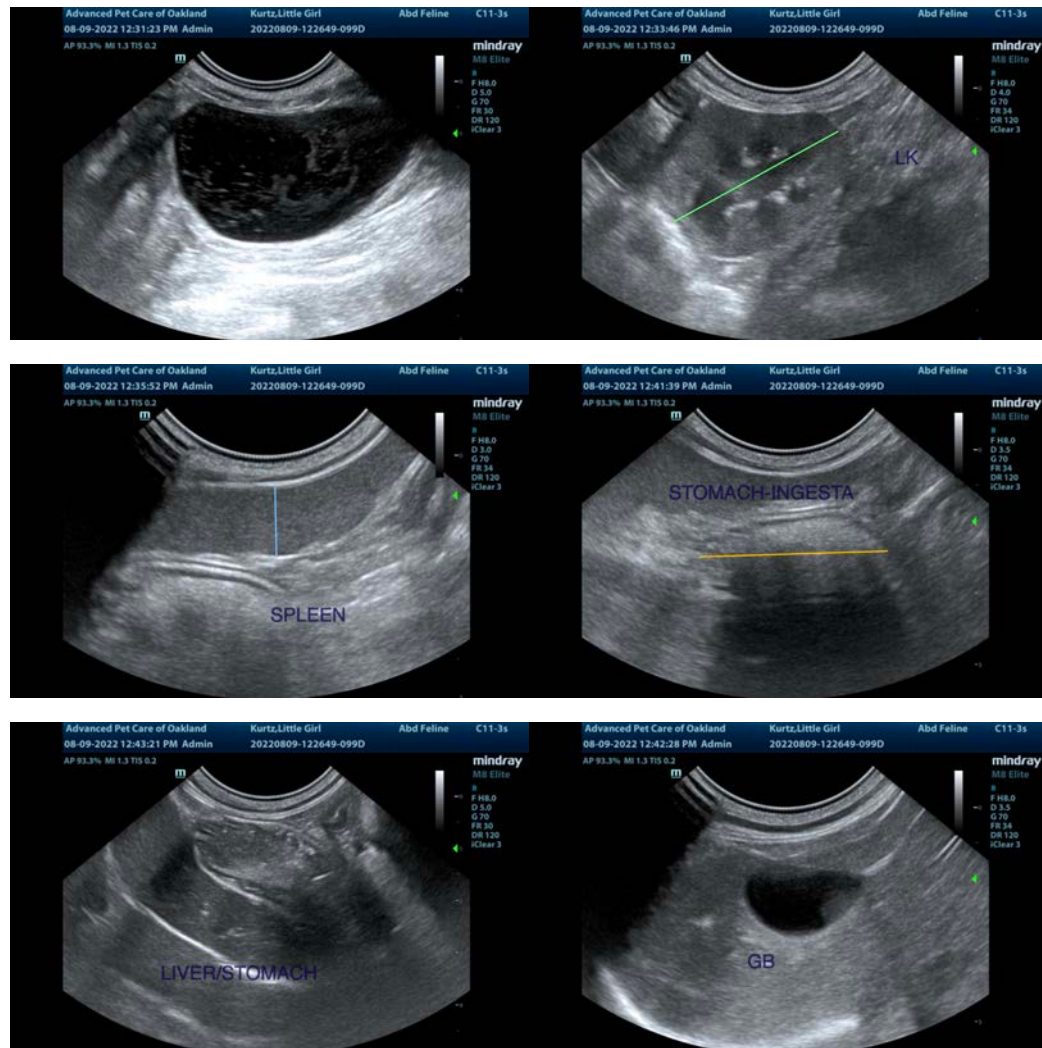
Dr. Sheldon

INVOICE

40273

DATE

8/9/22





PATIENT

Little Girl Kurtz

SPECIES

Feline

BREED

DSH

SEX

Spayed Female

AGE

11 Years

WEIGHT

6.62 Pounds

INTERPRETED BY

Kathleen Sennello DVM,
MS, Diplomate ACVIM
(Small Animal Internal
Medicine)

**IMAGING
PERFORMED BY**

Dr. Sheldon

HOSPITAL NAME

Advanced PetCare
of Oakland

REFERRING VET

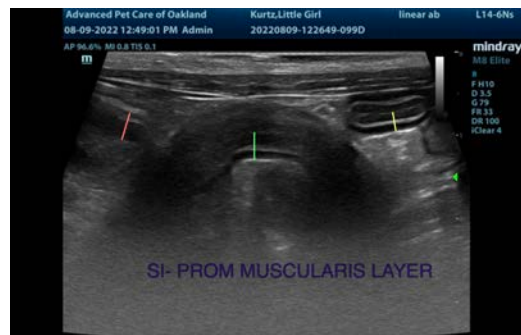
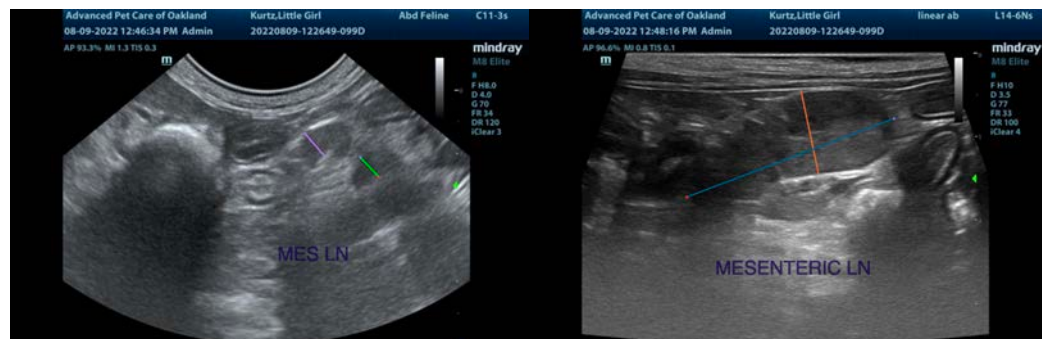
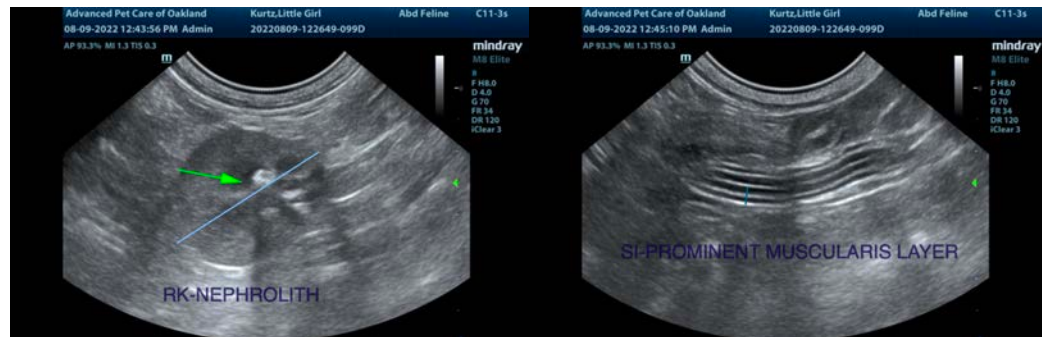
Dr. Sheldon

INVOICE

40273

DATE

8/9/22



The information and recommendations provided are based on the images presented by the referring veterinarian/sonographer. No evaluation can be communicated regarding pathology that was not visible in the image/video clips provided.

Thank you for this referral. If the clinical or image interpretation does not parallel your findings or if I can be of any further assistance please contact me.

Kathleen Sennello DVM,MS, Diplomate ACVIM (Small animal Internal Medicine)

kathleen.sennello@sonopath.com